

Immediate Implant Placement After Extraction of Mandibular molars : Report of 3 cases

Dr Vrinda Kolte

Abstract: Immediate dental implant placement has been an acceptable procedure for at least the past two decades. Commonly, immediate implants have been reserved for the single rooted anterior tooth and single or bi-rooted premolar tooth. Perhaps the most important aspect of any implant surgery in accordance with the successful procedure is implant stability and bone to implant contact (BIC). Removal of molar teeth provides a challenging and intriguing dilemma due to multiple root morphology. In the case of extraction and immediate placement of dental implants preserving alveolar bone proper, particularly that of the labial and lingual plates of bone is essential in providing the optimal environment for maximizing BIC and implant stability. Also, the position of the final restoration must be considered, in relation to intra and inter arch position, occlusion, function and esthetics. Thus, minimal alveolar bone removal should be considered and attained to aid in the above factors in order to provide an acceptable surgical site for successful placement of the dental implant. Finally, and perhaps most importantly when considering immediate molar implant placement, removal of the intra-alveolar septum should be avoided to aid in increasing BIC and allowing the attainment of initial implant stability at the time of placement.

I. Introduction

Immediate implant placement following tooth extraction in appropriately selected cases has been considered the optimal procedure for the following reasons: the natural healing process are mobilized to the maximum, no bone resorption has taken place yet, drilling is reduced, a number of surgical stages are eliminated, design and construction of prosthesis is simplified, and positive psychological effect on the patient.^{1,2}

The posterior mandible is a common site for the consideration of implant placement because of the premature loss of molars and it is always a challenging task to place implant in multirouted teeth as there is discrepancy between size of implant and socket. However, their use is complicated by the anatomic obstacles of the inferior alveolar nerve, a variety of malformations of the ridges, the presence of softer bone, and little or no possibility of reinforcement via bicortical stabilization.^{3,4}

The implant diameter is often smaller than the diameter of the root of the extracted tooth, which may lead to a gap between the implant and the extraction socket wall. In cases where the distance between the implant and the extraction socket is less than 2mm, spontaneous bone healing can be expected without the necessity for additional grafting procedures.^{5,6,7}

Barrier membranes have been developed to allow guided tissue regeneration by the principle of osteopromotion. The material is chemically and biologically inert. However, non resorbable and resorbable membranes are available in the market, the non resorbable e-PTFE (Expanded Poly Tetra Floro Ethylene) (Gore-Tex,) remains the most widely used membrane.^{8,9,10}

CASE REPORT 1

A 30 year old, non smoker visited the opd. Tooth #30 was vertically fractured (**Fig.1a**) and therefore scheduled for extraction. No pain or fistula formation was noted.

All the available treatment options were discussed with the patient which involves the hemisection of lower right 1st molar with extraction of the distal root and tooth segment, with metal ceramic bridge would be fabricated; extraction of lower right 1st molar, followed by a delayed implant placement; extraction of lower right 1st molar and fabrication of a metal ceramic bridge and an immediate implant placement. The patient opted for immediate implant placement and was informed about the treatment procedure.

The patient was then investigated to fulfill the following required criteria before undergoing treatment : 1) No systemic diseases (eg, diabetes), not consuming any prescribed medications or recreational drugs; 2) the buccal and lingual plate of extraction socket was present; 3) the teeth adjacent to the extraction socket were free of overhanging or insufficient restoration margins; 4) the patient did not use nicotine; and 5) the interradicular bone was wide and intact following the tooth extraction.

An intrasulcular incision extending to the adjacent teeth was made and a full thickness flap was reflected. No vertical releasing incision was made. Lower right 1st molar was hemisected and the roots were removed separately. The socket was curetted carefully and irrigated with sterile saline solution (**Fig.1b**). The dimension of the socket was measured with a periodontal probe (UNC 15, Hu Friedy, Germany) during surgery after tooth extraction. The mesiodistal distance was 9 mm, buccolingual distance was 8 mm and the depth in the mesial side was 8 mm. A dental implant 4.2 mm wide, length 11.5 (ADIN, Israel) was placed into the interradicular bone. Pilot drill (2mm) was used for initial preparation. This was followed by sequential drilling along the implant axial line to allow the implant to have adequate bone contact till 3.75 mm drill in diameter.

While drilling along the depth, just after 1mm of drilling, patient was in deep pain. Implant is placed in the proposed site but we could not achieve initial stability. But still after patient's consent, we left that implant in place, with synthetic bone graft (Hydroxyapatite, SYBOGRAFT) covering the implant in the whole socket. A ePTFE non resorbable membrane was then secured over the socket and the graft (**Fig 1c**). The membrane was left in place for 4 weeks. The flap was repositioned and was sutured into place with interrupted sutures and the membrane was left partially exposed.

The patient was administered an analgesic twice a day daily for 7 days and a systemic antibiotic twice a day for 7 days. Furthermore, he was advised to rinse with a 0.1% chlorhexidine digluconate solution four times a day for 5 weeks.

The membrane was removed 4 weeks after surgery. Healing cap was placed 6 months after surgery. After 2 weeks healing cap was removed and implant was loaded with a single, ceramic crown. (**Fig. 1 d,e,f**)

CASE REPORT 2

Another patient, 17 year old female, reported in the OPD. This patient came with the complaint of overretained lower right deciduous (**Fig.2a,b**) molar with congenitally missing second premolar and wanted to replace it. All the treatment options were given and patient opted for immediate implant placement. All the pre operative investigations were within normal limits. The same procedure was carried out as in the previous case to place an implant in the interradicular bone (**Fig.2c,d**). In this case, no bone graft was required as the gap between implant and the socket wall was less than 2mm and the primary stability immediately after implant placement was good. Prosthesis for this patient was given after 3 months. (**Fig. 2 e,f,g**)

CASE REPORT 3 (Fig.3 a,b)

A 23 year old male patient reported in our OPD for extraction of his decayed teeth. After evaluating his dentition, we gave this patient all the treatment options and he also opted for immediate implant placement for his first molar. The same procedure was carried out as previous and implant placement was done in the interradicular bone.

Clinical evaluation was done at one, two and four months preloading, then at one, three and six months after loading including: Probing depth, bleeding index and gingival index. Radiographic evaluation was done for all cases at same follow up post loading periods using periapical and panoramic radiographs to assess marginal bone height and bone density mesial and distal to implant fixture.

Postoperative follow up visits for all three patients were made every week during the first 4 weeks and then followed by a maintenance program consisting of semi-annual follow up appointments for 2 years.

II. Results – (Table 1)

PRE-LOADING CLINICAL EVALUATION

All three patients were followed up at one, two and four months post operatively. At the first week postoperative, some discomfort was reported without any complaint of severe pain or edema. All wounds healed properly during follow up period.

POST –LOADING EVALUATION

This was done one, three and six months post loading as implant mobility was tested using the Miller Mobility Index (MI) scores.¹¹

Two out of three cases showed no mobility during the follow up period. The remaining one case showed decline in mobility index scores through the follow up period.

The percussion was done to assess osseointegration, indicating ankylosed implant in cases with no mobility. While, less metallic sound was observed in the remaining one case.

Probing depth¹² was measured for each implant for the four surfaces collectively (buccal , lingual , mesial and distal). There was gradual decrease in probing depth measurement during the study period.

Bleeding index¹² was measured from the four surfaces collectively around all implant abutments. Bleeding index showed gradual decline over 6 weeks follow up.

Gingival index¹² scores were measured of the four surfaces collectively for all implant abutments. At six months follow up period, decline in gingival index score was shown.

RADIOGRAPHIC EVALUATION

Both marginal bone height and bone density were evaluated for all cases throughout the post-loading follow up period. For the marginal bone height measurements, there was decrease in the marginal heights around all implants at the three months post-loading period and then increase in the six months post-loading period. No major complications were encountered in all the cases.

III. Discussion

All the 3 extraction sockets had intact socket walls after extraction. Following placement of the implants, primary stability of all cases were good except in the first case where primary stability was not achieved.

All the cases had good soft tissue architecture preservation at one week post surgery with minimal edema and there were no complaints of pain nor discomfort during early post operative healing period.

All the implants achieved successful osseointegration after a healing period of between 3 and 6 months. The residual peri implant socket spaces were found to be well healed exhibiting no implant thread exposure at the end of healing process.

The soft tissue architecture remained stable with preservation of adequate attached gingiva throughout the healing period of the implants as well as after final prosthesis delivery , contributing to aesthetically pleasing and biologically sound results.

All the 3 patients were very pleased with the functional outcomes of their treatment.

Implant placements in fresh extraction sockets with or without the use of covering membrane or graft materials have been reported in a several recent publications. It has been suggested that the implant should be placed into a minimum of 3 mm of solid bone apical to the extraction site.^{13,14,15,16}

A main factor determining the success of immediate placement is the initial stability of the implant. The extraction site must be evaluated to see whether it is suitable for immediate implant placement. Micromovements between implant and surrounding bone should be avoided to allow successful healing to occur. In our cases , the interradicular septum of extraction socket and part of mesial socket were used to anchor the implant. The implant was inserted 3mm apical to the socket. Therefore, sufficient height and width of the interradicular septum should be considered serious selection criteria for this treatment modality. Further selection criteria include the following : (1) absence of clinical signs of acute periodontal or endodontic abscess formation ² (2) establishment of healthy periodontal conditions before surgery and instructing the patient in oral hygiene, (3) management of postoperative maintenance, and (4) patient compliance.

The long term stability of immediate implant placement in the molar region has been demonstrated previously. These findings suggest that in cases of immediate implant placement in molar region, a sufficient interradicular bone width should be present.

In the present study, two cases showed no mobility through-out the post-loading follow-up period and one case showed gradual decline in the Mobility Index scores. This is in agreement with Linkow et al, ¹⁸ who stated that periodontal indices were not directly related to the success or failure of osseointegration of implants. They are used for monitoring peri-implant soft tissue.

The surgical protocol was standardised for all cases. All three teeth were extracted with minimal trauma. This was a useful technique, resulting in preservation of intact labial walls of all the three sockets, which is required for soft tissue framing.

This was the most challenging phase of the surgery as the relatively large discrepancy between the dimensions of the molar sockets and the diameters of the drill present a unique challenge of creating a congruent osteotomy. Furthermore, encroachment of the inferior alveolar canal must also be avoided.

There was a slight increase of bone density for all implants through follow-up period in the present study

To be successful, implant placement should only be attempted if there is complete resolution of local infection, and if there is enough bone for placement of an appropriately sized implant, in the ideal restorative position, and with primary implant stability. Implant placement can be adversely affected by infection in the implantation site, lack of soft-tissue closure, flap dehiscence, thin tissue types, and incongruity between the implant shape and the socket.

References

- [1]. Zahnmed SM: Prevention of alveolar ridge resorption after teeth extraction. Int J Oral Maxillofac Surg. 114: 328, 2004.
- [2]. Esposito M, Grusovin MG, Kwan S, Worthington H V, Coulthard P: Intervention for replacing missing teeth: bone augmentation techniques for dental implant treatment. Aust Dent J. 70: 54, 2009.
- [3]. Abubaker O, Benson K: Oral and Maxillofacial secrets, Hanley ,Beflus inc ; Philadelphia. PP 309, 2000.
- [4]. Coatoam G, Mariotti A: Immediate placement of anatomically shaped dental Implants. J Oral Implantol. 26:170, 2000.
- [5]. Chen ST, Darby IB, Reynolds EC, Clement JG. Immediate implant placement postextraction without flap elevation. J Periodontol. 80 : 163-172, 2009
- [6]. McAllister BS, Haghghat K. Bone augmentation techniques. J Periosdntol. 78 : 377-396, 2007.
- [7]. Fugazzotto PA. Report of 302 consecutive ridge augmentation procedures : technical considerations and clinical results .Int J Oral Maxillofac Implants. 1998 ; 13 : 358-368.
- [8]. Simon M, Trisi P, Piattelli A: Vertical ridge augmentation using a membrane technique associated with osseointegrated, implants. Int J Periodont Rest Dent. 14: 497, 1994.
- [9]. Rominge J W,Triplett R G: The use of guided tissue regeneration to improve implant osseointegraion. J Oral Maxillofac Surg. 52:106,1994.
- [10]. Schliephake H, Dard M, Planck H, Hierlemann H, Jakob A.: Guided bone regeneration around endosseious implants using a resorbable membrane VS ePTFE membrane . Clin. Oral Impl .Res:11:230, 2000.
- [11]. Miller SC. Textbook of Periodontia. 3rd Edition, Blankiston Inc. Pub, Philadephia. Pg 215, 1950.
- [12]. Mohamed TN, Younis AES et al. Immediate implants in lower posterior teeth with bone substitute and guided tissue membrane. Cairo Dental Journal. Vol 25 , No 1 ; 2009 : 61-67.
- [13]. Esposito M, Grusovin MG et al. The effectiveness of immediate, early and conventional loading of dental implants : A Cochrane systematic review of randomized controlled clinical trials. Int J Oral Maxillofac Implants. 2007; 22 : 893- 904.
- [14]. Schwartz AD, Chaushu G. The ways and wherefores of immediate placement of implants into fresh extraction sites : A literature review. J Periodontol. 1997 ;68:915-923.
- [15]. Werbit MJ , Goldberg PV. The immediate implant: Bone preservation and bone regeneration. Int J Periodontics Restorative Dent. 1992;12:207-217.
- [16]. Cochran DL, Schenk RK et al. Bone response to unloaded titanium implants with sand blasted ad acid etched surface : A histometric study in the canine mandible. J Biomed Mater Res. 1998;40:1-11.
- [17]. Schulte B, et al. The first 15 years of Tübingen implant and its further development to the Frialite – 2 system. J Dent Implantol. 1999; 15 :75.
- [18]. Anson, D. The changing treatment planning paradigm: Save the Tooth or Place and Implant. 2010. 30:506-5-17.

TABLE 1

Patient No.	AGE / SEX	Extracted tooth and implant replacement site	Reason for extraction	Inter Radicular Bone After Extraction	Labial peri implant socket gap distance	Primary stability	Peri implant socket grafting	Healing period before final prosthesis (in month)
1	32 / Male	Mandibular right first molar	Unrestorable tooth structure secondary to vertical tooth fracture	Intact	> 2mm	Average	Yes	6 months
2	17 / Female	Mandibular overretained primary first molar	To replace the missing tooth	Intact	< 2mm	Good	No	3 months
3	23 / Male	Mandibular right first molar	Unrestorable tooth secondary to caries	Intact	< 2mm	Good	No	3 months

Figures

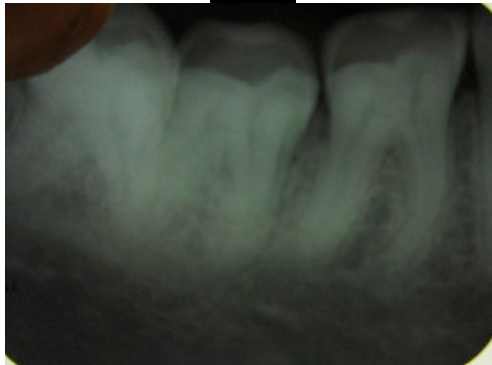

Fig 1 a
Preoperative IOPA

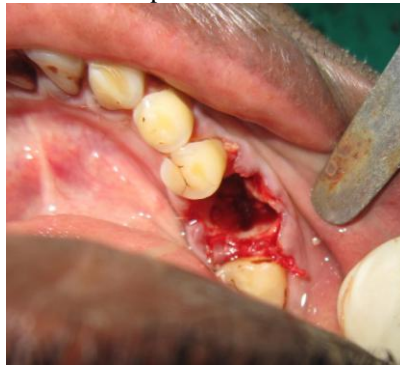

Fig 1 b
Intra operative after atraumatic extraction of mandibular right 1st molar

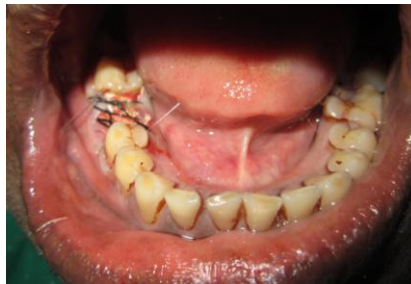

Fig 1 c
Placement of GTR membrane and suturing

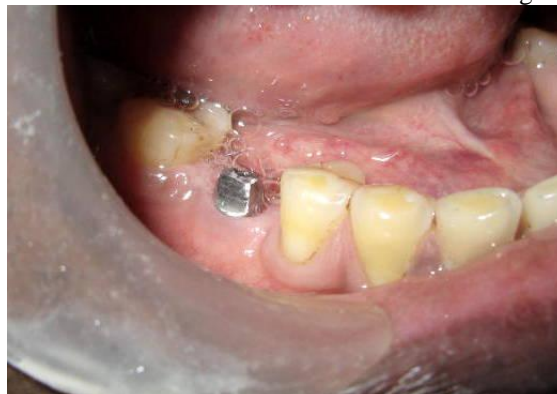

Fig 1 d
Abutment at the time of prosthesis

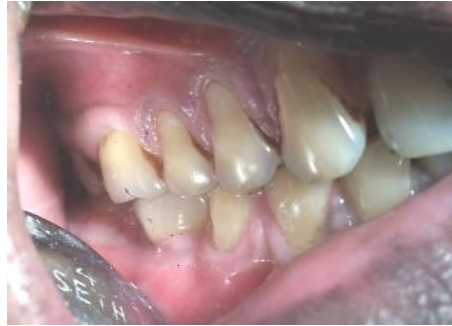

Fig 1 e

Implant supported prosthesis with mandibular right 1st molar

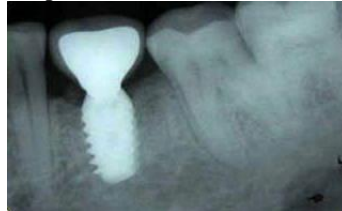

Fig 1 f

IOPA after prosthesis

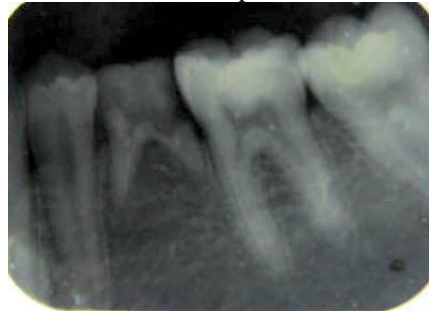

Fig 2 a

Pre operative IOPA showing overretained mandibular right 1st molar

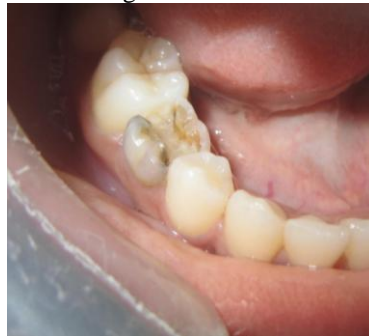

Fig 2 b

Preoperative intra oral view

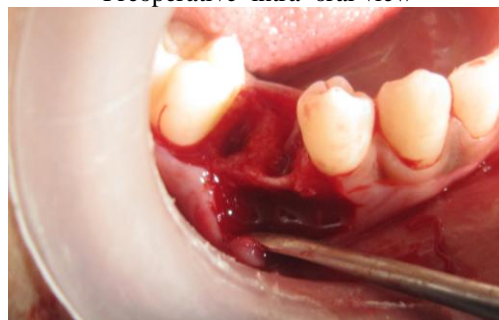


Fig 2 c

Intra operative view showing extracted socket

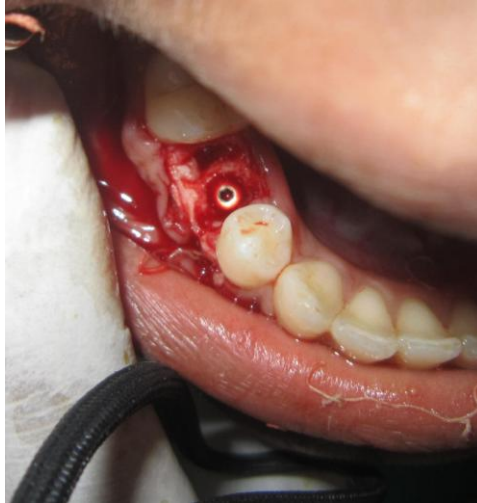

Fig 2d

Intra operative view after implant placement

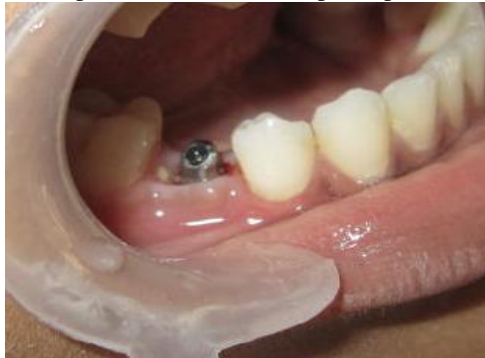

Fig 2 e

At the time of prosthesis

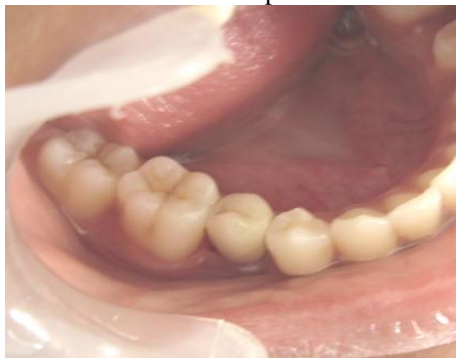

Fig 2 f

After prosthesis

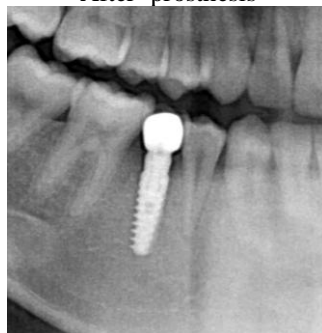

Fig 2 g

OPG after prosthesis

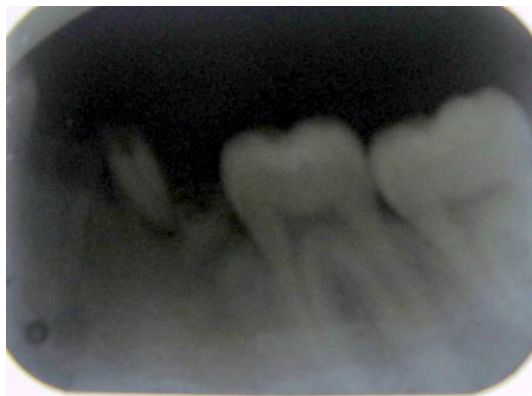

Fig 3 a

Pre operative IOPA showing root pieces with mandibular molar

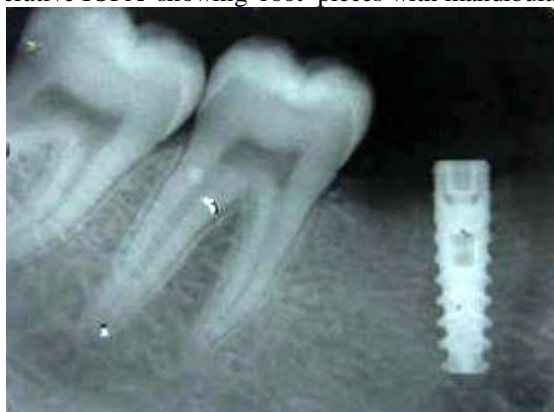

Fig 3 b

IOPA after implant placement