

Valentino's Syndrome Presenting as Acute Appendicitis: A Case Report

Ritu Nehra¹, Sanjeev Agarwal¹, Yogesh Kumar Baberwal¹, Dushyant Kumawat¹, Arjun Chaudhary¹

¹Department of General surgery, Geetanjali medical college and hospital, Geetanjali University, Udaipur, Rajasthan, India

Abstract

Valentino's syndrome is a rare condition in which a perforated gastric or duodenal ulcer presents as right lower quadrant pain, mimicking acute appendicitis. We report a 40-year-old male presenting with 5 days of worsening right iliac fossa pain, fever, and nausea. Laboratory investigations showed markedly elevated inflammatory markers. Initial ultrasonography suggested acute appendicitis with a thickened non-compressible appendix and periappendiceal inflammatory changes. However, contrast-enhanced CT demonstrated a normal appendix with a large retroperitoneal periduodenal fluid collection extending along the right paracolic gutter into the pelvis, associated with thickening and suspected posterior wall defect of the second and third parts of the duodenum, suggestive of a sealed duodenal perforation. Upper gastrointestinal endoscopy revealed erosive esophagitis and gastritis without visible duodenal pathology. The patient was successfully managed conservatively with bowel rest, intravenous antibiotics, fluids, freka's tube insertion and proton-pump inhibitors, with complete symptomatic recovery.

Keywords: Valentino's syndrome, Duodenal perforation, Acute appendicitis mimic, Retroperitoneal perforation, Contrast-enhanced computed tomography

Date of Submission: 06-06-2026

Date of Acceptance: 17-06-2026

I. INTRODUCTION

Right lower quadrant (RLQ) pain is most commonly due to acute appendicitis, but a broad differential must be considered, including gastrointestinal, urinary and gynaecologic causes [1]. Valentino's syndrome refers to a duodenal (or gastric) ulcer perforating into the retroperitoneum, with leaked contents tracking down the right paracolic gutter and causing RLQ pain mimicking appendicitis [2]. Awareness of this syndrome is critical because missed diagnosis can lead to delayed treatment and high morbidity [3]. Modern imaging, especially Computed Tomography (CT), plays a key role in distinguishing these conditions by identifying features such as retroperitoneal air, duodenal wall thickening, and fluid collections [3]. We present a case of suspected Valentino's syndrome in a 40-year-old male with 5-day RLQ pain, highlighting the clinical and imaging findings.

II. Case Report

A 40-year-old man with no significant past medical history presented to the emergency department with 5 days of worsening right lower abdominal pain, associated with fever and nausea. Initial laboratory tests were notable for significant findings, with an ESR of 120 mm/hr, CRP of 151 mg/L, and PCT of 0.28 ng/mL. Kidney markers were elevated (Creatinine 1.60 mg/dL, Urea 69.3 mg/dL, BUN 32.2 mg/dL), and electrolytes showed Sodium at 129 mEq/L. Other findings included Hemoglobin 11.50 g/dL, Albumin 2.88 g/dL, and a Blood Sugar of 153 mg/dL, while liver enzymes (SGOT 22, SGPT 21) remained normal. A bedside abdominal ultrasound described an obese patient with mild hepatomegaly, fatty liver changes, and notable right iliac fossa findings: a non-compressible, thickened appendix (8.5 mm) with surrounding echogenic fat and minimal free fluid. The impression was acute appendicitis.

Given the atypical presentation and to further evaluate, an abdominal CT scan was obtained (Figure 1). CT demonstrated no appendiceal inflammation or collection: the appendix was normal in size with clear lumen. Instead, there was a heterogeneous fluid collection (~380–400 mL) in the periduodenal (retroperitoneal) space, extending along the right paracolic gutter into the pelvis. The second and third parts of the duodenum showed wall thickening, with a suspected small perforation or wall defect in the posterior third portion. No free intraperitoneal air was seen. These findings raised suspicion of a sealed (posterior) duodenal ulcer perforation, i.e. Valentino's syndrome. The liver had a small hemangioma; biliary tract and pancreas were normal.

An upper gastrointestinal endoscopy was performed next (Figure 2). Esophagogastroduodenoscopy (EGD) showed diffuse erosive esophagitis with multiple ulcers in the lower esophagus, and diffuse gastritis in the stomach. The duodenum was inspected up to D3/D4: the mucosa appeared normal, with no visible ulcer or perforation. Biopsies were not reported. Final EGD impression was esophagitis, esophageal ulcers, and gastritis, with no obvious duodenal pathology.

Gastro medicine opinion was taken and Freka's tube insertion was done and feeding started (Figure 3). Following which another CECT was done (Figure 4). With an uncertain diagnosis of duodenal perforation with esophagitis, esophageal ulcers, and diffuse gastritis with perforation in 4th part of duodenum, the patient was managed conservatively: nil per os, IV fluids, broad-spectrum antibiotics, freka's tube insertion and intravenous proton-pump inhibitors (PPI) with Freka's tube insitu. On follow-up, there was gradual clinical improvement: pain and fever resolved and Freka's tube was removed. The patient was discharged after one week on oral antibiotics and high-dose PPI. At follow-up, the patient remained asymptomatic.

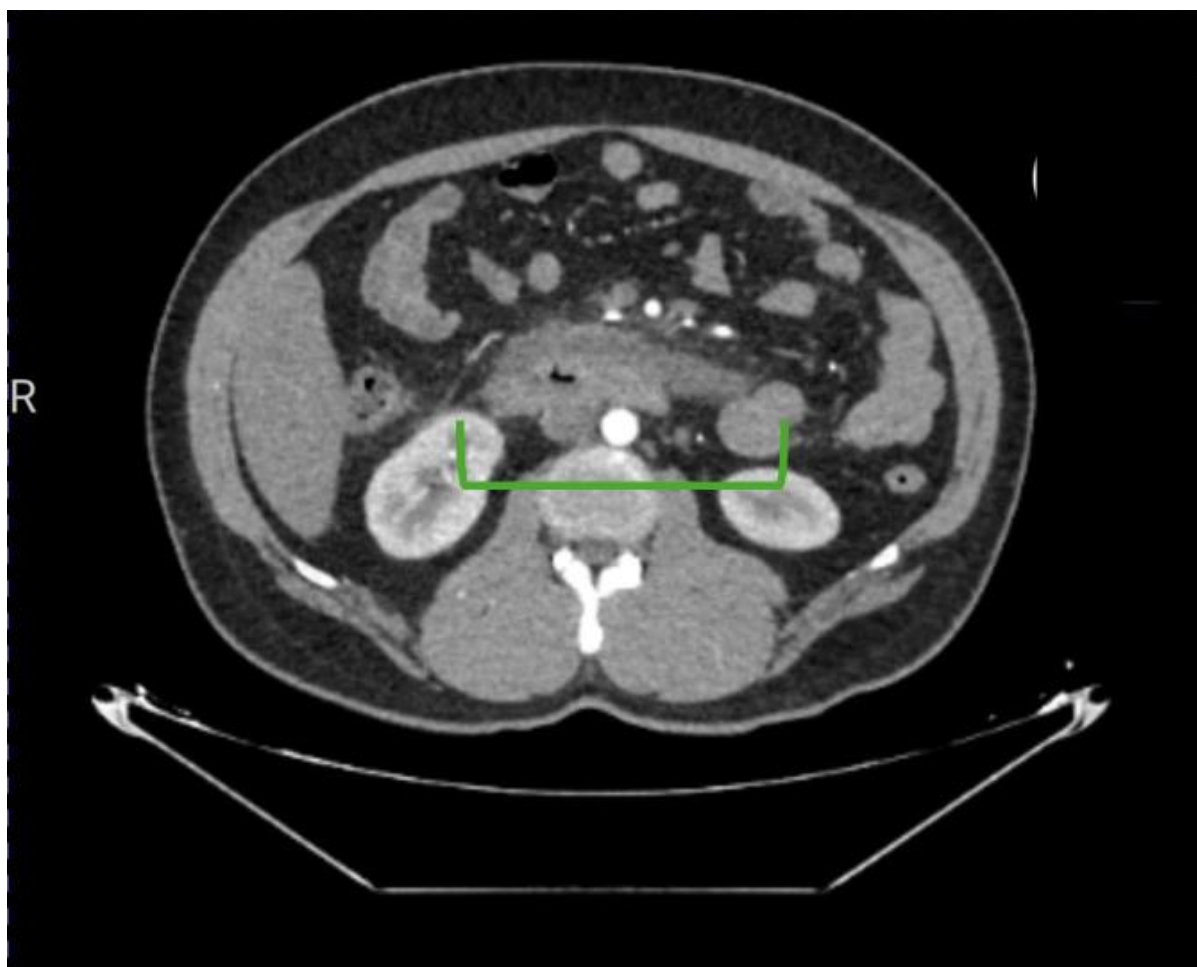


Figure 1: Contrast-enhanced CT abdomen demonstrating a large retroperitoneal periduodenal fluid collection extending along the right paracolic gutter with associated duodenal wall thickening, suggestive of a sealed duodenal perforation.

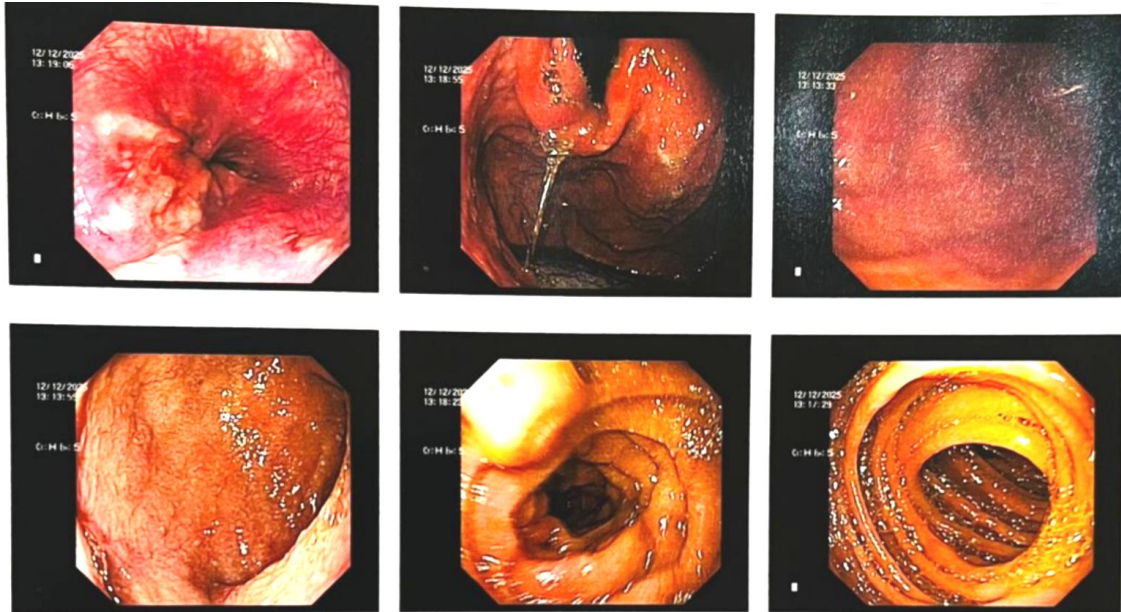


Figure 2: Upper gastrointestinal endoscopy findings showing diffuse erosive esophagitis with multiple lower esophageal ulcers extending from the mid-esophagus to the gastroesophageal junction. Gastric mucosa showed features of diffuse gastritis. Duodenal bulb, second part of the duodenum, and distal duodenum up to D3/D4 appeared normal, with no visible ulceration or perforation.

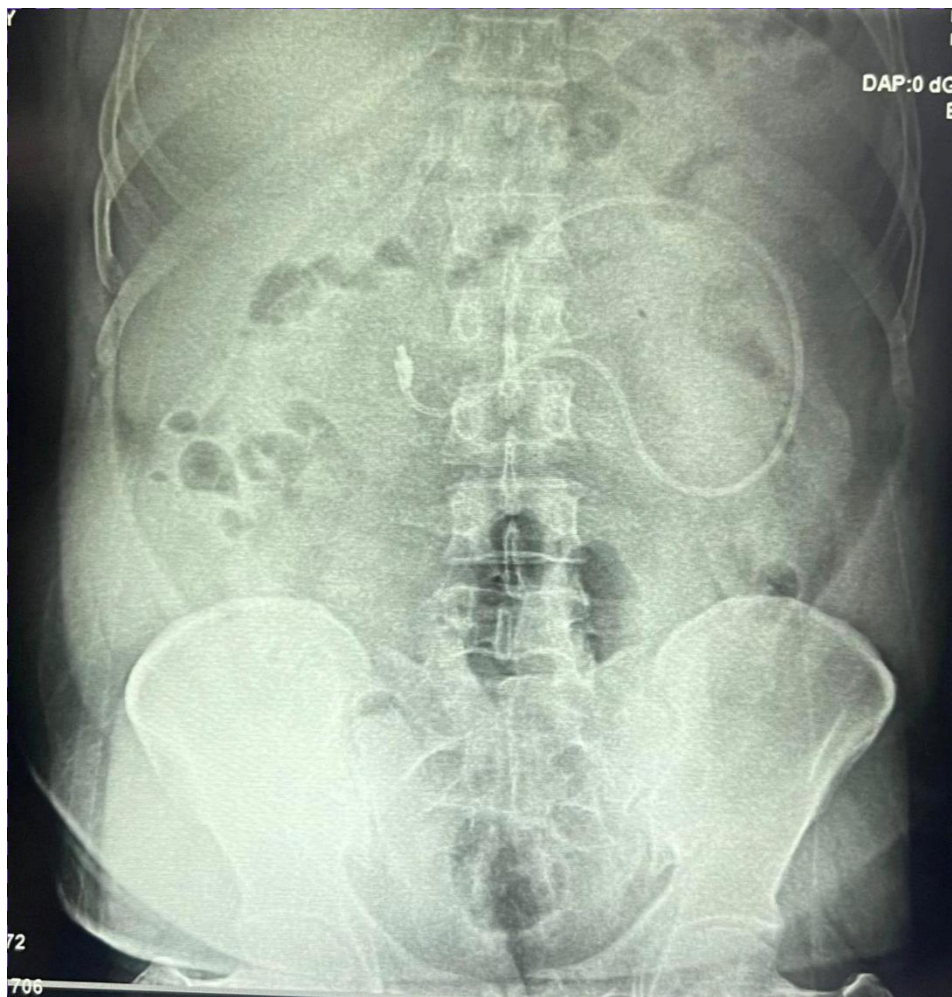

Figure 3: Endoscopic placement of a Freka's feeding tube for enteral nutritional support during conservative management.

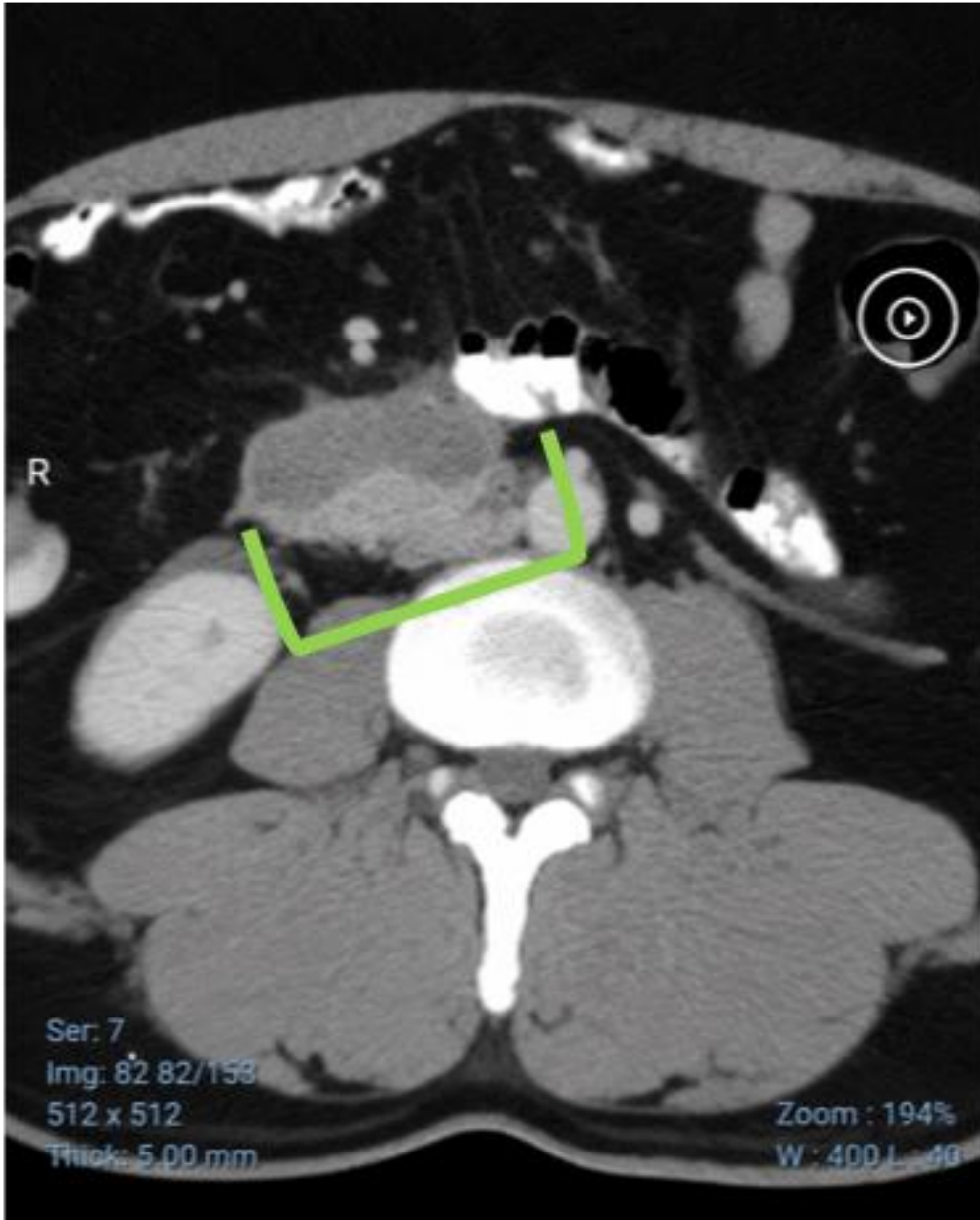


Figure 4: Follow-up contrast-enhanced CT abdomen showing interval reduction in the periduodenal fluid collection and inflammatory changes following conservative treatment.

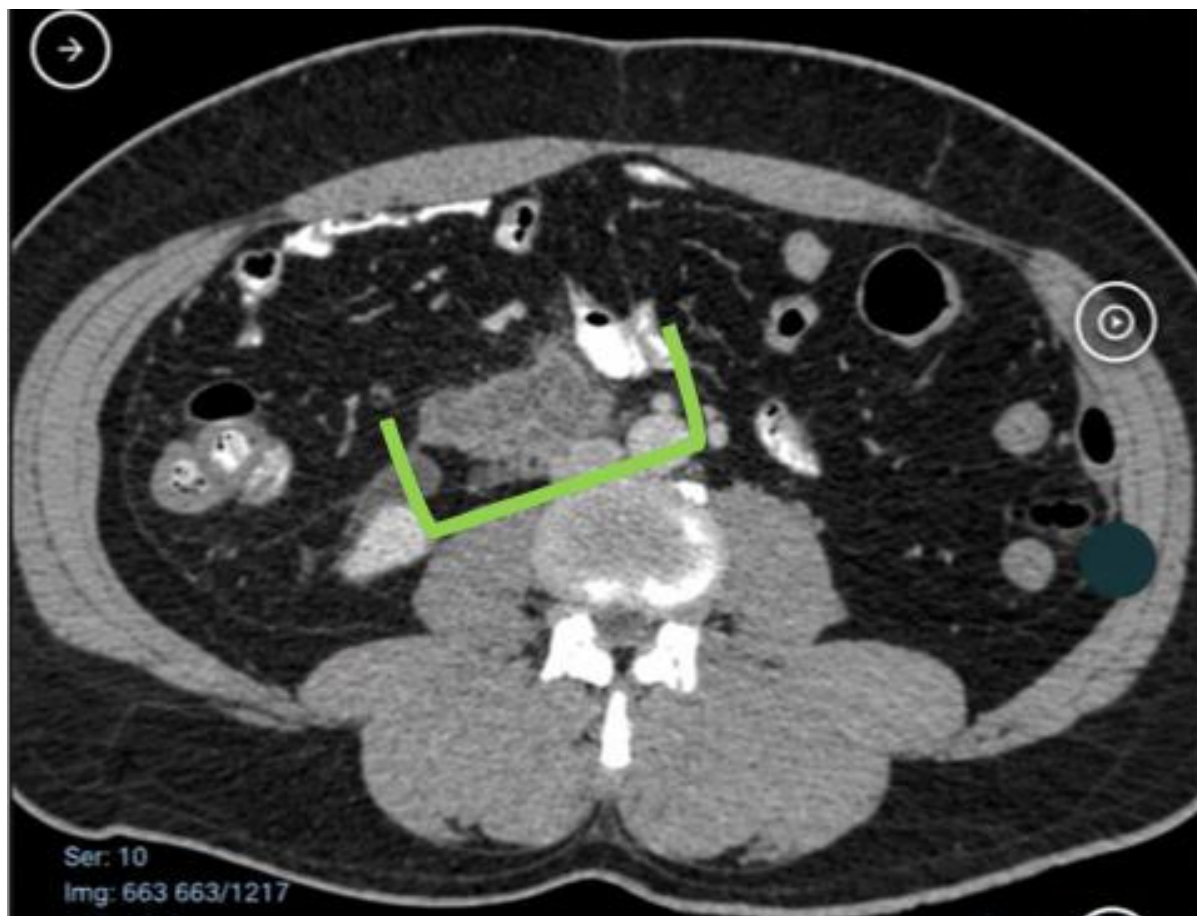


Figure 5: Follow-up imaging demonstrating near-complete resolution of the retroperitoneal collection with no evidence of ongoing duodenal leak or perforation.

III. DISCUSSION

This patient's presentation illustrates Valentino's syndrome, where a retroperitoneal duodenal ulcer perforation mimics acute appendicitis. Valentino's syndrome is noted as a rare but dangerous mimic of appendicitis.

The diagnostic process in this case highlights the complexities of Valentino's syndrome. While a perforated peptic ulcer typically presents with upper abdominal pain, its atypical presentation mimicking acute appendicitis poses a significant diagnostic challenge [4]. This phenomenon is especially critical in resource-limited settings where diagnostic capabilities might be constrained, potentially delaying definitive management [5].

The role of advanced imaging, particularly contrast-enhanced CT, is paramount in such ambiguous cases. In retroperitoneal perforation, plain X-ray often shows no free air, as in this case [3]. CT features of contained duodenal perforation include periduodenal fluid, retroperitoneal stranding, and duodenal wall defect or thickening. Here, CT showed a sizable periduodenal fluid collection and duodenal wall abnormalities without pneumoperitoneum, strongly suggesting a sealed duodenal ulcer perforation. This contrasts with typical appendicitis imaging (dilated appendix, peri-appendiceal fat stranding), which were absent. Similar cases report CT misleadingly suggesting appendicitis when abscesses form retroperitoneally; in one series a patient underwent laparotomy for presumed appendicitis, only to find a posterior duodenal ulcer and normal appendix [6].

Management of duodenal perforations, especially those contained within the retroperitoneal space, can be conservative in hemodynamically stable patients without generalized peritonitis [5]. This typically involves nil per os, intravenous fluids, broad-spectrum antibiotics, and high-dose PPIs. The successful conservative management in this patient, with gradual clinical improvement and resolution of pain and fever, aligns with strategies for selected stable patients with localized contamination. Surgical intervention is generally reserved for cases with signs of sepsis, generalized peritonitis, or when conservative measures fail [7].

IV. CONCLUSION

Valentino's syndrome, a rare presentation of perforated peptic ulcer mimicking acute appendicitis, demands a high index of clinical suspicion. This case underscores the diagnostic limitations of ultrasound and endoscopy for certain retroperitoneal pathologies and highlights the crucial role of contrast-enhanced CT in accurately identifying the underlying cause of abdominal pain. The successful conservative management with intravenous antibiotics and PPIs reinforces that non-operative treatment can be a safe and effective approach for contained duodenal perforations in stable patients, thus avoiding unnecessary surgical intervention

References:

- [1] Kara Carmo F, Santorcuato Cubillos F, Maldonado Schoijet I. Valentino's Syndrome: from History to Images. A Case-Based Literature Review. *Acta Gastroenterol Latinoam* 2023;53:188–92. <https://doi.org/10.52787/AGL.V53I2.313>.
- [2] Machaku D, Suleman M, Mduma E, Nkoronko M. Valentino's syndrome: a bizarre clinical presentation. *J Surg Case Rep* 2023;2023. <https://doi.org/10.1093/JSCR/RJAD035>.
- [3] Amini A, Lopez RA. Duodenal Perforation. *StatPearls [Internet]* 2023. https://doi.org/10.1007/978-3-642-29613-0_100518.
- [4] Nakarmi RN, Budha B, Chaudhary R, Sah S, Bajracharya S, Pandey A. Valentino's syndrome: diagnostic challenge of acute lower abdominal pain. *J Surg Case Rep* 2025;2025. <https://doi.org/10.1093/JSCR/RJAF934>.
- [5] Jayaprasad YDM, Peiris AG, Kularathna S, Madushan T, Jayaprasad YDM, Peiris A, et al. Navigating a Surgical Dilemma: Conservative Management of a Rare Case of Spontaneous Duodenal Perforation in a Resource-Limited Setting. *Cureus* 2025;17. <https://doi.org/10.7759/CUREUS.93098>.
- [6] Marano FR. Case Report: Suspected Valentino's Syndrome mimicking acute appendicitis: a case report and literature review. *F1000Research* 2026;15:1. <https://doi.org/10.12688/f1000research.174869.1>.
- [7] Dufera RR, Berake TB, Maliakkal B, Dufera RR, Berake TB, Maliakkal B. Post-endoscopic Retrograde Cholangiopancreatography Complications: A Case of Duodenal Perforation and Literature Review. *Cureus* 2023;15. <https://doi.org/10.7759/CUREUS.40303>.