

Incidental Findings On Digital Panoramic Radiographs Among Dental College Patients In Jaipur Population: A Retrospective Study

Author

Abstract

Background

Panoramic radiography, commonly known as orthopantomogram (OPG), is a routinely used diagnostic imaging modality in dentistry that provides a broad visualization of the maxillofacial complex including teeth, alveolar bone, mandible, maxilla, temporomandibular joints, and adjacent anatomical structures. While panoramic radiographs are primarily prescribed for evaluation of dental pathologies such as impacted teeth, orthodontic assessment, periodontal disease, or pre-prosthetic evaluation, they frequently reveal additional radiographic findings that are unrelated to the patient's presenting complaint. These findings, referred to as incidental findings, may represent developmental anomalies, pathological lesions, anatomical variations, or calcifications in adjacent soft tissues.

Early identification of these findings is clinically important because some incidental abnormalities may indicate systemic diseases or conditions requiring further investigation or intervention.

Aim -To evaluate the prevalence and spectrum of incidental findings detected on digital panoramic radiographs among patients attending a dental college

Objectives:

1. To identify the presence of incidental findings in orthopantomogram (OPG) radiographs.
2. To classify the different types of incidental findings detected in OPG images (dental, bony, and soft tissue findings).
3. To determine the prevalence of various incidental findings among the studied population.
4. To analyze the distribution of incidental findings according to age and gender of patients.
5. To assess the clinical significance of these incidental findings and their potential impact on patient management.

Materials and Methods

A retrospective cross-sectional study was conducted using digital panoramic radiographs obtained from the radiology Section of the Department of Oral Medicine and Radiology at Rajasthan Dental College and Hospital using Carestream 8200 3D machine. A total of 1500 panoramic radiographs taken between Oct 2025 and March 2026 were analyzed. Radiographs were evaluated for incidental findings unrelated to the primary indication for imaging. Findings were categorized into:

Dental findings

- Idiopathic calcifications
- Soft tissue calcifications
- Developmental anomalies
- Odontome
- Stafne cyst
- Elongated styloid process

Results

Among the evaluated radiographs, 10% demonstrated at least one incidental finding. The most common findings included:

Conclusion -Panoramic radiographs frequently reveal clinically significant incidental findings that may otherwise remain undetected. Careful systematic evaluation of all anatomical regions in panoramic radiographs is essential for comprehensive diagnosis and optimal patient management.

Keywords: Panoramic radiography, incidental findings, orthopantomogram, maxillofacial radiology, dental imaging.

Date of Submission: 13-05-2026

Date of Acceptance: 23-05-2026

I. Introduction

Panoramic radiography represents one of the most commonly used extraoral radiographic techniques in dental practice due to its ability to provide a comprehensive overview of the maxillofacial region in a single image. The orthopantomogram enables simultaneous visualization of the maxilla, mandible, teeth, temporomandibular joints, maxillary sinuses, nasal cavity, and surrounding anatomical structures. Compared with intraoral radiography, panoramic imaging offers several advantages including: wide anatomical coverage, lower radiation exposure compared with full-mouth intraoral series, improved patient comfort, rapid image acquisition. Due to these advantages, panoramic radiography is widely used for orthodontic assessment, evaluation of impacted teeth, detection of jaw lesions, trauma evaluation and assessment of developmental abnormalities. However, because panoramic radiographs encompass a broad anatomical field, they often reveal radiographic findings unrelated to the chief complaint of the patient. These findings are referred to as incidental findings.

Incidental findings may include: Dental findings, Impacted teeth, Supernumerary teeth, Retained root fragments, Osseous findings, Idiopathic osteosclerosis, Periapical radiolucencies, Fibro-osseous lesions, Soft tissue calcifications, Stylohyoid ligament calcification, Tonsilloliths, Carotid artery calcifications, Temporomandibular joint changes, Condylar flattening, Osteophytes, Degenerative joint disease. Detection of such findings may lead to early diagnosis of conditions that could otherwise remain asymptomatic. In certain cases, incidental findings may indicate potentially serious conditions such as vascular calcifications associated with cardiovascular disease. Therefore, a systematic interpretation of panoramic radiographs is essential for comprehensive patient care.

The present study was undertaken to evaluate the prevalence and types of incidental findings observed in digital panoramic radiographs among patients attending a dental teaching institution.

II. Aim And Objectives

Aim -To evaluate the prevalence of incidental findings detected in digital panoramic radiographs of dental patients.

Objectives

- I. To identify the types of incidental findings present in panoramic radiographs.
- II. To categorize incidental findings into dental, osseous, TMJ, and soft tissue calcifications.
- III. To determine the frequency distribution of these findings among different age groups.
- IV. To emphasize the importance of systematic radiographic interpretation.

III. Materials And Methods

Study Design– A Retrospective cross-sectional study conducted in the Department of Oral Medicine and Radiology, Rajasthan Dental College and Hospital, Jaipur. From October 2025 to February 2026. A total of digital panoramic radiographs were included in the study.

Inclusion Criteria

- Patients aged above 14 years
- High-quality digital panoramic radiographs
- Radiographs taken for routine dental diagnostic purposes

Exclusion Criteria

- Poor quality radiographs
- Patients with known maxillofacial pathologies already under treatment
- Radiographs with positioning errors or artifacts
- Radiographic Evaluation

All radiographs were evaluated using digital imaging software under standardized viewing conditions. Each panoramic radiograph was systematically examined in the following sequence: Teeth and alveolar bone, Maxilla and mandible, Maxillary sinus, Temporomandibular joints, Soft tissue structures

Classification of Incidental Findings

1. Dental findings

- Impacted teeth
- Retained roots
- Supernumerary teeth

2. Jaw bone findings

- Idiopathic osteosclerosis
- Periapical pathology
- Fibro-osseous lesions

3. Soft tissue calcifications

- Stylohyoid ligament calcification
- Tonsilloliths
- Sialoliths
- Carotid artery calcification

Statistical Analysis -Data were entered into Microsoft Excel and analyzed using SPSS v 26 software.

Descriptive statistics including: frequency, percentage distribution were used to determine prevalence of incidental findings. Chi-square test may be applied to evaluate association between age and type of incidental findings.

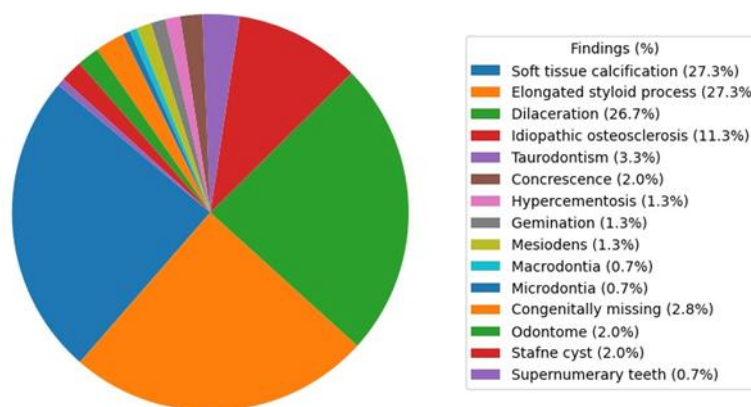
IV. Results

Out of the total 1500 radiographic cases examined, 150 cases exhibited incidental findings, resulting in an overall prevalence of 10.0%. This indicates that approximately one in every ten individuals in the studied population presented with at least one incidental radiographic finding.

Table 1: Distribution of Incidental Finding

Variable	Male (n=99)	Female (n=51)	Total (n=150)
Any Impaction Present	49 (49.5%)	25 (49.0%)	74 (49.3%)
• Upper Third Molar	23 (23.2%)	12 (23.5%)	35 (23.3%)
• Lower Third Molar	29 (29.3%)	15 (29.4%)	44 (29.3%)
• Canine	4 (4.0%)	3 (5.9%)	7 (4.7%)
• Premolar	3 (3.0%)	2 (3.9%)	5 (3.3%)
Retained Deciduous Teeth	17 (17.2%)	10 (19.6%)	27 (18.0%)
Supernumerary Teeth	1 (1.0%)	0 (0.0%)	1 (0.7%)
Idiopathic Osteosclerosis	11 (11.1%)	6 (11.8%)	17 (11.3%)
Soft Tissue Calcification	27 (27.3%)	14 (27.5%)	41 (27.3%)
Elongated Styloid Process	27 (27.3%)	14 (27.5%)	41 (27.3%)
Gemination/Fusion	1 (1.0%)	1 (2.0%)	2 (1.3%)
Dilaceration	26 (26.3%)	14 (27.5%)	40 (26.7%)
Hypercementosis	1 (1.0%)	1 (2.0%)	2 (1.3%)
Concrescence	2 (2.0%)	1 (2.0%)	3 (2.0%)
Taurodontism	3 (3.0%)	2 (3.9%)	5 (3.3%)
Mesiodens	1 (1.0%)	1 (2.0%)	2 (1.3%)
Macrodonia	1 (1.0%)	0 (0.0%)	1 (0.7%)
Microdonia	0 (0.0%)	1 (2.0%)	1 (0.7%)
Congenitally Missing Teeth	3 (3.0%)	1 (2.0%)	4 (2.7%)
Odontome	2 (2.0%)	1 (2.0%)	3 (2.0%)
Stafne Cyst	1 (1.0%)	2 (3.9%)	3 (2.0%)

Prevalence of Dental Anomalies (n=150)



Age Distribution - The age distribution of the study population revealed that the majority of participants were in the younger and middle age groups. The highest proportion was observed in the 21–30 years age group (38 participants; 25.3%), followed closely by the 31–40 years group (36 participants; 24.0%) and 41–50 years group (34 participants; 22.7%). Participants aged ≤20 years and 51–60 years each constituted 7.3% of the sample. Older age groups were less represented, with 61–70 years accounting for 9.3%, and only 2.0% each in the 71–80 and ≥81 years categories.

Variable	≤20 (n=11)	21–30 (n=38)	31–40 (n=36)	41–50 (n=34)	51–60 (n=11)	≥61 (n=20)	Total (n=150)
Any Impaction Present	6 (54.5%)	24 (63.2%)	18 (50.0%)	14 (41.2%)	5 (45.5%)	7 (35.0%)	74 (49.3%)
• Upper Third Molar	3 (27.3%)	12 (31.6%)	9 (25.0%)	6 (17.6%)	2 (18.2%)	3 (15.0%)	35 (23.3%)
• Lower Third Molar	4 (36.4%)	16 (42.1%)	11 (30.6%)	7 (20.6%)	2 (18.2%)	4 (20.0%)	44 (29.3%)
• Canine	2 (18.2%)	3 (7.9%)	1 (2.8%)	1 (2.9%)	0 (0.0%)	0 (0.0%)	7 (4.7%)
• Premolar	1 (9.1%)	2 (5.3%)	1 (2.8%)	1 (2.9%)	0 (0.0%)	0 (0.0%)	5 (3.3%)
Retained Deciduous Teeth	5 (45.5%)	10 (26.3%)	6 (16.7%)	4 (11.8%)	1 (9.1%)	1 (5.0%)	27 (18.0%)
Supernumerary Teeth	1 (9.1%)	0 (0.0%)	0 (0.0%)	0 (0.0%)	0 (0.0%)	0 (0.0%)	1 (0.7%)
Idiopathic Osteosclerosis	1 (9.1%)	5 (13.2%)	4 (11.1%)	4 (11.8%)	1 (9.1%)	2 (10.0%)	17 (11.3%)
Soft Tissue Calcification	1 (9.1%)	8 (21.1%)	10 (27.8%)	12 (35.3%)	4 (36.4%)	6 (30.0%)	41 (27.3%)
Elongated Styloid Process	1 (9.1%)	7 (18.4%)	10 (27.8%)	13 (38.2%)	4 (36.4%)	6 (30.0%)	41 (27.3%)
Gemination/Fusion	1 (9.1%)	1 (2.6%)	0 (0.0%)	0 (0.0%)	0 (0.0%)	0 (0.0%)	2 (1.3%)
Dilaceration	2 (18.2%)	9 (23.7%)	11 (30.6%)	10 (29.4%)	3 (27.3%)	5 (25.0%)	40 (26.7%)
Hypercementosis	0 (0.0%)	0 (0.0%)	1 (2.8%)	0 (0.0%)	0 (0.0%)	1 (5.0%)	2 (1.3%)
Concrescence	0 (0.0%)	1 (2.6%)	1 (2.8%)	1 (2.9%)	0 (0.0%)	0 (0.0%)	3 (2.0%)
Taurodontism	0 (0.0%)	2 (5.3%)	1 (2.8%)	1 (2.9%)	0 (0.0%)	1 (5.0%)	5 (3.3%)
Mesiodens	1 (9.1%)	1 (2.6%)	0 (0.0%)	0 (0.0%)	0 (0.0%)	0 (0.0%)	2 (1.3%)
Macrodonia	0 (0.0%)	1 (2.6%)	0 (0.0%)	0 (0.0%)	0 (0.0%)	0 (0.0%)	1 (0.7%)
Microdonia	0 (0.0%)	0 (0.0%)	0 (0.0%)	1 (2.9%)	0 (0.0%)	0 (0.0%)	1 (0.7%)
Congenitally Missing Teeth	0 (0.0%)	2 (5.3%)	1 (2.8%)	1 (2.9%)	0 (0.0%)	0 (0.0%)	4 (2.7%)
• Odontome	0 (0.0%)	1 (2.6%)	1 (2.8%)	1 (2.9%)	0 (0.0%)	0 (0.0%)	3 (2.0%)
• Stafne Cyst	0 (0.0%)	0 (0.0%)	1 (2.8%)	1 (2.9%)	0 (0.0%)	1 (5.0%)	3 (2.0%)

Age Group (years)	Frequency (n)	Percentage (%)
≤20	11	7.3%
21–30	38	25.3%
31–40	36	24.0%
41–50	34	22.7%
51–60	11	7.3%
61–70	14	9.3%
71–80	3	2.0%
≥81	3	2.0%
Total	150	100.0%

Gender Distribution- The study population consisted of 150 participants, of which 99 (66.0%) were males and 51 (34.0%) were females. A slightly higher prevalence was observed in male patients compared to females.

Association Between Age and Incidental Findings

Statistical analysis using Chi-square test showed a significant association between age group and prevalence of incidental findings ($p < 0.05$).

V. Discussion

Panoramic radiography remains a fundamental diagnostic tool in dental practice due to its ability to provide a comprehensive overview of the maxillofacial region in a single radiograph. The wide anatomical coverage provided by panoramic imaging allows clinicians not only to assess dental structures but also to identify additional abnormalities within adjacent anatomical regions. The present study evaluated the prevalence and pattern of incidental findings in digital panoramic radiographs among patients attending Rajasthan dental college for a period of six month as mentioned above. A significant proportion of radiographs demonstrated incidental findings, emphasizing the importance of careful radiographic interpretation.

The gender-based cross-tabulation analysis demonstrated that impaction was the most prevalent finding, observed in 74 (49.3%) participants, with comparable distribution among males (49.5%) and females (49.0%). Lower third molar impaction (44; 29.3%) was more frequent than upper third molar impaction (35; 23.3%), while canine (7; 4.7%) and premolar (5; 3.3%) impactions were relatively uncommon. Retained deciduous teeth were observed in 27 (18.0%) cases, with slightly higher prevalence among females (19.6%) compared to males (17.2%).

Among radiographic findings, soft tissue calcification and elongated styloid process were the most common, each present in 41 (27.3%) cases, followed closely by dilaceration in 40 (26.7%) cases. Idiopathic osteosclerosis was noted in 17 (11.3%) participants. Developmental anomalies such as gemination (1.3%), hypercementosis (1.3%), concrescence (2.0%), taurodontism (3.3%), mesiodens (1.3%), macrodontia (0.7%), and microdontia (0.7%) were relatively rare.

Congenitally missing teeth were observed in 4 (2.7%) cases, while odontomes and Stafne cysts were each present in 3 (2.0%) cases. Most anomalies showed a slight male predominance; however, microdontia and Stafne cyst were more frequently observed in females. Overall, the findings suggest a comparable distribution of major anomalies between genders, with minor variations across specific conditions.

The findings of this study highlight that panoramic radiographs should be interpreted systematically by examining all anatomical structures rather than focusing only on the region of interest. Failure to recognize incidental findings may result in missed diagnoses and delayed treatment.

Clinical Significance

Detection of incidental findings in panoramic radiographs can facilitate early diagnosis of asymptomatic conditions, prevent progression of pathological lesions, aid in identifying systemic diseases such as vascular calcifications and improve overall patient management. Therefore, dental practitioners should adopt a systematic approach while interpreting panoramic radiographs.

Limitations

- Retrospective study design
- Limited sample size
- Lack of clinical correlation in certain cases
- Future multicenter studies with larger sample sizes are recommended.

VI. Conclusion

Digital panoramic radiography frequently reveals incidental findings that may have important clinical implications. The results of the present study demonstrate that a considerable number of patients exhibit radiographic findings unrelated to their chief complaint. A systematic and comprehensive evaluation of all anatomical structures in panoramic radiographs is essential to ensure accurate diagnosis and optimal patient care.

References

- [1]. Alharbi HS, Aldukhail S, Elkhateeb SM. Incidental Findings In Digital Panoramic Radiographs Among Dental School Patients.
- [2]. White SC, Pharoah MJ. Oral Radiology: Principles And Interpretation. 8th Ed.
- [3]. Rushton VE, Homer K. The Use Of Panoramic Radiology In Dental Practice.
- [4]. Carter LC, Haller AD. Common Incidental Findings On Panoramic Radiographs.
- [5]. Langlais RP, Langland OE. Principles Of Dental Imaging.
- [6]. Goyal G, Padma S, Kaur B. Unusual Incidental Findings On Intra-And Extra-Oral Radiographs In North Indian Population: A Radiographic Study. *Journal Of Dental And Allied Sciences*. 2016 Jul 1;5(2):74.
- [7]. Henriques JC, Kreich EM, Baldani MH, Luciano M, De Melo Castilho JC, De Moraes LC. Panoramic Radiography In The Diagnosis Of Carotid Artery Atheromas And The Associated Risk Factors. *The Open Dentistry Journal*. 2011;5:79.
- [8]. Ramadurai J., Umamaheswari T. N. The Prevalence Of Oral And Maxillofacial Soft Tissue Calcifications In Dental Panoramic Radiography: A Retrospective Study. *International Journal Of Maxillofacial Imaging*, 2018;4(3):82-86.
- [9]. Head T, Daunert S, Goldschmidt-Clermont PJ. The Aging Risk And Atherosclerosis: A Fresh Look At Arterial Homeostasis. *Frontiers In Genetics*. 2017 Dec 14;8:216.
- [10]. Yoon SJ, Yoon W, Kim OS, Lee JS, Kang BC. Diagnostic Accuracy Of Panoramic Radiography In The Detection Of Calcified Carotid Artery. *Dentomaxillofacial Radiology*. 2008 Feb;37(2):104-7.
- [11]. Sisman Y, Ertas ET, Gokce C, Menku A, Ulker M, Akgunlu F. The Prevalence Of Carotid Artery Calcification On The Panoramic Radiographs In Cappadocia Region population. *European Journal Of Dentistry*. 2007 Jul;1(3):132.
- [12]. Taheri JB, Moshfeghi M. Prevalence Of Calcified Carotid Artery On Panoramic Radiographs In Postmenopausal Women. *Journal Of Dental Research, Dental Clinics, Dental Prospects*. 2009;3(2):46.
- [13]. Balaji Babu B, Avinash Tejasvi ML, CK AA, Chittaranjan B. Tonsilloolith: A Panoramic Radiograph Presentation. *Journal Of Clinical And Diagnostic Research: JCDR*. 2013 Oct;7(10):2378.
- [14]. Barghan S, Tahmasbi Arashlow M, Nair MK. Incidental Findings On Cone Beam Computed Tomography Studies Outside Of The Maxillofacial Skeleton. *International Journal Of Dentistry*. 2016.
- [15]. Chan J, Rashid M, Karagama Y. An Unusual Case Of A Tonsilloolith. *Case Reports In Medicine*. 2012.
- [16]. Dau M, Marciak P, Al-Nawas B, Staedt H, Alshiri A, Frerich B, Kämmerer PW. Evaluation Of Symptomatic Maxillary Sinus Pathologies Using Panoramic Radiography And Cone Beam Computed Tomography—Influence Of Professional Training. *International Journal Of Implant Dentistry*. 2017 Dec;3(1):13.
- [17]. Gujrathi A, Wakode PT. Haziness In X-Ray Paranasal Sinus Water's View In Sinusitis: A Fact Or Fiction. *Indian Journal Of Otolaryngology And Head & Neck Surgery*. 2013 Aug 1;65(2):242-6.
- [18]. Garay I, Netto HD, Olate S. Soft Tissue Calcified In Mandibular Angle Area Observed By Means Of Panoramic Radiography. *International Journal Of Clinical And Experimental Medicine*. 2014;7(1):51.
- [19]. Sharan A, Madjar D. Maxillary Sinus Pneumatization Following Extractions: A Radiographic Study. *International Journal Of Oral & Maxillofacial Implants*. 2008 Jan 1;23(1).