

# Emerging Radiological Patterns Of Pulmonary Tuberculosis In Immuno-Competent Host - A Case Series

A. A. Saibannavar, Harshita Mittal

Professor And Head, Department Of Pulmonary Medicine, RCSM GMC, Kolhapur, Maharashtra  
PG Student, Department Of Pulmonary Medicine, RCSM GMC, Kolhapur, Maharashtra

---

## Abstract

**Background:** Pulmonary tuberculosis (PTB) classically presents with cavitation or upper lobe infiltrations which is a hallmark radiological feature of PTB. It usually manifests as single cavitary consolidation mostly in the upper lobe (apical and posterior segments) 1,3. Later in HIV era, pulmonary TB presentation have diversified with lower lobe involvement and diffuse pulmonary disease becoming more common due to profound immunosuppression and low CD4 counts. 1,2 However, with the growing prevalence of comorbidities such as diabetes, malnutrition, alcoholism etc, unusual and diffuse radiological patterns are also seen in Non-HIV patients. This case series aims to highlight such emerging unusual radiological presentations in non-HIV immune-competent patients.

**Methods:** A case series study was conducted on eight non-HIV patients who were diagnosed with pulmonary TB at our tertiary care centre. Clinical data, comorbidities, and radiological findings were reviewed for deviations from classical TB presentations.

**Results:** All patients exhibited unusual radiological findings, notably bilateral multiple cavitary lesions. These radiological lesions resembled those seen in bronchopneumonia, septic emboli, and fungal infections. None had profound immunosuppression predisposition or HIV.

**Conclusion:** Pulmonary TB can present with unusual radiological findings in non-HIV patients, mimicking other infectious and inflammatory pulmonary conditions. Awareness of such presentations is crucial for timely diagnosis and management, especially in the context of rising comorbidities like diabetes mellitus and our goal of TB elimination in near future.

**Keywords-** Pulmonary tuberculosis, extensive lung and radiological involvement, immune-competent host, non-HIV patients.

---

Date of Submission: 23-04-2026

Date of Acceptance: 03-05-2026

---

## I. Introduction

Tuberculosis remains a significant global health burden particularly in lower- and middle-income countries, where it substantially contributes to morbidity and mortality.<sup>4</sup> Its pathogenicity is largely attributed to its capacity for intracellular survival within alveolar macrophages, facilitated by mechanisms that inhibit phagosome-lysosome fusion. The host immune response to persistent infection results in granuloma formation and central caseous necrosis, hallmark features of tuberculosis. Transmission primarily occurs via inhalation of aerosolized droplet nuclei from individuals with active pulmonary disease, with the lungs serving as the principal site of infection due to the organism's predilection for oxygen-rich environments.<sup>5,6</sup>

Classically pulmonary tuberculosis presents with symptoms such as chronic cough (more than 2 weeks), fever, night sweats, haemoptysis and significant weight loss. Radiologically, it is commonly characterised by upper lobe infiltrates, fibronodular opacities, endobronchial spread and cavitary lesions typically located in apical and posterior segments of upper lobe. Atypical radiological presentations such as lower lung field involvement, miliary pattern, extrapulmonary involvement are more commonly seen in moderate to severe immunosuppression secondary to dysregulated immune responses and compromised host defences.

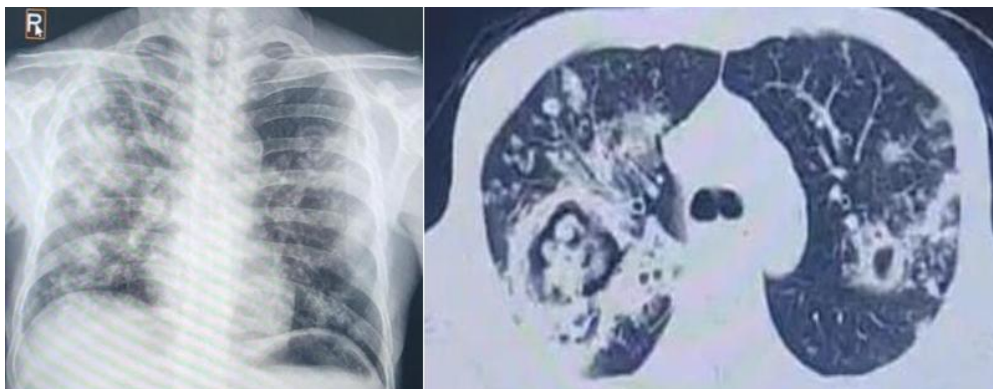
This study aims to explore and characterize the emerging unusual radiological patterns of pulmonary TB in immunocompetent hosts, assess their clinical and microbiological correlation, and highlight their diagnostic implications. By improving awareness of these emerging unusual radiological patterns, we hope to aid clinicians and radiologists in recognizing TB even when it deviates from its classic presentation.

## II. Cases-

Case 1:

A 35-year-old male patient presented with chief complaints of productive cough for 2 months, fever with evening rise of temperature and night sweats since 1-month, streaky haemoptysis on and off since 1 month with one episode of massive haemoptysis (approx. 500ml). He was a known case of diabetes mellitus (controlled) for 1 year. He also had a history of chronic alcohol consumption and tobacco chewing for 20 years. His lab

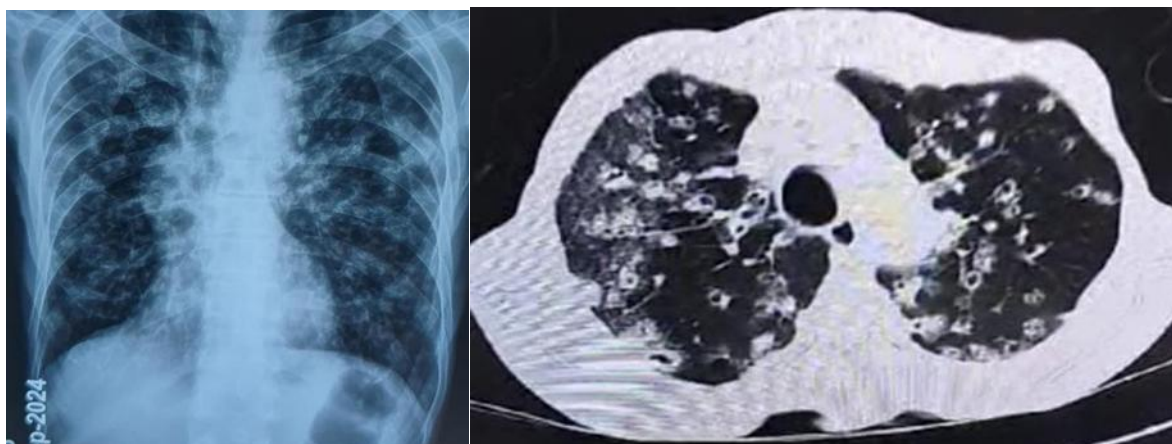
investigations showed leucocytosis with WBC count of 20,000/mm<sup>3</sup>, Hb 13.3 gm% and platelet count 4.5 lakh/mm<sup>3</sup>. Renal and liver function tests were within normal limits. HBA1C was 5.6% along with normal fasting and random blood sugar levels. CXR PA view suggestive of right upper zone and left lower zone infiltrates with patchy inhomogeneous opacities in right middle zone. HRCT Thorax showed multiple cavitary lesions with surrounding consolidation in bilateral lung parenchyma. Sputum samples were sent for bacterial, fungal and mycobacteria tuberculosis, which tested positive for mycobacterium tuberculosis and rest of the cultures were negative.



Case 1: Chest x-ray and HRCT Thorax images

Case 2:

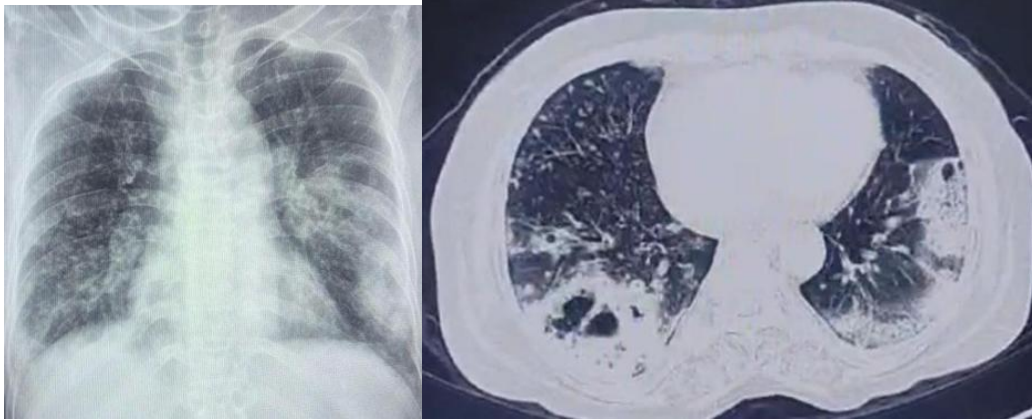
A 65-year-old male patient with no comorbidities and no addiction history presented with a 3 months history of evening rise of temperature, productive cough, anorexia, weight loss and shortness of breath. On general examination, the patient appeared ill and malnourished. His lab investigations showed leucocytosis with WBC counts of 15,000/mm<sup>3</sup>, haemoglobin of 10 gm% and platelet count 1.5 lakh/mm<sup>3</sup>. Renal and liver function tests were within normal limits. Chest radiograph revealed bilateral lung infiltrates with cavitations. HRCT thorax showed bilateral multiple tiny cavitations in bilateral lung parenchyma mimicking septic emboli. All cultures (blood, sputum, and urine) were negative. Sputum was positive for MTB, and Antitubercular therapy was initiated.



Case 2: Chest x-ray and HRCT Thorax images

Case 3:

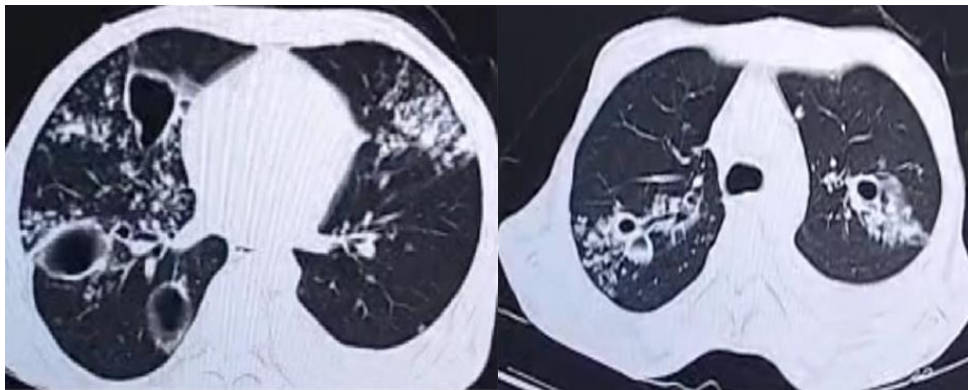A 60-year-old female patient presented with a history of cough with expectoration and fever for 8 days associated with increased dyspnoea for the past 2 days. She was a known case of obstructive airway disease and had been on salmeterol and fluticasone dry powder inhaler for the last 2 years. She had no other comorbidities. Her laboratory investigations revealed leucocytosis with a total WBC counts of 23,500/mm<sup>3</sup>, haemoglobin of 11.2 gm% and platelet count 1.05 lakh/mm<sup>3</sup>. Renal and liver function tests were within normal limits. X-ray chest showed bilateral middle and lower zone infiltrates along with cavitary consolidation. HRCT thorax showed multiple cavitations with surrounding consolidations in right middle, left lingula and bilateral lower lobes, features suggestive of cavitary pneumonia. Sputum analysis was done to rule out any bacterial or fungal pneumonia which was negative, but positive for mycobacterium tuberculosis.



Case 1: Chest x-ray and HRCT Thorax images

Case 4:

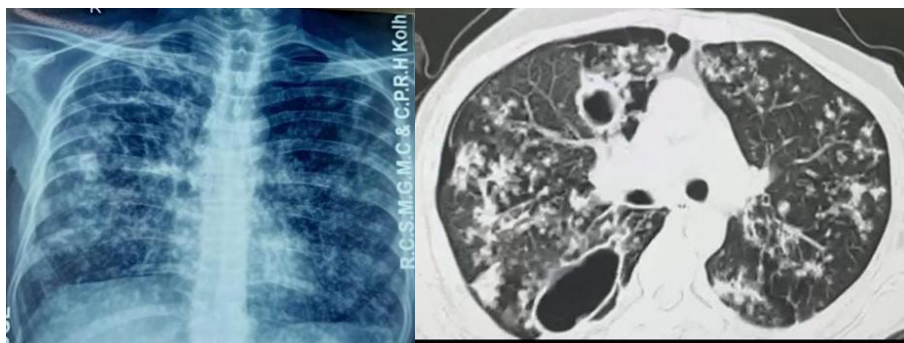
A 25-year-old male patient presented with 2 months history of cough with yellowish expectoration, evening rise of temperature, loss of appetite and weight (approximately 15 kg) and generalized weakness. He had a history of alcohol consumption and tobacco chewing for 5 years. On examination, he was malnourished and anaemic with haemoglobin of 4.2 gm%. Rest other blood investigations were within normal limits. HRCT thorax showed bilateral cavitary consolidations in multiple lobes. Sputum studies turned out positive for MTB.



Case 5: HRCT Thorax images

Case 5.

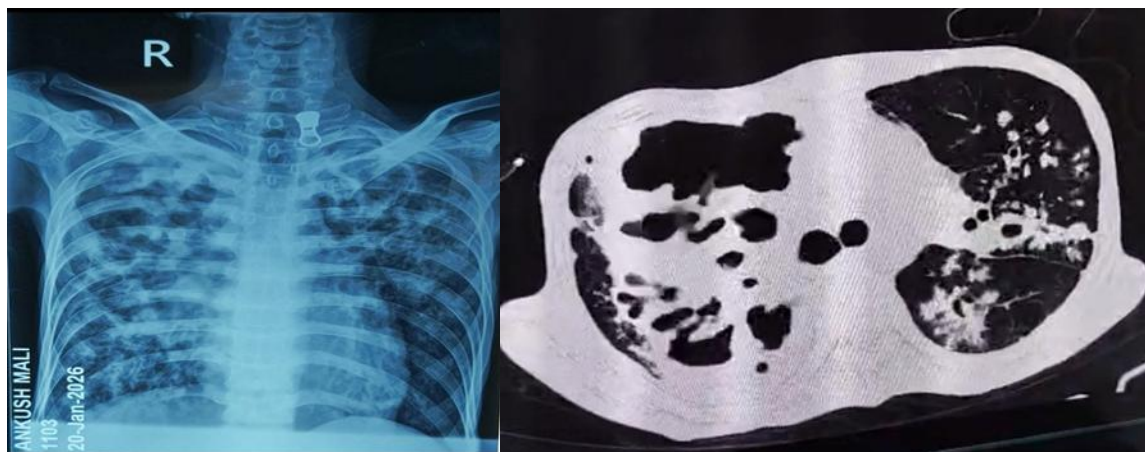
A 40-year-old male patient presented with complaints of cough with expectoration for 1 month, breathlessness for 1 month, decreased appetite and intermittent fever since 15 days. He had no other comorbidities but gave history of alcohol consumption (approximately 4 quarters/day) for the past 15 years. On evaluation, blood investigations showed leucocytosis with WBC counts of 28,500/mm<sup>3</sup>, haemoglobin of 12.2 gm% and platelet count 1.5 lakh/mm<sup>3</sup>. Renal and liver function tests were within normal limits. Chest radiograph showed bilateral infiltrates with cavitations. HRCT Thorax showed multiple thick walled cavitations with centrilobular nodules and tree in bud pattern in bilateral lung parenchyma. Sputum CBNAAT was MTB detected and rifampicin sensitive.



Case 5: Chest x-ray and HRCT Thorax images

Case 6:

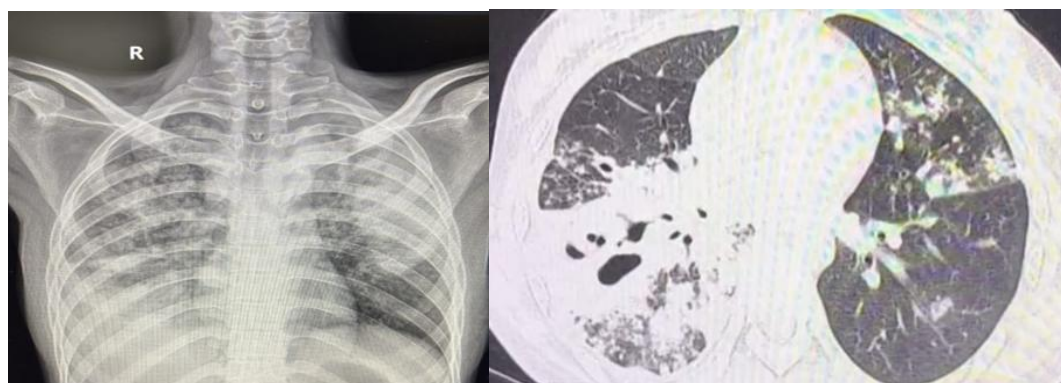A 32-year-old male patient presented with 2 months history of decreased appetite and weight (approx. 10 kgs), fever with evening rise of temperature, cough with expectoration for 2 months along with breathlessness for 10 days. He had no other comorbidities but gave history of alcohol consumption (approximately 4-5 quarters/day) for past 4 years. On evaluation, blood investigations showed leucocytosis with WBC counts of  $19,100/\text{mm}^3$ , haemoglobin of 8.8 gm% and platelet count  $1.5 \text{ lakh}/\text{mm}^3$ . Renal and liver function tests were within normal limits. Chest radiograph showed bilateral infiltrates with cavitations. HRCT Thorax showed multiple thick walled cavitations with centrilobular nodules and tree in bud pattern in bilateral lung parenchyma (right more than left). Sputum AFB was positive (3+) and sputum CBNAAT was MTB detected and rifampicin sensitive.



Case 6: Chest x-ray and HRCT Thorax images

Case 7:

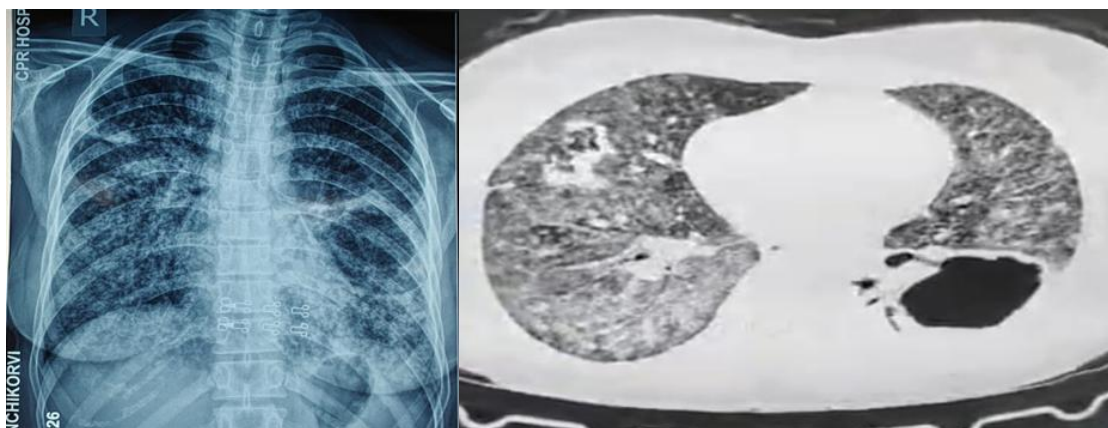
A 23-year-old female patient presented with 1 month history of decreased appetite and weight, fever (high grade) with morning rise of temperature, cough with yellowish expectoration along with breathlessness for 15 days. She had no other comorbidities and no addiction history. On evaluation, blood investigations showed leucocytosis with WBC counts of  $20,000/\text{mm}^3$ , haemoglobin of 9.8 gm% and platelet count  $1.5 \text{ lakh}/\text{mm}^3$ . Renal and liver function tests were within normal limits. Chest radiograph showed bilateral infiltrates with right lower zone consolidation. HRCT Thorax showed cavitory consolidation with centrilobular nodules and tree in bud pattern in bilateral lung parenchyma (right more than left). Sputum AFB was positive (2+) and sputum CBNAAT was MTB detected and rifampicin sensitive.



Case 7: Chest x-ray and HRCT Thorax images

Case 8:

A 25-year-old female patient presented with 3 months history of decreased appetite and weight, fever, cough with expectoration along with breathlessness. She had no other comorbidities and no addiction history. On evaluation, blood investigations showed leucocytosis with WBC counts of  $24,000/\text{mm}^3$ , haemoglobin of 9 gm% and platelet count  $2.6 \text{ lakh}/\text{mm}^3$ . Renal and liver function tests were within normal limits. Chest radiograph showed miliary mottling. HRCT Thorax showed miliary nodules in bilateral lung parenchyma with cavitory consolidation in left lower lobe. Sputum AFB was positive (3+) and sputum CBNAAT was MTB detected and rifampicin sensitive.



Case 8: Chest x-ray and HRCT Thorax images

### III. Discussion

Pulmonary tuberculosis (PTB) typically presents with well-characterized radiological features including upper lobe infiltrations, miliary mottling, centrilobular nodules, tree-in-bud opacities, and cavitory lesions predominantly in the upper lobes (apical and posterior segments)<sup>1</sup> and superior segments of the lower lobes<sup>7,11,15</sup> as shown in fig. 1 and table no.1. These hallmark findings often guide early clinical suspicion and diagnosis, particularly in endemic regions. The upper lobe predilection in classic PTB cases is largely attributed to relatively high partial pressure of oxygen in these areas because of higher pulmonary ventilation/perfusion ratio, or a lower lymphatic drainage, resulting from a decreased pulmonary arterial flow, favouring the growth of mycobacterium tuberculosis.<sup>7,16</sup>

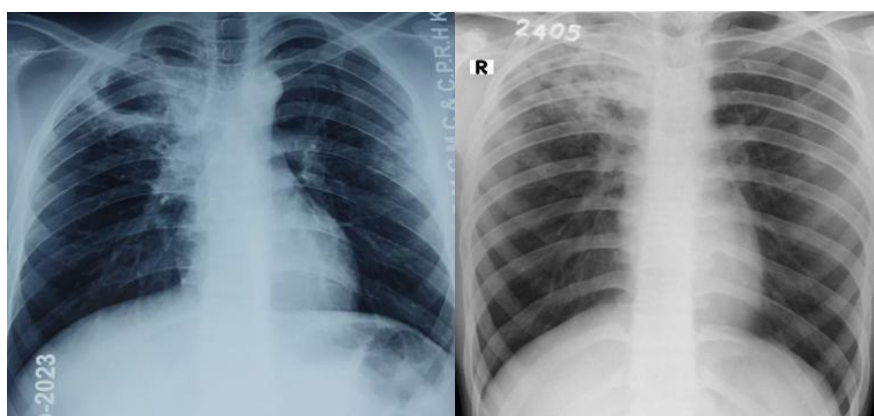


Figure no. 1 Typical radiological finding of Pulmonary tuberculosis

**Table no.1 - Radiological presentation of Pulmonary tuberculosis**

Primary pulmonary TB	Post primary TB	Immunocompromised host
Lymphadenopathy	Cavitation	Intrathoracic lymph node TB
Parenchymal consolidation	Local exudative and fibro-productive lesion	Lower lung field involvement
Tuberculoma	Tuberculoma	Less prevalence of cavitation
Miliary TB	Miliary TB	Miliary or disseminated disease
Pleural effusion	Bronchogenic spread	Extra pulmonary involvement
Airway involvement	Broncho-stenosis	Pleural and pericardial effusions
	Pleural disease	

In contrast, involvement of lower lung zones, multilobe disease, and diffuse bilateral cavitation have traditionally been associated with immunocompromised states such as HIV, AIDS, cancer, chemotherapy, prolonged steroid therapy, organ transplant, malnutrition causing impaired cell-mediated immunity. However, the present case series highlights an evolving spectrum of radiological manifestations of PTB occurring in immunocompetent hosts, challenging the conventional imaging paradigm. This localization often results in a diagnostic delay due to lower clinical suspicion, especially in patients without classical risk factors or in settings where TB is not the most immediate differential diagnosis<sup>8</sup>.

The causes of diagnostic delays are multifactorial (table no.2). These include patient delay (the time between symptom onset and seeking medical attention) and doctor's delay (the time from first medical consultation to correct diagnosis). These delays increase the risk of chronic pulmonary damage and relapse.<sup>9,10</sup>

**Table no.2 Causes of diagnostic delays**

<b>Patients' factor</b>	<b>Doctors' factor</b>
Under-recognition of early subtle symptoms	Misdiagnosis/underdiagnosis
Poor awareness and low health literacy	Delayed diagnostic workup
Use of off the counter drugs	Multiple antibiotics trial
Low socioeconomic status	Delayed specialist referral

In our series, patients without overt immunosuppression demonstrated unusual and extensive radiological patterns, including multi-lobar cavitory disease, bilateral lung involvement, lower and middle lobe predominance, and associated tree-in-bud nodularity. Such patterns closely mimicked other infectious and non-infectious pulmonary conditions, including cavitory bacterial pneumonia, fungal infections, septic emboli, and malignancy. These findings underscore the growing recognition that PTB in immunocompetent individuals may no longer conform strictly to classical radiological descriptions.

Lower lung field tuberculosis (LLF-TB), though uncommon, has been previously described in certain subsets of patients, particularly those with HIV, diabetes mellitus, chronic alcohol consumption, malnutrition, or advanced age. Several patients in our series had metabolic or lifestyle-related comorbidities which although not constituting frank immunosuppression had LLF-TB. Altered macrophage function, delayed hypersensitivity reactions, and changes in bronchial clearance mechanisms in these conditions may facilitate unusual bacillary localization and spread, thereby contributing to non-classical imaging patterns. The prevalence of lower lung field TB in Indian population has been attributed to tying their clothes around the upper abdomen resulting in impaired movement of diaphragm which leads to decrease ventilation, retarded blood circulation and lymphatic flow to lower lung fields thus making them more vulnerable to TB.<sup>12</sup>

Multi-lobar and bilateral cavitory disease, a prominent feature in our cases, is generally considered a marker of advanced disease or immunodeficiency. However, emerging literature suggests that high bacillary load, delayed presentation, or virulent mycobacterial strains may also result in extensive parenchymal destruction in immunocompetent hosts. In endemic regions, delayed health-seeking behaviour and initial empirical treatment for community-acquired pneumonia may further allow disease progression, culminating in widespread cavitation by the time of imaging.

The presence of tree-in-bud opacities and centrilobular nodules in most cases reflects active endobronchial spread of infection. While this pattern is well recognized in PTB, its coexistence with extensive cavitory consolidation in unusual locations can be misleading. In our series, these imaging features raised strong differentials of necrotizing pneumonia and fungal infection, particularly when air–fluid levels and surrounding consolidation were present. Such radiological overlap emphasizes the importance of correlating imaging findings with microbiological testing, especially in TB-endemic settings.

Another notable observation was the radiological resemblance of PTB to acute infective processes. Some patients presented with relatively short symptom duration and imaging features suggestive of cavitating pneumonia. This atypical presentation likely reflects early but aggressive disease or rapid progression in the presence of permissive host factors. The absence of classical chronic symptoms in such cases may further contribute to diagnostic delay, reinforcing the need for a high index of suspicion among clinicians and radiologists<sup>9</sup>.

The evolving radiological patterns of PTB in immunocompetent hosts may also be influenced by changing host–pathogen interactions.<sup>13</sup> Factors such as increasing prevalence of diabetes mellitus, while nutritional deficiencies, smoking, and alcohol use may modify immune responses at a subclinical level.

Additionally, genetic variability and virulence factors of *Mycobacterium tuberculosis* strains may play a role in determining disease distribution and severity. Severe or disseminated tuberculosis occurring in patients without overt immunodeficiency raises the possibility of subtle host susceptibility to mycobacterial infections. Disorders affecting the IL-12/IFN- $\gamma$  immune pathway, collectively described under Mendelian Susceptibility to Mycobacterial Disease (MSMD)<sup>14</sup>, have been increasingly recognized as an important mechanism underlying severe mycobacterial infections in otherwise healthy individuals. Genetic defects involving molecules such as IL12RB1, IFNGR1, STAT1, TYK2, and TBX21 impair the IFN- $\gamma$ –mediated immune response that is critical for macrophage activation and intracellular killing of *Mycobacterium tuberculosis*. These defects may remain clinically silent until patients develop severe, multifocal, or recurrent mycobacterial infections. Importantly, patients may present with extensive tuberculosis despite appearing immunocompetent or having only mild immunosuppression. Therefore, in cases of unusually severe or disseminated tuberculosis, clinicians should consider the possibility of underlying immune dysregulation or genetic susceptibility affecting the IL-12/IFN- $\gamma$  axis.

From a clinical and radiological standpoint, these atypical imaging manifestations pose significant diagnostic challenges. Misinterpretation as bacterial or fungal infections can lead to inappropriate antimicrobial therapy, delayed initiation of antitubercular treatment, and increased risk of disease transmission. Awareness of such emerging patterns is therefore crucial, particularly in high-burden countries, where tuberculosis remains a

common yet protean disease. Early consideration of PTB in the differential diagnosis of atypical cavitary and multi-lobar lung disease can prompt timely microbiological evaluation. Adjunct molecular diagnostics like CBNAAT can facilitate rapid identification of MTB and rifampicin resistance<sup>17</sup>, Whole Genome Sequencing (WGS) can further characterize strain-specific mutations and epidemiological linkages, offering deeper insight into pathogenesis and transmission patterns in atypical cases<sup>15</sup>.

#### IV. Conclusion

This study highlights a spectrum of emerging radiological presentations of pulmonary tuberculosis in immunocompetent individuals emphasizing the diagnostic complexities such as physician failure to consider tuberculosis as one of the possibilities when faced with such radiological appearance which may lead to diagnostic delays and delay in treatment initiation. Ultimately that will lead to increased risk of disease transmission and unfavourable outcomes. Furthermore, detailed evaluation is necessary to identify the underlying cause of extensive pulmonary tuberculosis in immunocompetent patients, including infection with a mutant or more virulent Mycobacterium tuberculosis strain or host susceptibility related to immune dysregulation and genetic variability.

#### References-

- [1]. Sharma SK, Mohan A, Gupta R, Kumar A, Gupta AK, Singhal VK, Pande JN. Clinical Presentation Of Tuberculosis In Patients With AIDS: An Indian Experience. *Indian J Chest Dis Allied Sci.* 1997 Oct-Dec;39(4):213-20. PMID: 9654817.
- [2]. Urbanowski ME, Ordonez AA, Ruiz-Bedoya CA, Jain SK, Bishai WR. Cavitary Tuberculosis: The Gateway Of Disease Transmission. *Lancet Infect Dis.* 2020 Jun;20(6):E117-E128. Doi: 10.1016/S1473-3099(20)30148-1. Epub 2020 May 5. PMID: 32482293; PMCID: PMC7357333
- [3]. Rosen Y, Cavitating Pulmonary Tuberculosis (Gross Pathology). Case Study, Radiopaedia.Org. <https://doi.org/10.53347/Rid-8633>
- [4]. World Health Organization. Global Tuberculosis Report 2024. Geneva: WHO; 2023.
- [5]. Ananthanarayan R, Paniker CKJ. Ananthanarayan And Paniker's Textbook Of Microbiology. 11th Ed. Hyderabad: Universities Press; 2023.
- [6]. Murray PR, Rosenthal KS, Pfaller MA. Medical Microbiology. 9th Ed. Philadelphia: Elsevier; 2021.
- [7]. Yoon JY, Lee IJ, Im HJ, Lee K, Lee Y, Bae SH. CT Findings In Apical Versus Basal Involvement Of Pulmonary Tuberculosis. *Diagn Interv Radiol.* 2013 Mar-Apr;19(2):85-90. Doi: 10.4261/1305-3825.DIR.6025-12.3. PMID: 23019057.
- [8]. Goto A, Komiya K, Kan T, Honjo K, Uchida S, Takikawa S, Yoshimatsu T, Fujimoto K, Johkoh T, Kadota JI. Factors Associated With Atypical Radiological Findings Of Pulmonary Tuberculosis. *Plos One.* 2019 Jul 25;14(7):E0220346. Doi: 10.1371/Journal.Pone.0220346. PMID: 31344108; PMCID: PMC6657914.
- [9]. Liu, Jian-Jun Mba; Feng, Yin-Ping Mma; Liu, Zhong-Da Mba; Guo, Jing Mma. Impact Of Delayed Diagnosis And Treatment On Tuberculosis Infection Within Families: A Case Report. *Medicine* 103(11):P E37406, March 15, 2024. | DOI: 10.1097/MD.00000000000037406
- [10]. Getnet F, Demissie M, Assefa N, Mengistie B, Worku A. Delay In Diagnosis Of Pulmonary Tuberculosis In Low-And Middle-Income Settings: Systematic Review And Meta-Analysis. *BMC Pulm Med.* 2017 Dec 13;17(1):202. Doi: 10.1186/S12890-017-0551-Y. PMID: 29237451; PMCID: PMC5729407.
- [11]. Wetscherek, M.T.A., Sadler, T.J., Lee, J.Y.J. Et Al. Active Pulmonary Tuberculosis: Something Old, Something New, Something Borrowed, Something Blue. *Insights Imaging* 13, 3 (2022). <https://doi.org/10.1186/S13244-021-01138-8>
- [12]. Sharma SK, Mohan A. Lower Lung Field Tuberculosis. In: Sharma SK, Editor. *Textbook Of Tuberculosis And Nontuberculous Mycobacterial Diseases.* 3rd Ed. New Delhi;2019. P. 155-159.
- [13]. Saqib HA, Saeed U, Awan MM, Firdous A, Islam Z Ul. Atypical Radiological Presentations Of Pulmonary Tuberculosis: An Analysis Of Associated Factors. *Pak J Chest Med [Internet].* 2023Dec.2 [Cited 2026Jan.28];29(4): 50110.
- [14]. Bustamante J, Boisson-Dupuis S, Abel L, Casanova JL. Mendelian Susceptibility To Mycobacterial Disease: Genetic, Immunological, And Clinical Features Of Inborn Errors Of IFN- $\gamma$  Immunity. *Semin Immunol.* 2014 Dec;26(6):454-70. Doi: 10.1016/J.Smim.2014.09.008. Epub 2014 Oct 26. PMID: 25453225; PMCID: PMC4357480.
- [15]. Zhang M, Lu Y, Zhu Y, Wu K, Chen S, Zhou L, Wang F, Peng Y, Li X, Pan J, Chen B, Liu Z, Wang X. Whole-Genome Sequencing To Predict Mycobacterium Tuberculosis Drug Resistance: A Retrospective Observational Study In Eastern China. *Antibiotics (Basel).* 2023 Jul 31;12(8):1257. Doi: 10.3390/Antibiotics12081257. PMID: 37627677; PMCID: PMC10451829.
- [16]. Lee KS, Song KS, Lim TH, Kim PN, Kim IY, Lee BH. Adult-Onset Pulmonary Tuberculosis: Findings On Chest Radiographs And CT Scans. *AJR Am J Roentgenol.* 1993 Apr;160(4):753-8. Doi: 10.2214/Ajr.160.4.8456658. PMID: 8456658.
- [17]. Joshi P, Singh KG, Patidar V, Gupta V. Evaluation Of Diagnostic Methods, And Rifampicin Resistance In Pulmonary Tuberculosis: A Hospital-Based Study. *Cureus.* 2024 Aug 17;16(8): E67062. Doi: 10.7759/Cureus.67062. PMID: 39286711; PMCID: PMC11403642.
- [18]. Mathur M, Badhan RK, Kumari S, Kaur N, Gupta S. Radiological Manifestations Of Pulmonary Tuberculosis - A Comparative Study Between Immunocompromised And Immunocompetent Patients. *J Clin Diagn Res.* 2017 Sep;11(9):TC06-TC09. Doi: 17.7860/JCDR/2017/28183.10535. Epub 2017 Sep 1. PMID: 29207803; PMCID: PMC5713825.