

# Custom-Made Polymethyl Methacrylate (PMMA) Cranioplasty Using A Conventional Prosthodontic Technique: A Clinical Case Report

Dr. Mitumani Biashya, Dr. Jitendra Khetan, Dr. Shiv Kumar, Dr. Sk Afreen  
Post Graduate Student, Head Of The Department, Post Graduate Student, Post Graduate Student  
Department Of Prosthodontics, Nims Dental College And Hospital, Jaipur

## Abstract

Cranioplasty is a reconstructive procedure performed to restore cranial defects caused by trauma, tumor resection, or decompressive surgery. This case report presents the rehabilitation of a cranial defect in a 32-year-old male patient using a custom-fabricated polymethyl methacrylate (PMMA) implant developed through conventional prosthodontic techniques. A precise impression was made, followed by wax pattern fabrication, flasking, and heat-cure PMMA processing. The implant was surgically placed with satisfactory esthetic and functional outcomes. This method provides a cost-effective alternative to digital workflows, particularly in resource-limited settings.

**Keywords:** Cranioplasty, PMMA, Cranial defect, Maxillofacial prosthesis, Conventional technique

Date of Submission: 18-04-2026

Date of Acceptance: 28-04-2026

## I. Introduction

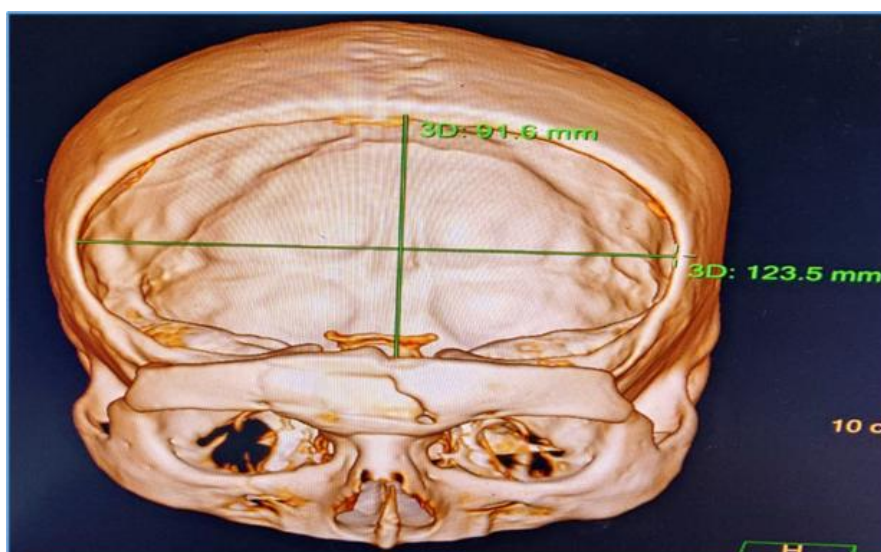
Cranioplasty is performed to repair cranial defects and restore both functional and esthetic integrity of the skull. Such defects may arise from trauma, tumor resection, or decompressive craniectomy. Reconstruction not only protects intracranial structures but also improves neurological function and patient psychology.

Various materials have been used for cranioplasty, including titanium, hydroxyapatite, and patient-specific implants fabricated via CAD/CAM. However, polymethyl methacrylate (PMMA) remains widely used due to its affordability, ease of manipulation, and acceptable biocompatibility.

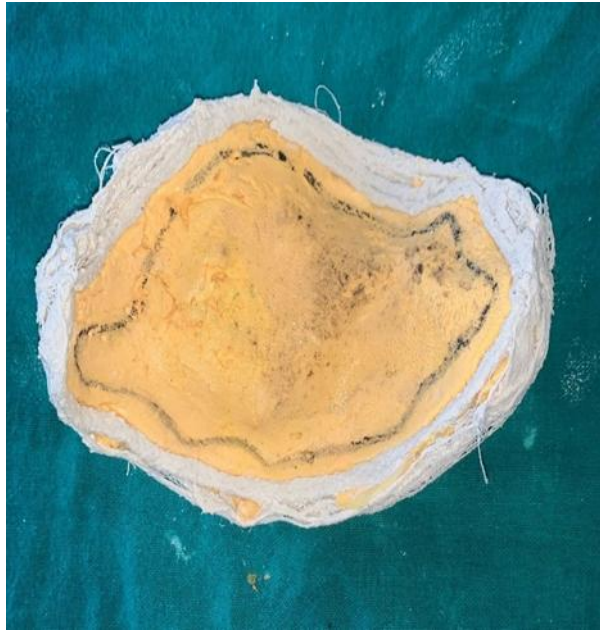In developing clinical settings, conventional prosthodontic techniques still play a crucial role in fabricating cranial prostheses. This case report highlights a cost-effective and clinically successful approach using PMMA.

## II. Case Report


A 32-year-old male patient, reported with a cranial defect following trauma. The patient's chief complaint was esthetic deformity and lack of protection over the affected region. Radiographic evaluation using CBCT confirmed a well-defined cranial defect.



## Procedure



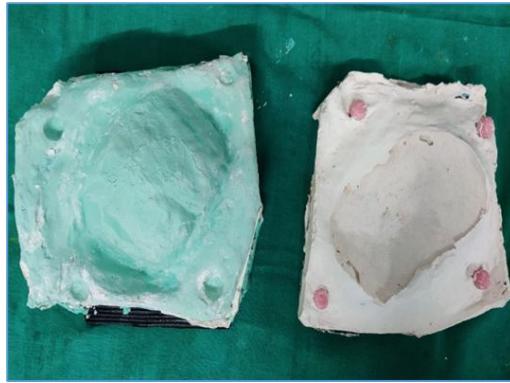
**Impression Making:** Accurate impression of the cranial defect was obtained.



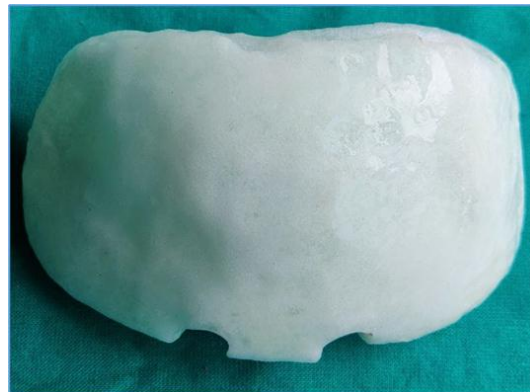**Cast Preparation:** A working cast was fabricated.



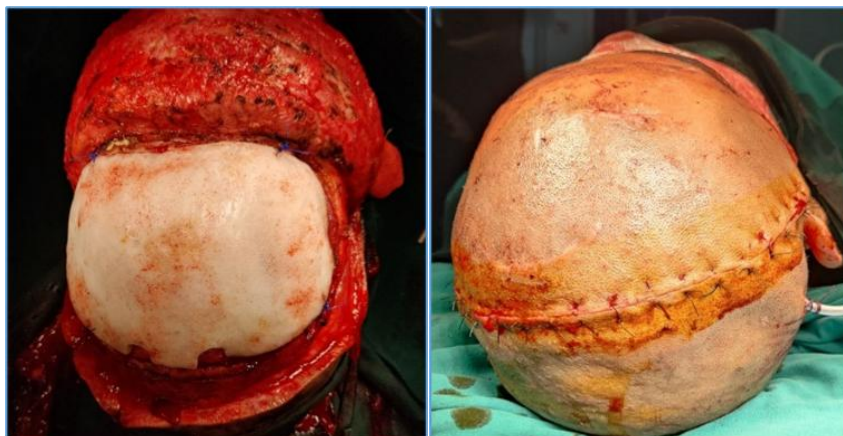**Wax Pattern:** Anatomical contour restored using wax pattern.



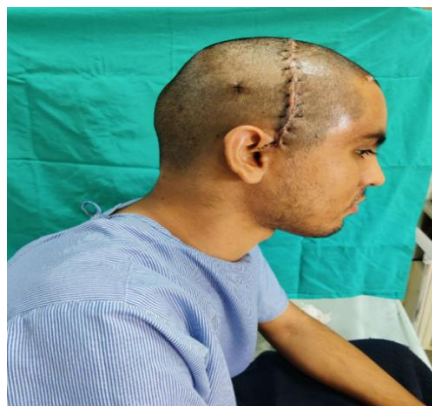**Flasking & Processing:** Heat-cure PMMA used to fabricate implant.



**Finishing & Polishing:** Smooth surface achieved to prevent irritation.



**Surgical Placement:** Implant placed and secured.



**Follow-Up:** Good healing observed at 5-day review.

### **III. Results**

The PMMA implant showed excellent adaptation and contour restoration. No post-operative complications such as infection or implant rejection were observed. The patient reported satisfaction in both esthetic and functional aspects.

### **IV. Discussion**

Cranioplasty restores cranial contour and improves neurological outcomes. PMMA remains a preferred material due to its cost-effectiveness and ease of fabrication.

Although CAD/CAM techniques provide superior precision, conventional techniques remain relevant in resource-limited settings. The present case demonstrates that with proper technique, conventional PMMA prosthesis can achieve satisfactory outcomes.

CBCT imaging played an important role in diagnosis and treatment planning, ensuring accurate defect assessment.

### **V. Conclusion**

Conventional PMMA cranioplasty is a reliable, economical, and effective method for cranial defect rehabilitation. It remains a valuable treatment option where advanced digital facilities are not available.