

# Microscope-Assisted Ultrasonic Retrieval Of A Separated Endodontic Instrument In The Buccal Canal Of A Mandibular Premolar: A Case Report.

Dr. Yamini Manoj<sup>1</sup>, Dr. Pallavi Kumbhare<sup>2</sup> Dr. Ayyagari Viresh<sup>3</sup>  
Dr. Ramya Sheshadri<sup>4</sup> Dr. R Sumukh Bharadwaj<sup>5</sup>

<sup>1</sup>Clinical Director, Manya Dental Clinics, Bengaluru <sup>2</sup>Reader, College- School of Dental Sciences, Bhopal-Indore road, Opp Pachama Oil fed Plant, Sehore, MP 4660013

<sup>3</sup>Senior Consultant Endodontist Manya Dental Clinics, Bengaluru <sup>4</sup>Senior Lecturer, Dept of conservative Dentistry and Endodontics, JSS Dental College and Hospital, JSS AHER, Mysore <sup>5</sup>Consultant Endodontist Mysuru, Karnataka

---

## Abstract

Instrument separation is a recognized procedural complication encountered during root canal treatment and may impede adequate cleaning and shaping of the root canal system. Successful management depends on several factors including canal anatomy, location of the fragment, visibility, and clinician expertise. This case report describes the endodontic management of a mandibular premolar with two roots in which a fractured endodontic instrument was encountered in the buccal canal during biomechanical preparation. Using magnification and ultrasonic techniques, the separated instrument was successfully retrieved, allowing completion of canal preparation and obturation. The case highlights the importance of careful treatment planning, conservative retrieval strategies, and the use of modern endodontic technologies in managing separated instruments.

**Keywords:** Separated instrument, fractured file retrieval, mandibular premolar, ultrasonic technique, endodontic complication.

Date of Submission: 13-04-2026

Date of Acceptance: 23-04-2026

---

## I. Introduction

Root canal therapy aims to eliminate microorganisms from the root canal system and prevent reinfection through thorough cleaning, shaping, and three-dimensional obturation of the canal space. Advances in endodontic instrumentation, particularly the introduction of nickel-titanium (NiTi) rotary systems, have significantly improved the efficiency and predictability of root canal procedures. However, procedural complications may still occur during endodontic treatment. Among these, **instrument separation** remains one of the most challenging and stressful events for clinicians.

The incidence of instrument fracture during root canal therapy has been reported to range between **0.5% and 5%**, depending on factors such as instrument design, operator skill, canal anatomy, and instrumentation technique. Fracture of endodontic instruments may occur due to **torsional stress or cyclic fatigue**, especially when files are used in curved or constricted canals. When an instrument separates within the canal, it may obstruct access to the apical portion of the canal system, potentially compromising adequate debridement and disinfection.

Management of separated instruments requires careful clinical judgment. Several treatment options have been proposed, including **removal of the fragment, bypassing the fragment, or leaving the fragment in situ** and monitoring the tooth periodically. The choice of treatment depends on factors such as the **location of the fragment, stage of canal preparation, root canal curvature, presence of periapical pathology, and potential risk of excessive dentin removal during retrieval attempts**.

With the advent of advanced technologies such as **dental operating microscopes, ultrasonic instruments, and specialized retrieval kits**, the success rate of instrument retrieval has improved considerably. Ultrasonic techniques in particular have gained popularity due to their ability to selectively remove dentin around the fragment and generate vibrations that facilitate loosening and removal of the fractured instrument.

Mandibular premolars often present with complex root canal anatomy, making endodontic procedures more challenging. While the majority of mandibular premolars typically present with two roots (mesial and distal) containing multiple canals, anatomical variations may occur that further complicate treatment.

Clinical decision-making during the management of separated endodontic instruments depends on several factors including the location of the fragment, stage of canal preparation, canal curvature, and operator experience. These factors play a crucial role in determining whether retrieval, bypassing, or retention of the fragment should be attempted. The key factors influencing treatment planning are summarized in **Table 1**.

The present case report describes the successful retrieval of a fractured endodontic instrument from the buccal canal of a mandibular premolar with two roots, followed by completion of root canal treatment.

**Table 1. Factors Influencing the Management of Separated Endodontic Instruments**

Factor	Clinical Significance	Influence on Treatment Decision
Location of fragment	Fragment may be located in coronal, middle, or apical third of canal	Coronal and middle third fragments are easier to retrieve
Canal curvature	Severe curvature increases risk of procedural complications	Retrieval attempts should be conservative to avoid perforation
Stage of canal preparation	Determines extent of canal disinfection before fracture	If canal cleaning is incomplete, retrieval or bypassing is preferred
Length of separated fragment	Longer fragments may be more difficult to retrieve	Short fragments embedded in dentin require careful ultrasonic techniques
Canal diameter	Narrow canals limit instrument retrieval	May require staging platform preparation
Visibility under magnification	Improved visualization enhances precision	Dental operating microscope increases retrieval success
Presence of periapical pathology	Indicates need for complete canal disinfection	Retrieval often recommended to allow apical instrumentation
Operator experience	Skill level influences success of retrieval	Experienced clinicians achieve higher success rates

## II. Case Report

### Patient History

A 34-year-old patient presented to the Clinic with the chief complaint of intermittent pain in the lower posterior region of the jaw for the past two weeks. The pain was described as dull and continuous, with occasional exacerbation during mastication.

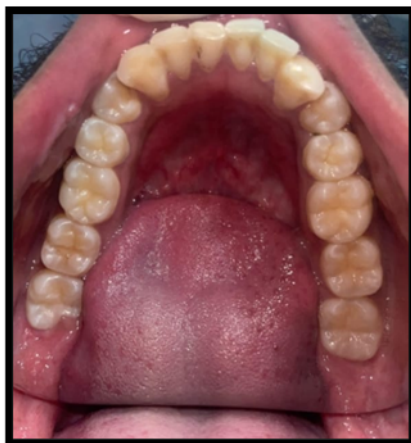The patient's medical history was non-contributory, and no systemic conditions were reported. The patient had not undergone any previous endodontic treatment on the affected tooth.

### Clinical Examination

Intraoral examination revealed a deep carious lesion involving the mandibular premolar. The tooth exhibited tenderness on vertical percussion. No swelling or sinus tract was observed in the surrounding soft tissues.

Pulp vitality tests were performed using thermal testing. The tooth exhibited a delayed response to cold stimulation, suggesting pulpal inflammation.

Based on the clinical findings, a provisional diagnosis of **symptomatic irreversible pulpitis with symptomatic apical periodontitis** was made.



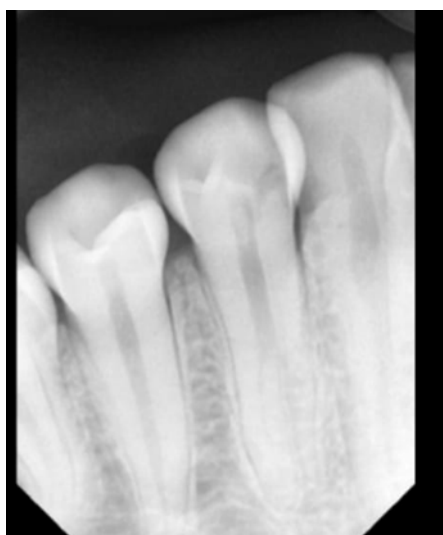**Figure 1: Intra-Oral Clinical Picture**

### **Radiographic Examination**

A preoperative intraoral periapical radiograph revealed a deep carious lesion approaching the pulp chamber. The tooth demonstrated two distinct roots consistent with the typical morphology of mandibular premolars.

Mild widening of the periodontal ligament space was observed around the root apex. No significant periapical radiolucency was noted.

Based on the clinical and radiographic findings, nonsurgical root canal treatment was planned.



**Figure 2: Intra-Oral Periapical Radiograph**

### **Endodontic Procedure**

#### **Access Preparation**

After obtaining informed consent from the patient, local anesthesia was administered and rubber dam isolation was achieved. Access cavity preparation was performed using a round diamond bur followed by an Endo-Z bur to refine the access cavity and achieve straight-line access to the canal orifices.

Upon entering the pulp chamber, necrotic pulp tissue was encountered and removed using barbed broaches. Canal orifices were carefully explored using an endodontic explorer.

Two canals were identified corresponding to the buccal and lingual aspects of the root canal system.

#### **Working Length Determination**

Initial canal scouting was performed using #10 and #15 stainless steel K-files to establish canal patency. Working length determination was carried out using an electronic apex locator and confirmed radiographically.

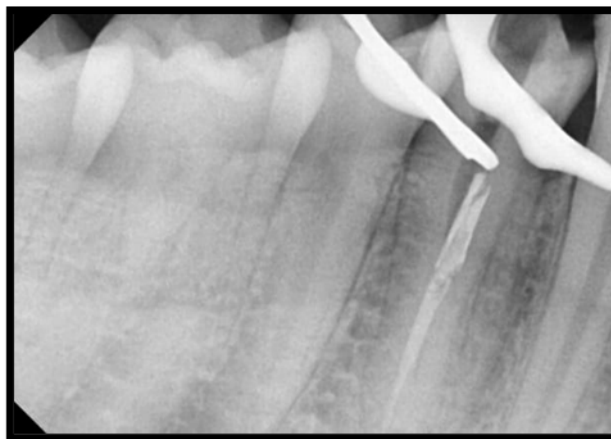
Copious irrigation with **sodium hypochlorite solution** was performed during canal exploration to facilitate disinfection and removal of debris.

### **Instrument Separation**


Biomechanical preparation was initiated using rotary nickel-titanium instruments in a crown-down technique.

During instrumentation of the **buccal canal**, resistance was encountered while negotiating the canal curvature. While attempting further instrumentation, a sudden loss of tactile sensation was noted, raising suspicion of instrument separation.

A radiographic examination confirmed the presence of a **fractured instrument fragment lodged within the buccal canal**, located in the middle third of the canal.



**Figure 3: One Canal was Obturated & the other canal shows file separation**



**Figure 4: Microscopic Image of the Access Cavity**

### **Management of the Separated Instrument**

Considering the location of the fragment and the potential to retrieve it without compromising the structural integrity of the root, an attempt was made to remove the fractured instrument.

### **Staging Platform Preparation**

A staging platform was prepared using a modified Gates-Glidden drill. This platform allowed improved visualization and facilitated access to the coronal portion of the fractured fragment.

### **Magnification**

The canal was inspected under magnification to clearly visualize the separated instrument and surrounding dentinal walls.

### **Ultrasonic Retrieval Technique**

Ultrasonic tips were carefully used to trephine dentin around the coronal aspect of the separated fragment. Controlled ultrasonic vibration was applied in a counter-clockwise motion to loosen the fragment. The ultrasonic energy generated micro-vibrations that helped dislodge the fragment from the canal wall.

After several attempts, the fractured instrument fragment became mobile and was successfully retrieved from the canal.

Various techniques have been proposed for the management of separated endodontic instruments, ranging from ultrasonic retrieval methods to bypassing techniques and the use of specialized retrieval devices. Each technique has specific advantages and limitations depending on the clinical situation. A summary of commonly used management approaches is presented in **Table 2**.

**Table 2. Techniques for Management of Separated Endodontic Instruments**

Technique	Principle	Advantages	Limitations
Ultrasonic retrieval technique	Ultrasonic vibration loosens the fragment from canal walls	Conservative dentin removal and high success rate	Risk of heat generation and dentin removal
Bypassing technique	Small hand files negotiate alongside the fragment	Allows continuation of cleaning and shaping	Technically demanding
Microtube or loop devices	Microtubes engage and pull the fragment out	Effective when fragment is visible coronally	Requires specialized equipment
Instrument removal kits	Specialized systems designed to grasp fragment	Controlled retrieval	Expensive and technique sensitive
Leaving fragment in situ	Fragment left if retrieval risks root damage	Avoids excessive dentin removal	May compromise canal disinfection

**Completion of Root Canal Treatment**

Following successful retrieval of the separated instrument, canal patency was re-established using small K-files. Biomechanical preparation was completed using rotary instrumentation while maintaining copious irrigation.

The irrigation protocol included:

- Sodium hypochlorite solution
- 17% ethylenediaminetetraacetic acid (EDTA)
- Normal saline

After thorough irrigation, the canals were dried with sterile paper points.

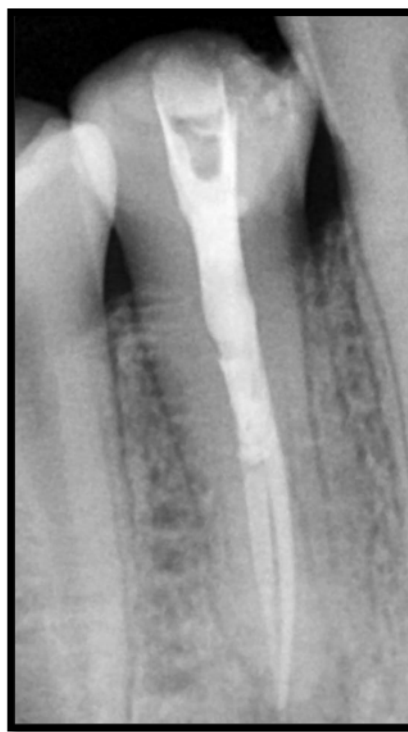Obturation was performed using gutta-percha cones with an endodontic sealer using a suitable obturation technique to achieve three-dimensional sealing of the canal system.

A postoperative radiograph confirmed satisfactory obturation of the canals.

The access cavity was subsequently restored with composite resin to ensure coronal seal.



**4(a)**



**4(b)**

**Figure 4(a): Broken Instrument Retrieved & Measured using a scale**  
**4(b): Final IOPAR showing well obturated canals**

### **III. Discussion**

Separation of endodontic instruments remains a significant procedural complication in endodontic practice. Fractured instruments can obstruct access to the apical portion of the canal and potentially compromise adequate cleaning and shaping procedures.

Several factors contribute to instrument fracture, including excessive torsional stress, cyclic fatigue, improper instrumentation techniques, and repeated use of endodontic files. Nickel-titanium instruments, although highly flexible, are particularly susceptible to cyclic fatigue when used in curved canals.

The management of separated instruments requires careful consideration of multiple factors. One of the most important determinants of successful retrieval is the **location of the fragment within the canal**. Fragments located in the **coronal or middle third** of the canal are generally easier to retrieve compared to those located in the apical third.

Another important factor is the **stage of canal preparation at the time of fracture**. If the canal has already been adequately cleaned and shaped before fracture occurs, leaving the fragment in situ may be considered. However, if the fragment obstructs access to the apical portion of the canal, retrieval or bypassing may be necessary.

The introduction of the **dental operating microscope** has significantly enhanced visualization during endodontic procedures and improved the success rate of fractured instrument retrieval.

Ultrasonic techniques are widely used for retrieval of separated instruments. The technique involves creating a staging platform and applying ultrasonic vibrations to loosen the fragment from the canal wall. Studies have demonstrated that ultrasonic retrieval techniques can achieve success rates ranging from **55% to 79%**, depending on the clinical scenario.

However, clinicians must exercise caution during retrieval attempts, as excessive dentin removal may weaken the root structure and increase the risk of perforation or vertical root fracture. Therefore, a conservative approach with minimal dentin removal is recommended.

In the present case, the fractured instrument was located in the middle third of the buccal canal, which facilitated its retrieval using ultrasonic techniques under magnification. Successful retrieval allowed completion of canal preparation and obturation, thereby achieving the biological objectives of endodontic therapy.

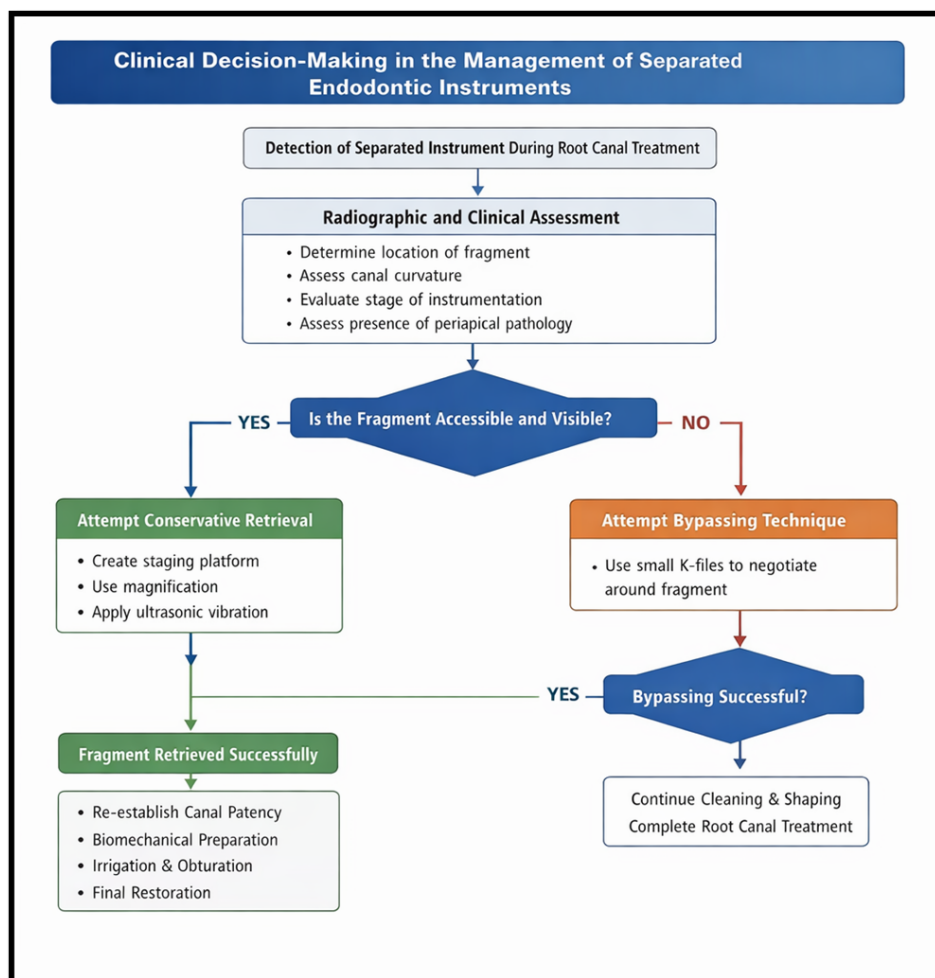


Figure 6: Clinical decision-making algorithm for the management of separated endodontic instruments during root canal therapy.

#### IV. Conclusion

Instrument separation during root canal treatment represents a challenging procedural complication that can potentially compromise treatment outcomes. Careful case assessment, proper visualization, and the use of advanced techniques such as ultrasonic retrieval under magnification can significantly improve the chances of successful management.

In the present case, the fractured instrument located in the buccal canal of a two-rooted mandibular premolar was successfully retrieved using ultrasonic techniques. This allowed completion of root canal therapy and restoration of tooth function.

Early recognition of the complication, appropriate treatment planning, and the use of modern endodontic technologies play a crucial role in achieving successful outcomes in such cases.

#### References

- [1]. Madarati AA, Watts DC, Qualtrough AJ. Factors Contributing To The Separation Of Endodontic Files. *Br Dent J.* 2008;204(5):241-245.
- [2]. Suter B, Lussi A, Sequeira P. Probability Of Removing Fractured Instruments From Root Canals. *Int Endod J.* 2005;38(2):112-123.
- [3]. McGuigan MB, Louca C, Duncan HF. Clinical Decision-Making After Endodontic Instrument Fracture. *Br Dent J.* 2013;214(8):395-400.
- [4]. Ruddle CJ. Nonsurgical Retreatment. *J Endod.* 2004;30(12):827-845.
- [5]. Shen Y, Cheung GS, Peng B, Haapasalo M. Defects In Nickel-Titanium Instruments After Clinical Use. *J Endod.* 2009;35(1):102-106.
- [6]. Hülsmann M, Schinkel I. Influence Of Several Factors On The Success Or Failure Of Removal Of Fractured Instruments From The Root Canal. *Endod Dent Traumatol.* 1999;15(6):252-258.
- [7]. Ward JR, Parashos P, Messer HH. Evaluation Of An Ultrasonic Technique To Remove Fractured Rotary Nickel-Titanium Endodontic Instruments From Root Canals. *J Endod.* 2003;29(11):756-763.
- [8]. Souter NJ, Messer HH. Complications Associated With Fractured File Removal Using An Ultrasonic Technique. *J Endod.* 2005;31(6):450-452.

- [9]. Nevares G, Cunha RS, Zuolo ML, Bueno CE. Success Rates For Removing Or Bypassing Fractured Instruments: A Prospective Clinical Study. J Endod. 2012;38(4):442-444.
- [10]. Torabinejad M, Walton RE, Fouad AF. Endodontics: Principles And Practice. 5th Ed. St Louis: Elsevier; 2015.