

# The Role of Pocus in The Diagnosis of Circulatory Shock in Critically Ill: A Takotsubo Syndrome Case Report

Leonardo Pinheiro de Pádua, MD<sup>1,2,3</sup>; Maria Elizabeth Ferreira, MD<sup>3</sup>

<sup>1.</sup> Intensive Care Unit of São Vicente de Paulo Hospital, Rio de Janeiro, Brazil;

<sup>2.</sup> Coronary Intensive Care Unit of Silvestre Adventist Hospital, Rio de Janeiro, Brazil;

<sup>3.</sup> Internal Medicine Departament of Estácio de Sá Faculty/IDOMED, Rio de Janeiro, Brazil

## Abstract

**Background:** Circulatory shock is a severe medical condition where the circulatory system fails to provide sufficient oxygen and nutrients to the body's tissues, leading to cellular damage and organ failure. Point-of-care ultrasound (POCUS) is a technological innovation that has transformed medical practice, especially in emergency and intensive care settings, where diagnostic speed and accuracy are crucial. POCUS enables quick and accurate diagnoses, comparable to invasive methods, and has a positive impact on clinical outcomes.

**Case summary:** a 55-year-old female patient, recently hospitalized for hydrocephalus of unknown origin was admitted for worsened neurological status due to obstruction of the device. Four days later she developed aspiration pneumonia and underwent tracheostomy. Few hours later, she developed refractory circulatory shock despite high doses of vasopressor drugs. a POCUS examination revealed a pattern of basal hyperkinesia and apical akinesia of the left ventricle (LV), typical of Takotsubo syndrome.

**Conclusion:** POCUS is an indispensable tool in hemodynamic assessment, with a positive impact on the quality of care and the economic efficiency of healthcare systems. It provides a rapid and accurate assessment of patients' hemodynamic status, contributing to real-time clinical decision-making and, consequently, to the improvement of clinical outcomes.

**Key words:** circulatory shock; Takotsubo syndrome; Point-of-care ultrasound.

Date of Submission: 13-06-2025

Date of Acceptance: 26-06-2025

## I. INTRODUCTION

Circulatory shock (CS) is a clinical condition characterized by inadequate oxygen perfusion to tissues, leading to difficulties in aerobic cellular respiration, which can result in multiple organ failure <sup>1</sup>. The use of point-of-care ultrasound (POCUS) can be an accessible, rapid, reliable, and easy-to-apply tool, aiding in the differentiation of CS aetiology. This tool allows for the direct assessment of cardiac function, volumetric conditions, and fluid responsiveness, which are crucial aspects in the management of hemodynamically unstable patients. The ability to monitor parameters such as cardiac function, intravascular volume, and tissue perfusion in real-time provides crucial information for managing patients with hemodynamic instability <sup>2,3</sup>.

This study describes a case of circulatory shock in an infectious context following a procedure (tracheostomy), initially interpreted as sepsis but re-evaluated as cardiogenic shock due to Takotsubo syndrome after POCUS application, highlighting the essential role of this tool in differentiating shock.

## II. CASE PRESENTATION

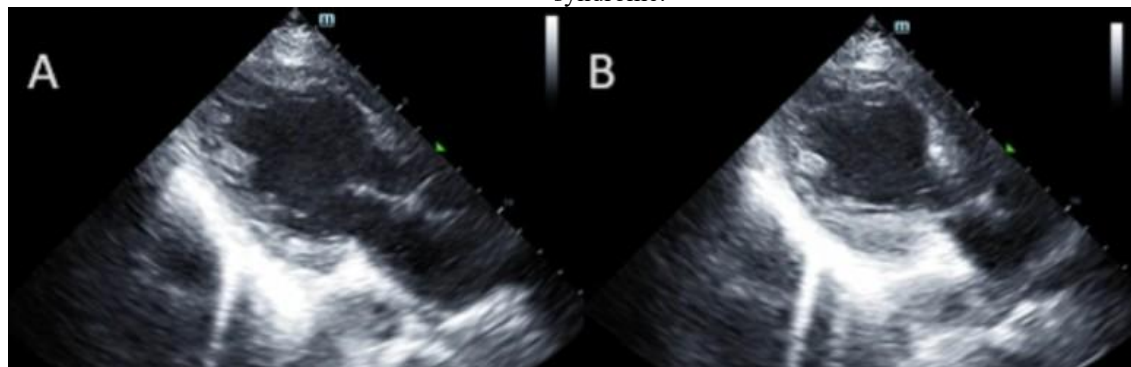
A 55-year-old female patient, recently hospitalized for hydrocephalus of unknown origin, underwent a ventriculoperitoneal shunt procedure and was later admitted for worsened neurological status due to obstruction of the device. She underwent removal of the VP shunt and insertion of an external ventricular drain, remaining on mechanical ventilation postoperatively. Four days after hospitalization, she developed aspiration pneumonia and was started on piperacillin/tazobactam.

Due to persistent neurological weakness and lack of expectation for extubating, she underwent tracheostomy without complications. However, after a few hours, she developed refractory circulatory shock despite high doses of vasopressor drugs. Sepsis was initially suspected due to the prior infection and persistent fever, leading to a change in the antimicrobial regimen to meropenem and vancomycin.

On the following day, a POCUS examination revealed a pattern of basal hyperkinesia and apical akinesia of the left ventricle (LV), typical of Takotsubo syndrome (**Figure 1**), which led to a change in diagnosis, and dobutamine was initiated. The evolution of troponin I and CK-MB levels was monitored, with a post-event peak and normalization in the following days (**Table 1**). Initially, the patient showed clinical improvement and a

reduction in the dose of vasopressors, including the discontinuation of vasopressin. However, the clinical picture complicated with worsening hemodynamic and infectious conditions, and the patient passed away on the 17th day after the procedure.

**Figure 1.** Echocardiography showing basal hyperkinesia and apical akinesia of the left ventricle - Takotsubo syndrome.



**Table 1.** The evolution of troponin I and CK-MB levels during hospitalization

	1st day*		2nd day*			4th day*	7th day*
	12h33	16h00	00h07	13h00	23h58	00h21	00h22
Troponin (ng/ml)	1028	1002	645	233	148	144	59
CK-MB (UI/L)	1002	18	19	20	13	15	21

### III. DISCUSSION

Circulatory shock is a clinical condition characterized by inadequate tissue oxygen perfusion, leading to impaired aerobic cellular respiration, which can result in multi-organ failure. It is a common pathology in hospital and ICU settings, affecting about 33% of patients, with a mortality rate of 38.3%<sup>1</sup>. From a pathophysiological standpoint, there are four etiological classes of shock, which can sometimes overlap: hypovolemic, cardiogenic, obstructive, and distributive. Identifying the etiology of shock enables a more targeted approach, improving clinical outcomes.

However, diagnosing etiology based solely on history and physical examination can be challenging. In this context, the use of POCUS (Point-of-Care Ultrasound) can serve as a complementary, accessible, quick, reliable, and easy-to-apply diagnostic tool. It aids in differentiating the etiology by examining the heart, lungs, vasculature, and intra-abdominal organs. Conditions that can be diagnosed using POCUS include pneumothorax, aortic dissection, pulmonary embolism, pericardial tamponade, heart failure, atrial myxoma, and endocarditis<sup>2</sup>.

In a meta-analysis, Yoshida et al. found sensitivity ranging from 77% (for distributive shock) to 93% (for obstructive shock), with specificity ranging from 92% (for hypovolemic shock) to 97% (for obstructive shock). The authors also noted that echocardiographic findings in distributive and hypovolemic shock can be quite similar. Furthermore, even when cardiogenic shock is suspected due to apparent cardiac dysfunction, it may be unclear whether the dysfunction is a cause or a consequence of circulatory shock. Obstructive shock demonstrated the highest sensitivity and specificities<sup>3</sup>. Other studies have also shown high specificity of POCUS in diagnosing cardiac tamponade, right ventricular failure<sup>2,3</sup>, and pneumothorax<sup>4</sup>. Post-resuscitation management guided by less extensive echocardiography has been associated with increased survival, reduced use of crystalloids, and increased use of inotropes<sup>5</sup>.

The RUSH protocol provides a bedside diagnostic algorithm for differentiating the etiology of circulatory shock using POCUS. This algorithm is based on assessing the "pump" (cardiac function), the "tank" (effective intravascular volume), and the "pipes" (arterial beds like the thoracic and abdominal aorta for dissections, and lower limb veins for deep vein thrombosis)<sup>6</sup>. In a meta-analysis, this protocol showed high sensitivity (87%) and specificity (98%) for identifying and differentiating the etiology of shock, indicating its value as a diagnostic tool for undifferentiated circulatory shock in the emergency setting<sup>7</sup>.

Cardiogenic shock is caused by severe impairment of myocardial function, resulting in decreased cardiac output, hypoperfusion of target organs, and systemic hypoxia. It is present in up to 8% of ICU patients, with a still high mortality rate of 47.4%, although this is gradually decreasing<sup>6,7</sup>.

On POCUS, cardiogenic shock may present with left ventricular (LV) systolic dysfunction and valvular diseases, as well as mechanical complications of acute myocardial infarction (AMI), such as chordae or papillary muscle rupture with acute mitral regurgitation and interventricular septal rupture. On the other hand, normal-

appearing biventricular systolic function, normal chamber sizes, absence of significant valvular pathology, and no pericardial effusion virtually exclude a cardiac cause for the shock.

To assess ventricular function, for less experienced operators and when the LV ejection fraction (LVEF) is near physiological limits, a more formal LVEF estimate using the biplane Simpson's method is recommended. Acute segmental wall motion abnormalities suggest an ischemic aetiology for cardiogenic shock, while global dysfunctions may suggest metabolic aetiologies. However, they can also be associated with ischemic causes, as severe chronic ischemic LV systolic dysfunction may sometimes present as global impairment<sup>8</sup>.

Takotsubo syndrome is a condition characterized by transient and acute left ventricular systolic dysfunction. Its pathophysiology has yet to be fully clarified; however, the most accepted theory is that of catecholamine-induced myocardial injury, although several other metabolic alterations may also be present. Typically, it occurs after a stressful event, which can even be emotional in nature, such as unexpected bereavement, conflict, or a major life event. Nevertheless, cardiac and neurological pathologies, as well as severe acute critical illnesses, can trigger syndrome<sup>9</sup>. In this case, tracheostomy in the context of infection may have been the necessary trigger to initiate the syndrome.

On echocardiography, there is the typical finding of apical to mid-ventricular segmental akinesia with basal hyperkinesia, as reported in this case. Around 20% of patients present with left ventricular outflow tract obstruction<sup>10</sup>, which was not observed in this patient. The diagnosis of this condition is based on an active search for the etiological diagnosis of circulatory shock. POCUS emerges as an important simply, easy, bedside tool in this context<sup>3,7</sup>.

#### IV. CONCLUSION

This case exemplifies how the application of POCUS allowed for the differentiation of cardiogenic shock due to Takotsubo syndrome, correcting an initial diagnosis of sepsis and altering the clinical management, although the clinical course evolved unfavorably. The use of POCUS can be a crucial differentiating factor for the etiological diagnosis and management of patients with circulatory shock, facilitating more assertive therapeutic decisions in a critical context.

#### REFERENCES

- [1]. Sakr, Y, Reinhart, K, Vincent, JL, et al. Does dopamine administration in shock influence outcome? Results of the Sepsis Occurrence in Acutely Ill Patients (SOAP) Study. *Crit Care Med* 2006; 34:589-597
- [2]. Labovitz AJ, Noble VE, Bierig M, Goldstein SA, Jones R, Kort S, et al. Focused cardiac ultrasound in the emergent setting: a consensus statement of the American Society of Echocardiography and American College of Emergency Physicians. *J Am Soc Echocardiogr* 2010;23(12):1225–30.
- [3]. Yoshida et al. Diagnostic accuracy of point-of-care ultrasound for shock: a systematic review and meta-analysis *Critical Care* (2023) 27:200.
- [4]. Ding W, Shen Y, Yang J, He X, Zhang M. Diagnosis of pneumothorax by radiography and ultrasonography: a meta-analysis. *Chest* 2011;140(4):859–66.
- [5]. Kanji et al, Limited echocardiography-guided therapy in subacute shock is associated with change in management and improved outcomes, *J Crit Care* 2014 Oct;29(5):700-5.
- [6]. Perera et al. Rapid Ultrasound in SHock examination The RUSH exam: Rapid Ultrasound in SHock in the evaluation of the critically ill, *Emerg Med Clin North Am.* 2010 Feb;28(1):29-56.
- [7]. Keikha et al. Diagnostic Accuracy of Rapid Ultrasound in Shock (RUSH) Exam; A Systematic Review and Meta-Analysis, *Bull Emerg Trauma* 2018;6(4):271-278.
- [8]. Puymirat et al. Cardiogenic shock in intensive care units: evolution of prevalence, patient profile, management and outcomes, 1997–2012, *European Journal of Heart Failure* (2017) 19, 192–200
- [9]. Muratsu A, Muroya T, Kuwagata Y. Takotsubo cardiomyopathy in the intensive care unit. *Acute Med Surg.* 2019; 6: 152–157
- [10]. Namgung J. Electrocardiographic findings in Takotsubo cardiomyopathy: ECG evolution and its difference from the ECG of acute coronary syndrome. *Clin Med Insights Cardiol* 2014; 8: 29–34.