

# Assessment of Clinical Outcomes Following Ankle Arthrodesis Among Patients Who Had Post Traumatic Arthritis and Infected Primary Ankle Injury at Specialized Hospitals in Kaduna, Kaduna State, Nigeria

Yusuf, N

Department of Surgery, Barau Dikko Teaching Hospital,  
Kaduna State University, Kaduna, Nigeria.

Correspondence Author's Address: nykogy@yahoo.com

---

## Abstract

*This study is on the assessment of clinical outcomes following ankle arthrodesis among patients who had posttraumatic osteoarthritis of the ankle and infected open primary ankle injury at specialized hospitals in Kaduna, Kaduna State, Nigeria, with the aim of determining the mechanism of injury, mode of treatment and treatment outcome. A retrospective study research design was employed for all the patients to collect data from the two specialized hospital records. The data were analyzed using Pearson and chi-square test tool. The results revealed that Motor vehicular crashes (MVCs) are the leading mechanism of injury, accounting for 66.7%, majority of patients underwent ankle arthrodesis using Charnley's compression clamp, and on the functional outcomes measured using the AOFAS Ankle-Hind foot scale, findings show that they were favorable, with over 80% of patients achieving good-to-excellent results. The paper recommended that further research with larger cohorts and randomized controlled designs is warranted to more definitively compare the long-term efficacy and safety profiles of Charnley's clamp versus trans articular screw fixation in ankle arthrodesis.*

**Keywords-** Arthrodesis, Trans articular Screws, Arthritis, Charnley's clamp, Nigeria.

---

Date of Submission: 15-06-2025

Date of Acceptance: 30-06-2025

---

## I. Introduction

Ankle arthrodesis remains the gold standard salvage procedure for the management of ankle arthritis, often resulting from acute ankle injury. These injuries vary from mild sprains to severe open fractures. The Sequelae of severe trauma to the ankle joint, is a disruption of the ankle mortise, with damage to the articular cartilage, leading to significant morbidity.<sup>1</sup>

The mechanism of injury may involve either high- or low-energy transfer, often influenced by the patient's age, bone quality, and ligamentous integrity<sup>2</sup>. Such traumatic events can result in joint incongruity, chronic pain, instability, and progressive cartilage degeneration. As the joint deteriorates, patients experience worsening pain, decreased mobility, and impaired quality of life.<sup>3</sup>

Ankle arthrodesis is a primary treatment option for managing severe post-traumatic ankle osteoarthritis. It aims to alleviate pain, stabilize the joint, and restore function by permanently fusing the tibia to the talus.

The outcomes of ankle arthrodesis in post-traumatic osteoarthritis have been examined across various centers. Obiegbo and Ikeotunye reported that 75% of patients achieved excellent outcomes. Similarly, Fuchs, *et al.* demonstrated the long-term benefits of ankle arthrodesis, noting sustained pain relief and improved function a decade after surgery.<sup>4,5</sup>

Despite favorable outcomes, complications such as non-union, infection, and hardware-related problems can occur, although these may be minimized through meticulous surgical technique and postoperative care. Additionally, altered foot biomechanics post-fusion may predispose patients to secondary arthritis in adjacent joints, such as the subtalar and mid foot joints, over time.<sup>6</sup>

The aim of the study

Is to analyze clinical outcomes following ankle arthrodesis among patients who had post-traumatic osteoarthritis of the ankle at specialized hospitals in Kaduna, Kaduna state, Nigeria, while the objectives are;

1. To analyze the early outcomes of patients who underwent ankle arthrodesis following severe traumatic injury to the ankle joint in the study.
2. To determine mechanism of injury, methods of fixation, treatment outcome and complications of treatment among patients who had posttraumatic osteoarthritis of the ankle at specialized hospital in Kaduna state, Nigeria.

## **II. Materials and Method**

**Study Area:** The study was carried out at two specialized hospitals, Barau Dikko Teaching hospital and Rapha specialist Hospital Kaduna. Barau Dikko Teaching Hospital is the only State-Owned Tertiary Health Facility that offers training to both medical students and resident doctors within the heart of the busy central city of Kaduna, the facility boasts of over 2000 staff and an annual patient turnover of over 300,000. Rapha Specialist Hospital Kaduna, is a multispecialty private hospital with a rising reputation for trauma and orthopaedic care that provides comprehensive specialist care in the resource deprived northern Nigerian city of Kaduna, it boasts of over 70 staff with an annual patient turnover of 15,000.

**Study Design and Study Population:** A retrospective study design was employed for all patients who had arthrodesis procedures for posttraumatic ankle arthritis. All patients with complete medical records were included in the study, while those with incomplete medical records and those with less than one year follow up were excluded from the study. The Period under review was between June 2014 to June 2021.

The Surgical techniques used for fixation, postoperative outcomes, complications and functional outcomes using the American Orthopaedic Foot and Ankle society (AOFAS)Ankle –Hind foot scale were all assessed.

**Data Collection:** The data was obtained from the medical records of patients managed during the period under review from the two facilities. Independent variables were the socio-demographic characteristics, mechanism of injury, duration of symptoms, surgical techniques used, type of fixation methods, and the first, third and sixth months post-operative radiological assessment results. Outcome measures of interest were rates of complication (such as non –union, infection, and hardware failure) and functional status.

**Data Analysis:** Data that were extracted from the data sources were entered into predesigned software in Statistical Packages for Social Sciences (SPSS) version 23 (IBM corp. Released 2012. IBM SPSS statistics for windows, version 19.0, Armonk, NY: IBM Corp) and analyzed. Functional outcomes measures were assessed using the American Orthopedic Foot and Ankle society (AOFAS)Ankle –Hind foot scale. Results were presented as Tables and charts. Confidence interval was calculated using open epi. Pearson and Chi-square ( $\chi^2$ ) tool were used to test association and differences between the independent variables and the main outcome of the study, with statistical significance set at p-value of 0.05.

### **Surgical Technique:**

Overall, 18 patients' records were reviewed. Of the 18 patients operated, 15 had developed post traumatic arthritis at the time of presentation, and the remaining 3 had open and infected fracture dislocation of the ankle joint.

A standard preoperative work up was followed on all the patients and consent obtained before surgery.

Procedures were primarily performed under spinal anesthesia, with few under general anesthesia based on patient preference.

Operative reports indicated that patients were placed in the supine position, and a thigh tourniquet was applied to minimize intraoperative bleeding. Surgical exposure was achieved using both medial and lateral incisions, with careful retraction of surrounding soft tissues to visualize the ankle joint. Approximately 6 cm of the distal fibula was excised in most cases. Any residual cartilage, osteophytes, or loose bodies present on the tibia and talar surfaces were debrided.

Articular surfaces were prepared using an osteotome to create fresh, bleeding bone surfaces to facilitate fusion. The foot was then positioned in neutral dorsiflexion with slight valgus alignment to ensure proper postoperative alignment and function. Internal fixation was achieved using trans articular screws in few of the cases, while external fixation with Charnley's clamp was employed in majority of the cases.

Following fixation, the wound was closed in layers. Where internal fixation was used, additional support with a cast was documented. Postoperative care involved strict non-weight-bearing immobilization on the affected side.

Patients were followed up regularly at approximately 1 month, 3 months, 6 months, and 12 months postoperatively. Radiographic assessments (anteroposterior and lateral views) were used to monitor fusion progress. In cases where external fixation with a Charnley's clamp was applied, the device was removed upon radiological evidence of callus bridging across at least two cortices.

Gradual reintroduction of weight-bearing activities and structured physical therapy was initiated once satisfactory bone healing was observed, as documented in follow-up notes.

Clinical outcomes were assessed through both radiographic evaluation and the American Orthopaedic Foot and Ankle Society (AOFAS) Ankle-Hind foot Scale. The AOFAS scale was adjusted to a maximum score of 92 (as patients post-arthrodesis are unable to score the 8 points allocated to sagittal motion). Scores were categorized according to AOFAS as follows: **Excellent:** 80–92 **Good:** 70–79 **Fair:** 60–69 **Poor:** <60.

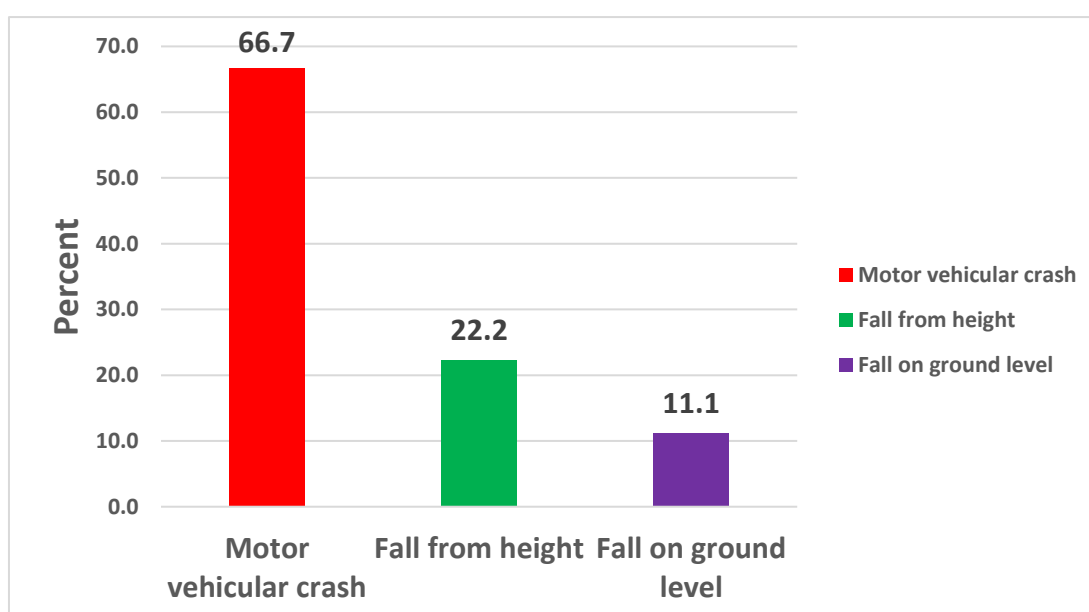
Radiographs were reviewed to assess the presence of bony fusion and the position/alignment of the fused joint. Clinical documentation was used to determine patient-reported pain and function. Other secondary complications such as non-union and pin site infections were also evaluated.

### III. Presentation of Results

**Table 1: Age and Sex Distribution of Patients (n=18)**

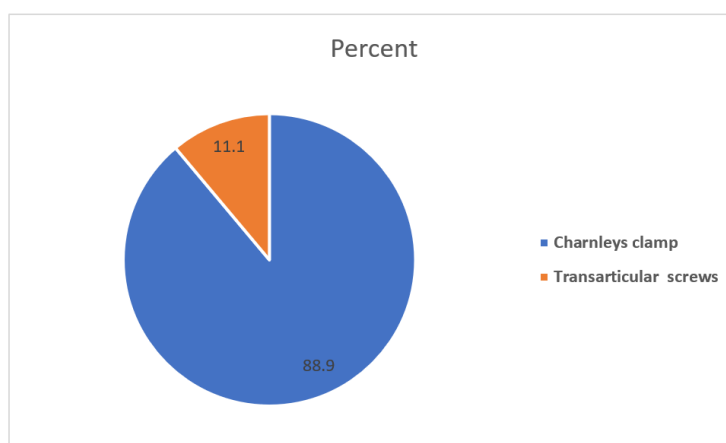
Age Group ( Years)	Frequency	Percent
≤30	2	11.1
31-40	4	22.2
41-50	6	33.3
51-60	4	22.2
≥61	3	16.7
<b>Sex</b>		
Male	10	55.6
Female	8	44.4

The age ranges from 22 to 68 years with mean age of 49.3(SD). The predominant age group was 41-50 years (33.3%), followed by 51-60 years and 31-40 years (22.2% each), 61-70 years (16.6%) and 20-30 years constitute the least (11.1%).



**Figure 1: Mechanism of Injury**

The predominant mechanism of injury was motor vehicular crash (66.7%), followed by Fall from height (22.2%), and fall on ground level (11.1%).

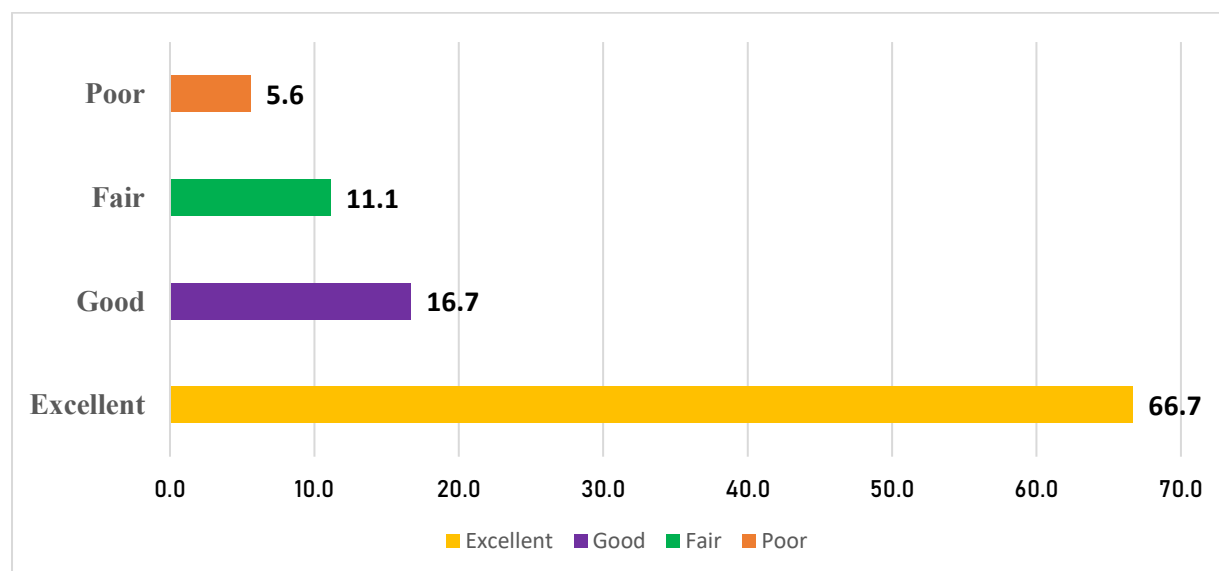


**Figure 2: Mode of Treatment**

Of the 18 surgeries carried out, majority of procedure (88.9%, n=16) had Charnleys clamp, while 11.1% (n=2) were Trans articular screws.

**Table 2: Treatment Outcome**

Methods of fixation	Union Status		Pin tract Infection Status	
	Union	Non-Union	No Infection	Infection
	Freq (%)	Freq (%)	Freq (%)	Freq (%)
Charnleys clamp (n=16)	14 (87.5)	2 (12.5)	15 (93.7)	1(6.3)
Trans articular screw (n=2)	2 (100.0)	0(0.0)	2(100.0)	0(0.0)
Total (n=18)	16 (88.9)	2(11.1)	17 (94.4)	1(5.6)
	Risk in Exposed= 87.5% CI= 62.72 – 97.76 p-value= 0.5074		Risk in Exposed= 93.75% CI= 69.69 – 100.0 p-value= 0.2032	



**Figure 3: Outcome of procedure using AOFAS Ankle –Hind foot Scale**

#### IV. Discussion

The age distribution as revealed by in this study ranged from 22 to 68 years, with a mean age of 49.3 years. The predominant age group affected was between 41 and 50 years, representing 33.3% of the cohort. This trend aligns with findings by Court-Brown et al., who reported that hind foot injuries occur most commonly in middle-aged adults due to increased exposure to trauma through occupational and vehicular activities.<sup>7</sup>

Findings shows that Motor vehicular crashes (MVCs) are the leading mechanism of injury, accounting for 66.7% of cases, followed by falls from height (22.2%) and ground-level falls (11.1%). Similar findings were observed in studies from low- and middle-income countries, where MVCs remain the predominant cause of lower limb trauma due to poor road safety and infrastructure.<sup>8,9,10</sup>

Regarding surgical interventions, research findings revealed that 88.9% of patients underwent ankle arthrodesis using Charnley's compression clamp, while 11.1% received trans articular screw fixation. Among those treated with Charnley's clamp, the union rate was 87.5%, with a 12.5% incidence of non-union and a 6.3% rate of pin tract infection. In contrast, all patients treated with trans articular screws achieved successful union without complications. Although the Charnley's clamp group exhibited high rates of non-union and pin tract infections, these differences were not statistically significant. These findings suggest that trans articular screw fixation may offer advantages in terms of union rates and complication profiles. This observation is supported by studies indicating that internal fixation methods, such as trans articular screws, can provide better compression and stability, leading to improved outcomes.<sup>10, 11, 13</sup>

Pin tract infection, a known complication of external fixation devices, remains a clinical challenge. Several studies have reported pin site infection rates ranging from 5% to 25% in Charnley's technique, with risks amplified in diabetic or immunocompromised patients.<sup>14,15</sup>

On the functional outcomes measured using the AOFAS Ankle-Hind foot scale, findings show that they were favorable, with over 80% of patients achieving good-to-excellent results. Previous studies evaluating outcomes after ankle arthrodesis also report high patient satisfaction and improved function, particularly when union is achieved without complications.<sup>4,10</sup> Globally, arthroscopic ankle arthrodesis has demonstrated high fusion

rates and favorable functional outcomes. A long-term follow-up study reported a 94.6% fusion rate and significant improvements in AOFAS scores.<sup>16,17</sup>

## V. Conclusion:

Ankle arthrodesis is a primary treatment option for managing severe post-traumatic ankle osteoarthritis. It aims to alleviate pain, stabilize the joint, and restore function by permanently fusing the tibia to the talus. This study concludes that ankle arthrodesis remains a reliable and effective surgical treatment for patients with post-traumatic ankle arthrodesis particularly when conservative management has failed. The procedure consistently provides significant pain relief and patients satisfaction with few complications. However, long time follow up is recommended to monitor for the development of adjacent joint arthritis.

## VI. Recommendations

While the small sample size of this study limits the generalizability of the findings, the results underscore the importance of selecting appropriate fixation methods to optimize patient outcomes. Further research with larger cohorts and randomized controlled designs is warranted to more definitively compare the long-term efficacy and safety profiles of Charnley's clamp versus trans articular screw fixation in ankle arthrodesis.

## References:

- [1]. Haddad SL, Coetzee JC, Estok R, Fahrbach K, Banel D, Nalysnyk L. Intermediate and long-term outcomes of total ankle arthroplasty and ankle arthrodesis: a systematic review of the literature. *J Bone Joint Surg Am.* 2007;89(9):1899-905.
- [2]. Barg A, Henninger HB, Hintermann B. Risk factors for nonunion in ankle arthrodesis. *J Bone Joint Surg Am.* 2011;93(4):325-32.
- [3]. Saltzman CL, Salamon ML, Blanchard GM, Huff T, Hayes A, Hayes P, et al. Epidemiology of ankle arthritis: report of a consecutive series of 639 patients from a tertiary orthopedic center, *Iowa Orthop J.* 2005;25:44-6.
- [4]. Obiegbu HO, Ikeotunye C. Clinical and radiological outcomes of ankle arthrodesis in post-traumatic arthritis: a tertiary center experience. *Niger J Orthop Trauma.* 2023;22(1):35-41.
- [5]. Fuchs S, Sandmann C, Skwara A, Chylarecki C. Quality of life 20 years after arthrodesis of the ankle. *J Bone Joint Surg Br.* 2003;85(7):994-8.
- [6]. Plaass C, Knupp M, Barg A, Hintermann B. Ankle arthrodesis. *J Am Acad Orthop Surg.* 2012;20(7):457-69.
- [7]. Court-Brown CM, Caesar B. Epidemiology of adult fractures: A review. *Injury.* 2006;37(8):691-697
- [8]. Mock C, Gloyd S, Adjei S, Acheampong F, Gish O. Economic consequences of injury and resulting family coping strategies in Ghana. *Accid Anal Prev.* 2003;35(1):81-90.
- [9]. Solagberu BA, Ofoegbu CP, Abdur-Rahman LO, Adekanye AO, Udoffa US, Taiwo J. Motorcycle injuries in a developing country and the vulnerability of riders, passengers, and pedestrians. *Inj Prev.* 2006;12(4):266-268.
- [10]. Nwachukwu AC. Ankle arthrodesis in Awka, Nigeria: Indications and treatment with unlocked retrograde intramedullary nailing and other methods. *Int J Sci Res Arch.* 2024;11(2):1640-6
- [11]. Easley ME, Montijo HE, Wilson JB, Fitch RD, Nunley JA. Revision Tibiotalar Arthrodesis. *Foot Ankle Int.* 2008;29(3):199-206.
- [12]. Gougoulas N, Khanna A, Maffulli N. History and evolution in ankle arthrodesis. *Br Med Bull.* 2009;89(1):111-123.
- [13]. Schuberth JM, Cheung Y, Talusan PG. Comparison of internal and external fixation for primary ankle arthrodesis: a systematic review. *J Foot Ankle Surg.* 2015;54(3):471-475.
- [14]. Myerson MS, Quill GE. Ankle arthrodesis. A comparison of an arthroscopic and an open method of treatment. *Clin Orthop Relat Res.* 1991;(268):84-95.
- [15]. Inman VT. *The Joints of the Ankle.* Baltimore: Williams & Wilkins; 1976.
- [16]. Lee MS, Millward DM. Arthroscopic Ankle Arthrodesis: A 2-15 Year Follow-up Study. *Arthroscopy.* 2018;34(3):775-80.
- [17]. Anderson K, Seneviratne A, Izzo A, Torgerson WR, Holmes G, Cottrell B. Return to Play After Shoulder Stabilization Procedures: A Criteria-Based Testing Continuum to Guide Rehabilitation and Inform Return-to-Play Decision Making. *Arthroscopy.* 2016 Jul;32(7):1403