

Giant Retro-Uterine Presacral Schwannoma: A Case Report

Kamel Hail (1), Kafia Belhocine (1), Lounas Benghanem (1),
Abderrazek Bouamra (1), Zakia Batoul Benlahreche (2), Rachid Nemmar (1),
Mohamed Derradji (1)

University Hospital Center Of Algiers. Hospital Of Algiers Mustapha. University Of Algiers 1
Hospital Of Laghouat. University Amar Telidji Of Laghouat

Abstract:

Schwannoma, typically a benign tumor originating from Schwann cells, can develop in various parts of the body, including the retroperitoneal and pelvic regions. In this observation, we report the case of a giant retro-uterine presacral schwannoma in a 25-year-old woman, revealed by atypical pelvic pain and diagnosed through CT and MRI imaging. The patient underwent surgery via both abdominal and Kraske's posterior approaches, and histology confirmed the diagnosis as benign. Schwannomas in this location are highly rare. They can progress to a malignant form, especially in patients with neurofibromatosis. Imaging examinations, particularly MRI, are more accurate in distinguishing benign from malignant tumors. Biopsy is often discouraged due to potential risks. Histological classifications and S100 protein expression aid in diagnosis. Surgery is the primary treatment, but the approach varies based on location and associated risks. Kraske's posterior trans-sacral approach can be an alternative. Although recurrences are rare, postoperative CT surveillance is recommended due to delayed diagnosis and uncertainty regarding tumor malignancy.

Keywords: Schwannoma, presacral, neurogenic tumor

Date of Submission: 25-12-2023

Date of Acceptance: 05-01-2024

I. Introduction:

Schwannoma is typically a benign nerve-origin tumor arising from Schwann cells. It can occur as a solitary or multiple entity, particularly in cases of Von Recklinghausen's disease, and can affect various body parts. Its presence in the retroperitoneal region is highly rare, even more so in the pelvic area. Due to the rarity of this specific location, we report the case of a giant retro-uterine presacral schwannoma in a young woman.

II. Patient and Observation:

We present the case of a 25-year-old patient with no significant medical history, consulting for atypical pelvic pain and a sensation of heaviness persisting for over a year, all occurring in an afebrile context. Pelvic ultrasound revealed a giant retro-uterine pelvic tissue mass, heterogeneous and hypoechoic, not associated with any specific organ (Figure 1). Abdomino-pelvic CT indicated a retro-uterine presacral pelvic mass, roughly oval-shaped, well-defined, measuring 132x116 mm, with heterogeneous density, displacing the uterus and bladder anteriorly and showing sacral bone lysis, suggestive of a neurogenic tumor (Figure 2). MRI revealed a lobulated and circumscribed pelvic tissue mass measuring 110x126 mm, seemingly originating through the sacral foramina, suggestive of a schwannoma (Figure 3). The patient underwent surgery via both abdominal and Kraske's posterior approaches, allowing en bloc resection of the tumor and sacrum. Postoperative recovery was uneventful. Histological and immunohistochemical examination (positive staining with anti-PS100 antibody) concluded a schwannoma with necrotic areas and no signs of malignancy.

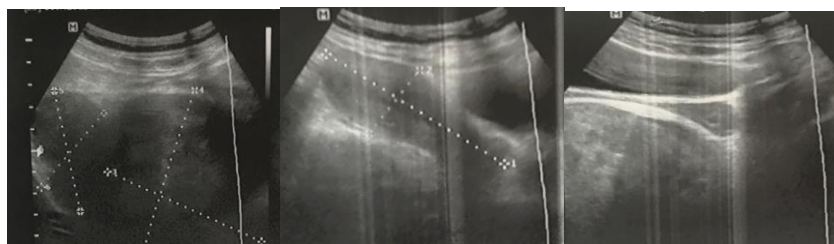

Figure 1 : Pelvic ultrasound

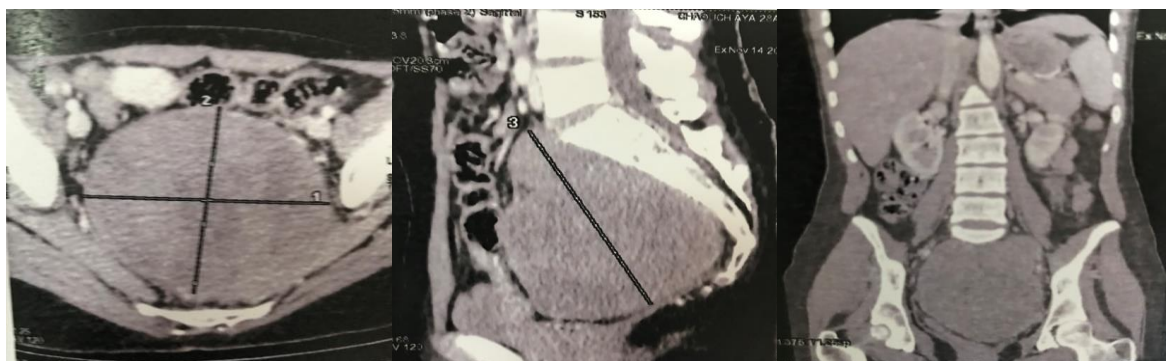

Figure 2 : Abdomino-pelvic CT

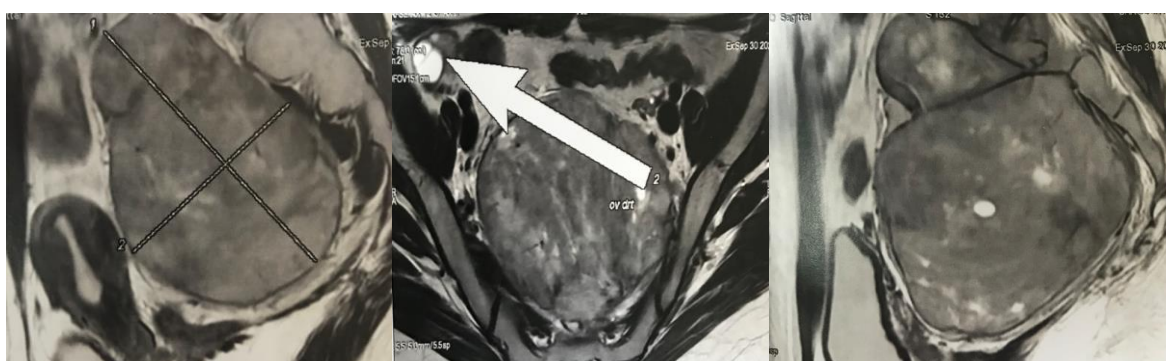


Figure 3 : Magnetic resonance imaging

III. Discussion :

The schwannoma is typically a benign tumor that forms from Schwann cells, which produce the myelin sheath surrounding peripheral nerves. These tumors usually develop from these cells and can affect peripheral nerves in different parts of the body. While they are often non-cancerous, their growth can exert pressure on nerves and surrounding tissues. The benign or malignant nature of a schwannoma often depends on the context in which it develops, its evolution over time, and its size. In some cases, a schwannoma initially benign can evolve into a malignant form. This transformation commonly occurs in individuals with neurofibromatosis type II. In this context, a pre-existing benign schwannoma can undergo malignant transformation, becoming more aggressive and potentially cancerous. At other times, it may appear spontaneously without any pre-existing tumor or lesion. These malignant types of schwannomas can develop without known antecedents and may exhibit more aggressive growth and behavior (1). It was in 1910 that VEROCAY described the first case of nerve sheath tumor, naming it a neurinoma. In 1932, Masson demonstrated that such tumors originate from Schwann cells and proposed the term Schwannoma (2). In the pelvis, it is considered particularly rare. Documented studies primarily consist of individual case reports, emphasizing its rarity in this specific anatomical zone where it can potentially affect any organ in the pelvic cavity (3). At this level, three variants of schwannomas are identified: retroperitoneal or presacral schwannoma, intra-osseous, and spinal. In this anatomical space, other tumors, whether benign or malignant, can also develop, forming the differential diagnoses of pelvic schwannoma. These include vestigial cysts (such as dermoids, epidermoids), vestigial congenital tumors (like teratomas or hamartomas), as well as non-vestigial conditions (such as chordomas, meningoceles), nerve-origin tumors (like neurofibroma, ependymoma, ganglioneuroma), bone-origin tumors (such as Ewing's tumor, chondrosarcoma, osteosarcoma, myeloma), and soft tissue sarcomas (including malignant schwannomas). These various pathological conditions may present similar characteristics to presacral schwannoma and should be considered in establishing the differential diagnosis (4). Abdomino-pelvic CT is the primary examination for diagnosing nonspecific symptoms. It helps identify anomalies in the presacral space but does not always distinguish the benign or malignant nature of these tumors. Nevertheless, it remains a useful examination to assess the tumor's relationships with neighboring organs, differentiate solid and liquid lesions, uni or multilocular, and determine any locoregional invasion (5). Magnetic resonance imaging (MRI) performs better than CT in characterizing presacral tumors. It may sometimes distinguish between benign and malignant tumors, with 81% sensitivity and 83% specificity for preoperative diagnosis of malignancy (6). MRI provides insights into the lesion's histological type, which can influence surgical approach decisions. It offers detailed information on the tumor's solid or liquid structure and composition, its location concerning the spine, and its anatomical relationships with surrounding structures (7). It may also highlight specific semiological features, such as the presence of a capsule around the tumor. Typically, retrorectal

schwannoma is well circumscribed and encapsulated, observable through this imaging modality. Most authors discourage percutaneous biopsy for schwannomas for several reasons. Firstly, this procedure may pose challenges in interpreting results, and in the case of a malignant tumor, there is a potential risk of neoplasm dissemination during the biopsy. Additionally, the presence of peritumoral hypervascularization further complicates this procedure, often making percutaneous biopsy less advisable (8,9). Therefore, a definitive diagnosis of benignity or malignancy can only be made through histology obtained from the surgical specimen. There are two primary histological classifications of schwannomas: Antoni A type, characterized by bipolar cells organized in interlacing palisades in a structured manner, and the Antoni B type, where pleomorphic cells are arranged in a looser fibrillary framework. Positive expression of the S100 protein in an immunohistochemical study is an indicator of neuritic differentiation, guiding the diagnosis towards a schwannoma (10, 11). The primary treatment for schwannomas remains surgery, especially through an abdominal approach for tumors located higher in the pelvic region, above the third sacral piece. However, this approach is recommended under the condition of no sacral invasion, nerve involvement, or pelvic organ compromise. Complete tumor resection is generally performed, often by enucleation without capsule rupture. Associated risks may include incomplete excision in some cases, challenges in accessing very low tumors, and the risk of hypogastric plexus nerve injuries. Despite these risks, this method allows meticulous exploration of the pelvis, identification of iliac vessels, and ureters (12,13). The trans-sacral posterior approach of Kraske is a feasible alternative. Its main feature is to allow the en bloc extraction of the coccyx and sacral parts with the tumor in case of bone invasion, contributing to prevent recurrences. Furthermore, this approach offers better surgical exposure, allowing precise dissection of the sacral nerves, reducing the risk of urogenital complications compared to the abdominal approach (14,15).

IV. Conclusion :

The presacral schwannoma generally carries a favorable prognosis in its benign form. Its clinical diagnosis is often delayed due to atypical symptoms, and imaging results are frequently inconclusive regarding malignancy. The preferred treatment remains complete surgical removal. Although recurrences are rare post-surgery, post-operative surveillance via computed tomography is recommended.

Conflicts of interest : The authors declare no conflicts of interest.

References:

- [1]. Fletcher CDM, Unni KK, Mertens F. Pathology And Genetics Of Tumours Of Soft Tissue And Bone. World Health Organization. Lyon: IARC Press; 2002.
- [2]. Masson P. Tumors Of The Peripheral Nerves. *Am. J. Cancer*, 1932,8, 367-380.
- [3]. Khatig R A, Khalil A M, Saba M I, Aswad N K, Mroueh A M. A Pelvic Retroperitoneal Schwannoma Presenting As An Adnexal Mass. *Gyn Oncol*. 1994 ; 53 (2) : 242-244.
- [4]. A. Makni A,* , F. Fetiricha , M. Mbarek B, Z. Ben Saftaa. Le Schwannome Pré-Sacré. *Journal De Chirurgie Viscérale* (2012) 149, 480—481
- [5]. M. Barraqué* , A. Filippello , A. Brek , S. Baccot , J. Porcheron , G. Barabino. Surgical Management Of Retro-Rectal Tumors In The Adult. *Journal De Chirurgie Viscérale* (2019) 156, 256—26.
- [6]. Yang B-L, Gu Y-F, Shao W-J, Et Al. Retrorectal Tumors In Adults: Magnetic Resonance Imaging Findings. *World J Gastroenterol* 2010;16:5822—9.
- [7]. Hosseini-Nik H, Hosseinzadeh K, Bhayana R, Jhaveri KS. MR Imaging Of The Retrorectal — Presacral Tumors: An Algorithmic Approach. *Abdom Imaging* 2015;40:2630—44.
- [8]. Krid M, Elleuch A, Gouchem M, Hbacha M, Ben Sorba N, Tlili Graies K, Mosbah A T, Jeddi M. Schwannome Rétropéritonéal, Démarche Diagnostique Et Thérapeutique. *Acta Urol Belg*. 1997 Mar ; 65 (1) : 69-72.
- [9]. Weber O, Zerbib M, Peyret C, Deslignères S, Debré B. Schwannome Bénin Rétropéritonéal. *J Urol*. 1993 ; 99 (4) : 189- 191.
- [10]. WEISS S.W., LANGLOSS J.M., ENZIGER F.M. : Value Of S-100 Protein In The Diagnosis Of Soft Tissue Tumors With Particular Reference To Benign And Malignant Schwann Cell Tumors. *Lab. Invest*, 1983, 49, 299-308.
- [11]. YAMAMOTO K., MIYAGAWA J., KATSURA H. : Retroperitoneal Cellular Schwannoma : Report Of A Case Diagnosed By The Presence Of S-100 Protein. *JPN J. Med.*, 1991, 30, 487-490.
- [12]. Sagar AJ, Tan WS, Codd R, Fong SS, Sagar PM. Surgical Strategies In The Management Of Recurrent Retrorectal Tumours. *Tech Coloproctol* 2014;18:1023—7.
- [13]. Guillem P, Ernst O, Herjean M, Triboulet J. Tumeurs Rétro Rectales : Intérêt De La Voie Abdominale Isolée. *Ann Chir* 2001;126:138—42.
- [14]. Lorentziadis M, Poulantzas I. Kraske's Posterior Approach To The Mid Rectum: Does It Still Have A Place In The Surgeon's Armamentarium? *Ann Gastroenterol* 2010;23:302—6.
- [15]. Westbrook KC, Lang NP, Broadwater JR, Thompson BW. Posterior Surgical Ap