

A Randomized Clinical Trial to Compare Inverted ILM Flap Technique and Standard Macular Hole Surgery In Terms Of Anatomical and Functional Outcomes

Dr Yogendra Singh Dhaked¹ Dr Kamlesh Khilnani² Dr Vishal Agarwal³
Dr Varun Saini⁴

¹(Resident, Department of Ophthalmology, SMS medical college Jaipur, Rajasthan)

²(Senior professor, Department of Ophthalmology, SMS medical college Jaipur, Rajasthan)

³(Associate professor, Department of Ophthalmology, SMS medical college Jaipur, Rajasthan)

⁴(Resident, Department of Ophthalmology, SMS medical college Jaipur ,Rajasthan)

Abstract

Aim : The aim of this is to evaluate the effects on vitrectomy with inverted internal limiting membrane (ILM) flap technique versus vitrectomy with complete ILM peeling (standard macular hole surgery) for large macular hole diameter greater than 400 micron.

Design : A prospective, randomized clinical trial

Participants : patients with macular holes larger than 400 micron were included. In group A, 75 eyes of 75 patients underwent standard macular hole surgery with complete ILM peeling. In group B, 75 eyes of 75 patients underwent inverted ILM flap technique.

Method: In the inverted ILM flap technique a remnant attached to the margins of the macular hole was left in place. This ILM remnant was then inverted upside down to cover the macular hole. Spectral domain optical coherence tomography and clinical examination were performed before surgery and postoperatively at 1, 3, 6 and 12 months.

Main outcome measures: visual acuity and macular hole closure.

Results : preoperative mean visual acuity was 0.0944 (Range 0.0630-0.1680) in group A and 0.0926 (range 0.0720-0.1430) in group B. macular hole closure was observed 93.33% of patients in group A, and in 100% of patients in group B, flat open was observed in 33.33% of patients in group A. 13.33% of patients in group B. Mean postoperative visual acuity 12 months after surgery was 0.19 in group A and 0.31 in group B, (p value 0.001 each) which was statistically significant

Conclusions : in the inverted ILM flap techniques prevents the postoperative flat open appearance of a macular hole and improves both the functional and anatomical outcomes of vitrectomy for macular holes with a diameter greater than 400 micron. Spectral optical coherence tomography after vitrectomy with the inverted ILM flap technique suggests improved foveal anatomy compared with the standard surgery.

Date of Submission: 29-01-2022

Date of Acceptance: 10-02-2022

I. Introduction

In skilled hands, pars plana vitrectomy with vital dye-assisted ILM peeling is a very safe and reliable procedure, which induces the closure of macular holes in up to 98% of cases^{1,2}. This surgical maneuver is so successful that its indications have expanded to the surgical treatment of other macular diseases³. However, in challenging cases like large macular holes (minimum diameter > 400 µm) and macular holes associated with high myopia, the surgical outcomes are usually poorer regardless of whether the ILM has been removed or not during surgery (closure rate ≈ 40%). Large macular holes that have ended up achieving closure after conventional ILM peeling are more prone to display a V-shape, W-shape or a flat/open (flat macular hole with bare retinal pigment epithelium) closure type pattern⁴. Despite being considered as favorable closure patterns, they are usually associated with persistent loss of photoreceptors layer (irregularities), retinal pigment epithelium defects, and foveal tissue loss that correlates with poorer visual recovery and frequent need of reoperations. In order to improve the closure rate in complicated cases of macular hole while minimizing the possible anatomical consequences of an extensive ILM peeling; Michalewska et al. introduced a novel surgical technique based on the principle of ILM manipulation and conservation: the inverted flap technique. Michalewska et al. proposed an approach in where the ILM is not completely removed, but a small

remnant is left on the margin of the macular hole to cover it. They found that their technique achieved better anatomical and visual outcomes compared to conventional ILM peeling⁵.

therefore, the aim of this study is to evaluate the effects on vitrectomy with inverted internal limiting membrane (ILM) flap technique versus vitrectomy with ILM peeling (standard macular hole surgery) for large macular hole (diameter greater than 400 micron).

II. Materials & Methods

STUDY LOCATION- Upgraded Department of Ophthalmology, SMS Medical College & Hospital, Jaipur

STUDY DESIGN- Randomized clinical trial **STUDY UNIVERSE-** All patients attending eye OPD of SMS

hospital Jaipur **STUDY POPULATION-** All patient of macular hole attending eye OPD of SMS hospital

Jaipur **SAMPLE SIZE-** Sample size was calculated 62 subjects for each of two groups at alpha error 0.05 and power 80% assuming flat hole roof with bare retinal pigment epithelial (flat open) in group1 19% and 2% in group2 (as per seed article). Assuming 20% non response the sample size is inflated to 75 subjects in each group; which is also enough to estimate all other study variables.

STUDY PERIOD- Data collection from Dec 2016 to Dec 2018 or till the sample size is completed, whichever is earlier. It will take another 2 months for processing and analysis of data.

SAMPLING TECHNIQUE – patients with macular hole diameter > 400 micron were randomized into 2 groups by sealed envelope method. Group A comprised 75 eyes of 75 patients in whom standard pars plana Vitrectomy with ILM peeling was performed and group B comprised 75 eyes of 75 patients in whom the inverted ILM flap technique was attempted.

ELIGIBILITY CRITERIA: The nature and aim of the study was explained to the patients and a written consent for participation was taken from each patient before the surgery. **Inclusion criteria** – Patient with idiopathic full thickness macular hole (FTMH) with a minimum diameter larger than 400 micron.

Exclusion criteria – History of high myopia, History of ocular trauma, History of retinal detachment or retinal surgery, Diabetic retinopathy, Presence of co-existing ocular pathologies affecting vision and patients refusing randomization were excluded from this study.

all patients underwent history – Ocular, Medical and Family, Preoperative parameters were recorded:- Best corrected visual acuity (BCVA)- was converted into decimal unit for statistical analysis, Intraocular pressure (IOP), Slit lamp biomicroscopy. Indirect ophthalmoscopy. Optical coherence tomography (OCT) TOPCON. The diagnosis of full thickness macular hole was made by indirect ophthalmoscopy and OCT. Duration of macular hole was recorded. From each OCT study we manually assessed them by using the caliper software tool, the minimum diameter (minimal extent of the hole), the base diameter (diameter at the level of retinal pigment epithelium), height (the maximal distance between the retinal pigment epithelium and the vitreoretinal interface), Stages and posterior vitreous detachment (PVD) status and the macular hole index (MHI, ratio of the macular hole height to its base diameter) was calculated. MHI, a predictor factor for macular hole closure.

SURGICAL TECHNIQUE

All the surgeries in both the groups were performed by a single surgeon. In both groups phacoemulsification with implantation of intraocular lens was followed by 23-G core vitrectomy and induction posterior vitreous detachment. After core vitrectomy (23 Gauge), posterior vitreous detachment (PVD) induction was performed. Triamcinolone acetonide was used to facilitate visualization of the vitreous and posterior hyaloids. Then brilliant blue G dye was slowly injected toward the ILM around the macular hole instead of directly toward it to minimize retinal toxicity, and let the ILM be stained for about 30s. after that the ILM along with any epiretinal membrane if present was grasped and peeled off in a circumferential pattern for about 2 disc diameter around the macular hole using ILM peeling forceps. During the circumferential peeling the ILM was completely removed in standard macular hole surgery but in inverted ILM flap technique a peripheral piece of the ILM was trimmed with vitreous cutter and leaving only the innermost narrow circle of ILM attached to the macular border by a pedicel. Then this remnant of ILM was gently turned upside down toward the bottom of the macular hole and was carefully flattened to make sure it was properly positioned rather than packed irregularly. The perfusion pressure was set at the lowest level that the vitrectomy machine allowed when covering the macular hole with the inverted ILM flap and during the air fluid exchange to avoid the flimsy flap being washed away. At the end of surgery 20% SF6 gas tamponade was applied to secure the position of the inverted flap and the postoperative face down position was instructed for at least 1 week.

Postoperative care :Hospital stays for 2 days with face down positioning after surgery

Patients were kept on IV antibiotic, analgesic and topical antibiotic, antiglaucoma and steroid medication

FOLLOW UP -was done at week 1 and 1, 3, 6 and 12 months. Following parameters were recorded:-IOP, Best corrected visual acuity using snellens acuity chart converted into decimal unit for statistical analysis, Indirect Ophthalmoscopy. The main outcomes measured on OCT were:

Anatomical closure was defined as the flattening of the hole with resolution of subretinal cuff of fluid.

- **Anatomical success** was defined in types of macular hole closure:-
 - Type-1 Anatomical closure i.e. flattening of macular hole with resolution of subretinal cuff of fluid and neurosensory retina(NSR) completely covering the fovea.
 - Type-2 Anatomical closure i.e. when the whole rim of the NSR around the macular hole was attached to the underlying retinal pigment epithelium(RPE) but NSR was absent above the fovea.
- **Pattern** of hole closure- 1. U shape, 2. V shape, 3. Irregular and 4. Flat open with bare retinal pigment epithelium.
- **Closure failure.**

At the end of study, data was collected, documented and analysis was done statistically.

Statistical analysis-Qualitative data were summarized in the form of proportion. Quantitative data were summarized in the form of mean and standard deviation. The difference in pre and postoperative mean value was analyzed using paired t test. The level of significance for all statistical analysis was kept 95%.

III. Results

A randomized clinical trial done on all patients of macular hole attending eye OPD of SMS hospital Jaipur from Dec 2016 to Dec 2018. 150 eligible cases of macular hole randomly assigned in standard macular hole surgery (ILMP group A) and Inverted ILM flap technique (IFT group B) using sealed envelope method. After surgery macular hole closure was recorded using optical coherence tomography on 1 month, 3months, 6 months and 12 months. At the end of study, data was collected, documented and analysis was done statistically.

Table 1: Age distribution of the two groups

Age (yrs)	Group A	Group B	P-value
Mean	64.17	65.39	0.1739 NS
SD	5.953	4.868	
Range	55 yrs-72 yrs	54 yrs-71 yrs	

The above table depicts that the mean age of patients was 64.17 years (standard deviation 5.953 years) in group A & 65.39 years (standard deviation 4.868 years) in group B, but statistical non significant (P=0.1739 NS).

Table 2: Duration of macular hole (months) of the two groups

Duration of macular hole (months)	Group A	Group B	P-value
Mean	21.21	22.57	0.2462 NS
SD	6.789	7.500	
Range	8.00-39.00	10.00-38.00	

The above table depicts that the mean duration of macular hole was 21.21 months in group A & 22.57 months in group B, but statistical non significant (P=0.2462 NS).

Table 3: Minimum macular hole diameter of the two groups

Minimum diameter (µm)	Group A	Group B	P-value
Mean	749.7 µm	765.6 µm	0.4585 NS
SD	167.6	77.01	
Range	476 µm -1065 µm	598.0 µm -923 µm	

The above table depicts that the minimum mean diameter of macular hole was 749.7 µm (standard deviation 167.6µm) in group A & 765.6 µm (standard deviation 77.01µm) in group B, but statistical non significant (P=0.4585 NS).

Table 4: Maximum macular hole diameter of the two groups

Maximum diameter (µm)	Group A	Group B	P-value
Mean	1560 µm	1579 µm	0.7614 NS
SD	417.5	358.0	
Range	893 µm -2500 µm	943.0 µm -2376 µm	

The above table depicts that the maximum mean diameter of macular hole was 1560 µm (standard deviation 417.5µm) in group A & 1579 µm (standard deviation 358µm) in group B, but statistical non significant (P=0.7614 NS).

Table 5: macular hole index of the two groups

macular hole index	Group A	Group B	P-value
Mean	0.2769	0.2835	0.3425 NS
SD	0.07598	0.07433	
Range	0.1600-0.4700	0.1900-0.5100	

The above table depicts that the mean value of macular hole index was 0.2769 in group A & 0.2835 in group B, but statistical non significant (P=0.3425 NS).

Table 6: Pre-operative visual acuity of the two groups

Pre-operative visual acuity	Group A	Group B	P-value
Mean	0.09449	0.09264	0.6204 NS
SD	0.02835	0.01532	
Range	0.0630-0.1680	0.0720-0.1430	

Our study showed that the mean value of pre-operative visual acuity was 0.09449 (standard deviation 0.02835) in group A & 0.09264 (standard deviation 0.01532) in group B, but statistical non significant (P=0.6204 NS).

Table 7: Post-operative visual acuity of the two groups Post-operative visual acuity	Group A	Group B	P-value
At 1 month	0.12±0.07	0.20±0.11	0.001**
At 3 months	0.14±0.10	0.22±0.13	0.001**
At 6 months	0.18±0.11	0.30±0.12	0.001**
At 12 months	0.19±0.12	0.31±0.14	0.001**

Our study showed that the mean value of post-operative visual acuity in 1, 3, 6 & 12 months was 0.12±0.07, 0.14±0.10, 0.18±0.11 & 0.19±0.12 respectively in group A and 0.20±0.11, 0.22±0.13, 0.30±0.12 & 0.31±0.14 respectively in group B, which was statistical significant (P=0.001** each) during follow up period.

Table 8: Anatomical & functional outcome in both groups

Outcome	Group A	Group B	P-value
Anatomical Closure	93.33% (70/75)	100% (75/75)	0.0583
Anatomical success			
Type 1	45	65	0.0005***
Type 2	25	10	
No closure	5	0	

Our study showed anatomical closure (flattening of cuff and resolution of subretinal fluid of hole) of 93.33% in group A and 100% in group B (P value=0.0583 which was not statistically significant). Our study showed anatomical success (flattening of cuff with filling of neurosensory defect) of 60% (45/75) in group A and 86.66% (65/75) in group B. Our study showed type-1 closure of 60% (45 out of 75) in group A and 86.66% (65 out of 75) in group B. Our study showed type-2/flat open closure rate of 33.33% (25 out of 75) in group A and 13.33% (10 out of 75) in IFT group B. The anatomical success type I closure was most commonly seen in both groups (45/75 in group A & 65/75 in group B) and type II closure was most commonly seen in group A (25/75) as compared to group B (10/75). Out of 75 patients, 5 patients had closure failure in group A.

Table 9: Pattern of closure in both groups

Pattern of closure	Group A (ILM peeling group)	Group B (IFT group)
U-shape	5	35
V-shape	10	22
Irregular shape	30	8
Flat open	25	10
Total	75	75

Our study showed U-shape closure 46.66% in IFT group B and 6.66% in group A. Our study showed V-shape closure 29.3% in IFT group B and 13.33% in group A. Our study showed W-shape /irregular closure 40% in group A and 10.66% in IFT group B. Our study showed type-2/flat open closure rate of 33.33% (25 out of 75) in group A and 13.33% (10 out of 75) in IFT group B. Our study showed the mean post-operative BCVA in group A at 3 months, 6 months and 12 months was 0.14, 0.18

and 0.19 respectively, and in group B at 3 months, 6 months and 12 months was 0.22, 0.30 and 0.31 respectively which was statistically significant during follow-up. Our study showed U-shaped and type-1 closure were associated with favorable visual outcome.

IV. Discussion

We set out to evaluate the anatomical closure rate and visual outcome in patients undergoing vitrectomy for macular hole (diameter >400 micron) with either inverted ILM flap technique or standard macular hole surgery.

Removal of the ILM in cases of macular hole have been widely adopted and evolved since its original description in 1991 and it is considered by the majority of retinal specialist as the standard of care⁶. Internal limiting membrane peeling relieves the tractional forces responsible for causing the hole by removing the template upon which glial tissue proliferates as well as triggers reparative gliosis by injuring the muller cells, which constitute the framework of ILM.. However, large neural defects are difficult to bridge by the glial tissue. Hence, large macular holes have a propensity to remain open or close in a Type 2 manner.

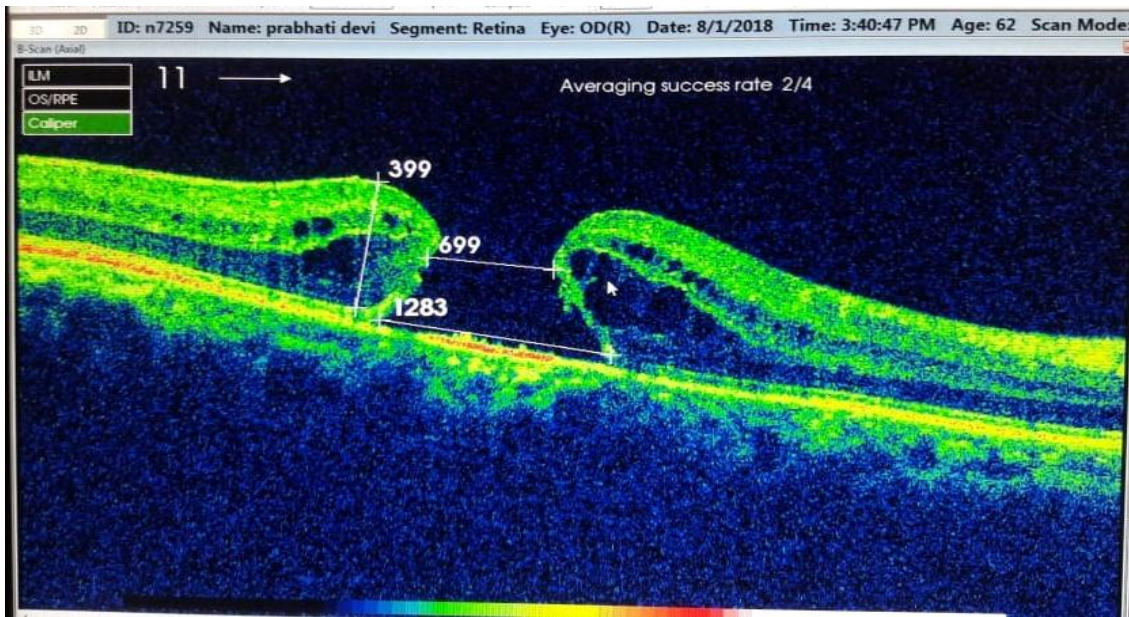
The most recommended treatment for macular hole today is pars plana vitrectomy with ILM peeling with gas injection and one week postoperative face down position. Gas tamponade plays an important role in hole closure during macular hole surgery, as the gas provides a scaffold for glial proliferation, and its surface tension may exclude vitreous fluid from the subretinal space. This is a randomized clinical trial done on all patients of macular hole attending eye OPD of SMS hospital Jaipur from Dec 2016 to Dec 2018. 150 eligible cases (75 in each group) of macular hole randomly assigned in Inverted ILM flap technique (Group B) and standard macular hole surgery (Group A) group using sealed envelope method.

Our study showed anatomical closure (flattening of cuff and resolution of subretinal fluid of hole) of 93.33% in group A and 100% in group B (P value=.0583 which was not significant).Our study shows anatomical success (flattening of cuff with filling of neurosensory defect) of 60% in group A and 86.666% in group B. There have been few studies comparing the anatomical and functional outcome of IFT with conventional ILMP in case of large macular hole. There are few studies which suggest that IFT is better than conventional ILMP. Michalewska et al. performed a prospective trial including 50 eyes in each group. They found that anatomical closure rate was 98% in IFT group and 88% in ILMP group⁷. Type 1 anatomical closure rates in the IFT and ILMP groups were 96 and 69% respectively. In Our study we found type-1 closure rate 60% (45 out of 75) in group A and 86.66%(65 out of 75) in group B.

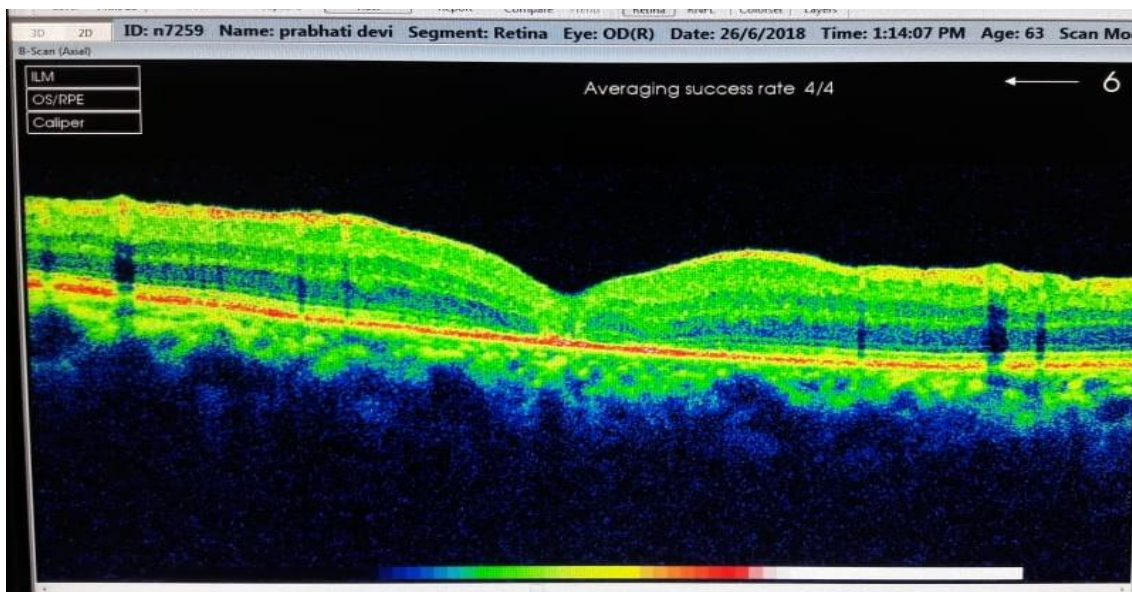
The post-operative BCVA was significantly higher in the IFT group. Similarly, Manasa et al¹⁰. did a prospective trial including 50 eyes in each group (mean MD around 650 μ m in each group)⁸. They found that Type 1 closure rate was significantly better in the IFT group (62.8%) than ILMP (33.3%). Also, the functional outcome was significantly better in the IFT group. Rizzo et al⁸. (mean MD not mentioned) in their retrospective analysis of 620 eyes, showed that both the anatomical and the functional outcome was statistically better in the IFT group (95.6%) than the ILMP group(78.6%). Narayanan et al⁹. in their retrospective analysis of 36 eyes (mean MD around 550 μ m in each group), found no statistically significant difference in either the anatomical or the functional outcome between the two groups. Their results showed 88.9% closure rate in IFT group and 77.8% in ILM peeling group. Velez-Montoya et al¹¹ performed a prospective trial with 12 patients in each group (mean MD around 600 μ m in each group)¹². They found that there was no statistically significant difference in the anatomical success rates between the two groups (91.7% in both groups). However, the functional outcome was significantly better in the IFT group. The anatomical success rates in our study were similar to that reported in the literature. Our study showed that IFT showed a trend towards better anatomical and visual outcome in case of large macular holes. our results show that holes with MD > 850 μ m have a higher probability of closing with inverted ILM flap.

Michalewska et al. recognized that the development of a U-shape closure type was the most prevalent after the inverted-flap technique and had better functional prognosis (2 lines improvement) than other types of closure. In Our study we found U-shape closure 46.66% in IFT group B and 6.66% in group A(ILMP group). The postoperative structural analysis of the fovea demonstrated that patients with U-shape closure had smaller photoreceptor layer defects (linear defect, volumetric defect, inner segment/outer segment junction abnormalities) and normal retinal thickness at the end of the follow-up. Our study showed V-shape closure 29.3% in IFT group B and 13.33% in group A. Our study showed W-shape/irregular closure 40% in group A and 10.66% in IFT group B. Our study showed type-2/flat open closure rate of 33.33%(25 out of 75) in group A and 13.33%(10 out of 75) in IFT group B. In our study we found U-shaped and type-1 closure were associated with favorable visual outcome. Our study shows the mean post-operative BCVA in group A at 3 months, 6 months and 12 months was 0.14, 0.18 and 0.19 respectively, and in group B at 3 months, 6 months and 12 months was 0.22, 0.30 and 0.31 respectively which was statistically significant during follow-up.

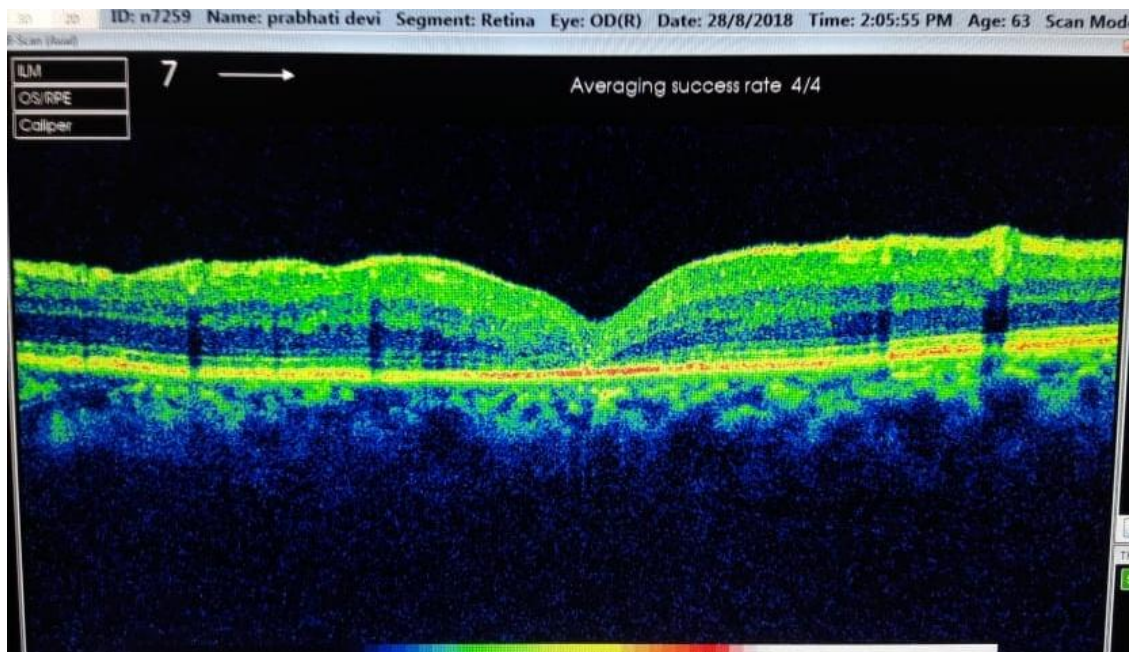
In our study, a trend towards a higher anatomical success rate and a better functional outcome was noticed with inverted ILM flap technique. This trend can be explained by the fact that the IFT provides a smooth and gap-free natural scaffold for the migration of glial cells and photoreceptors towards the fovea.



This can be explained by following results shown in our study:-
62 yrs old woman with a FTMH. OCT demonstrate minimum macular hole diameter 699 micron and maximum macular hole diameter 1283 micron. Pre operative visual acuity was 0.05. Underwent inverted ILM flap technique for macular hole repair in may 2018.



Macular hole 1 month after the inverted ILM flap technique. The retinal tissue with similar reflectivity to the outer plexiform layer can be seen in fovea. Visual acuity was 0.1 and type-1 closure (U-shape) was seen.



3 months after the inverted ILM flap technique. Appearance of 2 hyper reflective lines (external limiting membrane and IS/OS junction). . In this case regeneration of retinal tissue starting from the external limiting membrane, followed by restoration of the ellipsoid zone layer was observed during the following months. best corrected visual acuity was 0.25 noted.

V. Conclusion

Inverted ILM flap technique prevents the postoperative flat open appearance of a macular hole and improves both the functional and anatomic outcomes of vitrectomy for macular holes with a diameter greater than 400 micron .spectral optical coherence tomography after vitrectomy with the inverted ILM flap technique suggests improved foveal anatomy compared with the standard surgery.

References

- [1]. Ito Y, Terasaki H, Takahashi A, Yamakoshi T, Kondo M, Nakamura M. Dissociated optic nerve fiber layer appearance after internal limiting membrane peeling for idiopathic macular holes. *Ophthalmology*. 2005;112(8):1415–20.
- [2]. Michalewska Z, Michalewski J, Nawrocki J. Continuous changes in macular morphology after macular hole closure visualized with spectral optical coherence tomography. *Graefes Arch ClinExpOphthalmol*. 2010;248(9):1249–55.
- [3]. Wong D, Steel DH. Free ILM patch transplantation for recalcitrant macular holes; should we save some internal limiting membrane for later? *Graefes Arch ClinExpOphthalmol*. 2016;254(11):2093–
- [4]. Michalewska Z, Michalewski J, Nawrocki J. Continuous changes in macular morphology after macular hole closure visualized with spectral optical coherence tomography. *Graefes Arch ClinExpOphthalmol*. 2010;248(9):1249–55.
- [5]. Michalewska Z, Michalewska J, Adelman RA, Nawrocki. inverted internal limiting membrane technique for large macular hole; *Ophthalmology*. 2010 oct, 117(10):2018-25. doi 10.1016/j.ophtha.2010.02.011. Epub 2010 jun 11. PMID: 20541263
- [6]. Kelly NE, Wendel RT. Vitreous surgery for idiopathic macular holes. Results of a pilot study. *Arch Ophthalmol* 1991;109:654-9.
- [7]. Z. Michalewska, J. Michalewski, R. A. Adelman, and J. Nawrocki, “Inverted internal limiting membrane flap technique for large macular holes,” *Ophthalmology*, vol. 117, no. 10, pp. 2018–2025, 2010.
- [8]. Rizzo S, Tartaro R, Barca F, Caporossi T, Bacherini D, Giansanti F. Internal limiting membrane peeling versus inverted flap technique for treatment of full-thickness macular holes: a comparative study in a large series of patients. *Retina*. 2018; 38 Suppl 1:S73–S78
- [9]. Narayanan R, Singh SR, Taylor S, Berrocal MH, Chhablani J, Tyagi M, et al. Surgical outcomes after inverted internal limiting membrane flap versus conventional peeling for very large macular holes. *Retina*. 2019; 39:1465–1469. <https://doi.org/10.1097/IAE.0000000000002186> PMID: 29689027
- [10]. Manasa S, Kakkar P, Kumar A, Chandra P, Kumar V, Ravani R. Comparative evaluation of standard ILM peel with inverted ILM flap technique in large macular holes: a prospective, randomized study. *ophthalmic Surg Lasers Imaging Retina*. 2018; 49:236–240. <https://doi.org/10.3928/23258160-20180329-04> PMID: 29664979
- [11]. Velez-Montoya R, Ramirez-Estudillo JA, Sjöholm-Gomez de Liano C, Bejar-Cornejo F, Sanchez-Ramos J, Guerrero-Naranjo JL, et al. Inverted ILM flap, free ILM flap and conventional ILM peeling for large macular holes. *Int J Retina Vitreous*. 2018; 4:8. <https://doi.org/10.1186/s40942-018-0111-5> PMID: 29479478