

Prosthetic Rehabilitation of Custom Made Ocular Prosthesis In Ocular Defect: A Case Report

(1)Dr. Mrugnayani P. Patel. (2) Dr.Neerjamahajan (3) Dr. Rajesh Sethuraman

(MDS, Department of Prosthodontics, crown and bridge)

Professor and Guide of the department of Prosthodontics, crown and bridge)

(Additional dean and HOD of the department of Prosthodontics, crown and bridge)

Corresponding Author: (1)Dr. Mrugnayani P. Patel.

Abstract: The psychological impact of losing an eye is grave and the prosthetic rehabilitation of such a patient boosts their self-esteem and establishes a sense of normalcy. This clinical report describes the rehabilitation of the left eye using custom modified stock eye shell to produce esthetically pleasing results.

Keywords: custom made prosthesis, ocular prosthesis, indirect impression, irreversible hydrocolloids, conformers.

Date of Submission: 27-02-2020

Date of Acceptance: 13-03-2020

I. Introduction

Eyes are a vital organ both for vision and facial expression. Trauma, malignancy and congenital deformities result in facial defects. Cosmetic surgery restores most of the tissue that may have been lost but it may not completely mimic the appearance of the organ to create the illusion of normal or near normal¹.

The ocular prosthesis serves as a simulated ancillary for the enucleated eye. A well-adapted prosthesis improves the esthetic quotient of the patient along with improving the confidence level and psychological state. Ocular prosthesis maybe stock made or custom made. Economic and time restraints advocate the use of stock ocular prosthesis but these may not be an exact match or may not fit well. Custom made prosthesis are better adapted, accurately matches the iris position and movement of the adjacent natural eye^{2,3}.

II. Case Report

45 year old male patient reported to the Department of Prosthodontics and Crown & Bridge complaining of ill-fitting artificial left eye shown in the Figure No. 1.



Figure 1: Ill-Fitting Artificial Left Eye

The patient had a history of trauma to the left eye at the age of 40 and due to post-surgical complication, the eye ball was enucleated. A stock prosthesis was given to the patient by some shopkeeper. When the patient was examined on reporting to our institution, it was found that the tissue bed was irritated. Therefore, he was advised to discontinue wearing the old stock prosthesis. Further evaluation revealed adequate depth between the fornixes, which could be utilized to provide better retention for custom made ocular prosthesis⁴.

Impression procedure of the ocular prosthesis

First, petroleum jelly was applied to the eyebrows for the easy removal for the impression material when its sets⁵.

In 1940 U.S Armed Forces developed an indirect impression technique for fabrication of ocular prosthesis in which an irreversible hydrocolloid impression is placed within and over the socket shown in Figure No: 2(A to F). However, the injection pressure and the weight of the impression material can distort the contours of the socket itself. Allen and Webster modified the indirect technique by using an impression tray in the shape of the ocular prosthesis shown in Figure No: 3(A & B). When placed within the socket, the impression tray supports the eyelid and provides the required contour. An easily flowable, watery mix of the impression material was made and through the hollow stem of the impression tray, it was injected into the socket shown in Figure No: 2(D). The overfilling of the socket would be reversed as the tissues force the extra material out via the perforations in the tray and the hollow stem. A two-piece mold of dental stone was poured around the impression. The portion near the stem should be thin for convenience of removing the impression tray once the stone sets. A wax conformer was fabricated using this mold⁶.



Fig 2 (a)



Fig 2 (b)



Fig 2 (c)

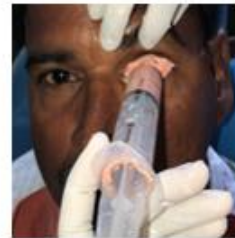

Fig 2 (d)

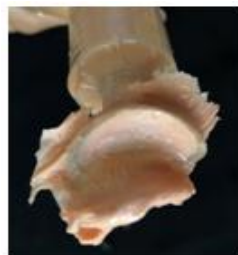

Fig 2 (e)



Fig 2 (f)

Figure No.2 (a): Mold made by clear PMMA acrylic resin

Figure No.2 (b): Mold attached to the hub of the syringe

Figure No.2 (c): Socket of the patient's affected eye

Figure No.2 (d): Injecting irreversible hydrocolloid impression material in the socket

Figure No.2 (e & f): Impression with irreversible hydrocolloids Alginate Material



Figure No.3 (a): Impression poured in dental stone

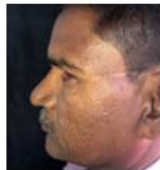

Figure No.3 (b): Two piece mold of dental stone

Wax conformer:

Once the mold was removed from the impression, it was coated with a separating medium. Molten modeling wax (company name) was then poured into the mold through the stem of the impression tray. Once the wax cooled and got set, the wax conformer was removed after opening the mold. The surface of the wax conformer was made smooth by removing any irregularities and sharp ridges on the surface. It was then evaluated in the socket and the contours were compared with that of the natural eye shown in figure no: 4. after this the insertion of heat cured PMMA clear acrylic resin conformer was done figure no: 5. Then gave the trial conformer to the patient for 15 days. Any modifications needed were done which improved the cosmetic results of the final prosthesis⁶.

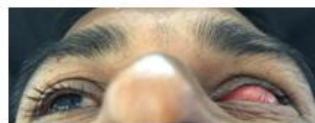Figure No.4: Wax conformer trial in the socket



Lateral view



Frontal view



Contouring trial of wax Conformer



Heat cured PMMA clear acrylic resin conformer



Figure no: 5 Insertion of trial conformer

Replication in scleral-colored acrylic resin

The entire wax pattern was invested with improved stone in a two-piece flask given in figure no: 6. When the improved stone got set, flask was opened and packed with scleral colored methyl methacrylate resin and cured in water at 212° F for 1 hour. Later the prosthesis was removed from the flask and its true scleral color was compared to the natural eye. The sclera of the prosthesis was tinted to compare favorably with the sclera of the natural eye. Veining was added by acrylic color painting to the prosthesis. The heat of a light bulb was applied to dry the added colors⁶.



Figure No.6(a): Wax pattern is invested with stone in a two-piece flask

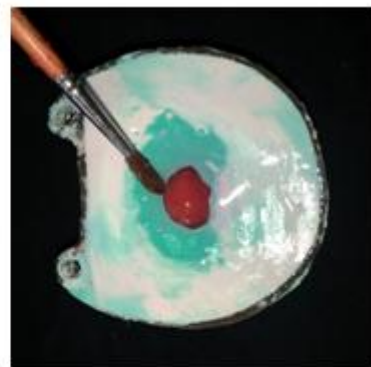


Figure No.6(b): cold mold seal (Separating media) application on wax pattern



Figure No.6(c): After de waxing procedure

Replication in scleral-colored acrylic resin and Placement of stock iris on the sclera

When the soft tissue contours provided by the sclera was satisfactory, a dot with the help of marker was placed in the location for the center of the pupil given in figure no: 7 (A & B). Then the shade and proper diameter of an artificial iris was selected with comparison of the natural eye (figure no: 8). A space was made in the sclera for the placement of the completed iris-cornea piece shown in figure no: 9(a). The pupil of which will coincide with the location of the black ink dot with the help of wax. Then the centering of iris has been placed in to the socket and compare with the patient's natural eye as a trial basis before final curing cycle. The position of the iris is noted in its direction of gaze and its medial, lateral, superior, and inferior relationships. The margins of the upper and lower lids should cross the iris of the prosthesis at the same level as the natural eye shown in Figure no: 9 (c)⁶.

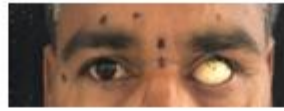

Figure No.7 (a): Black dot marked in the center of sclera for placement of iris

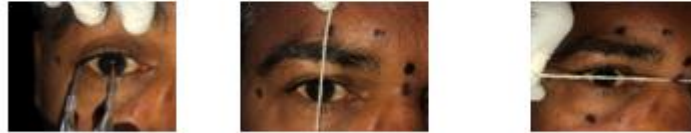

Figure No.7 (b): Measurements for centering of the pupil

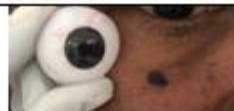

Figure No.8: selection of the artificial iris diameter and shade with the natural eye

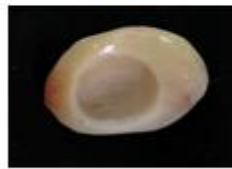

Figure No.9 (a): Space is made in the sclera for the placement of the iris-cornea piece



Figure No.9 (b): Iris-cornea piece



Figure No.9 (c): Try in of the sclera and placement of iris-cornea piece with the natural eye

Addition of the transparent acrylic resin and completion of the prosthesis

A tinfoil was adapted to the flask and with the help of clear methyl methacrylate resin it will be packed. Clear methyl methacrylate resin is placed in the top half of the flask, covered with a piece of wet cellophane, and trial packed. The use of the cellophane during trial packing will prevent the migration of the added colors by the expelled excess acrylic resin. When the excess clear acrylic resin has been eliminated, the final closure is made without any cellophane. Then the flask will be placed in water at 212° F and polymerize for 1 hour. After curing flask will be removed from water and let it cool down. The polymerized ocular prosthesis is finished and carefully polished (figure no: 10 a). After this the final prosthesis is placed in the socket and the orbicular muscle must be allowed to relax for at least 10 minutes to permit critical evaluation (figure no: 10 b to d). Once everything will be checked and satisfactory the prosthesis will be delivered to the patient and instructions will be given⁶.

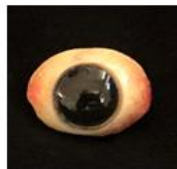

Figure No.10 (a): The polished polymerized ocular prosthesis



Figure No.10 (b): Final insertion of polymerized ocular prosthesis

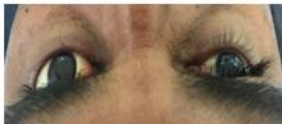

Figure No.10 (c): contouring of the final ocular prosthesis



Figure No.10 (d): Final ocular

Patient instructions

The patient was instructed to wear the prosthesis day and night. It need only to be removed from the socket and washed with mild soap once every 1 or 2 weeks. More frequent cleansing would be indicated if particularly dusty conditions were present. The soft tissues of the socket can be rinsed with an ophthalmic irrigation solution (Dacroiose, Smith, Miller and Patch, San & Juan, Puerto Rico) and examined for irritation or infection during regular follow ups. Daily ocular hygiene consists of using the ophthalmic irrigation solution as eye drops to clean the anterior surface of the prosthesis. The normal production of mucus and lacrimal fluid would keep the posterior of the socket and clean. To improve the movement of the eyelids and the sparkle and sheen of the prosthesis, the use of an ophthalmic silicone liquid has also proved quite beneficial. Several drops daily will improve the lifelike quality desired. If the surface of the prosthesis gets scratched or pitted, then it should be repolished immediately as well as periodically during routine follow-up examinations⁶.

III. Discussion And Summary

So many techniques have been used in fitting and fabricating ocular prosthesis. Empirically fitting a stock eye, modification of stock eye by making an impression of the ocular defect⁷, and fabrication of a custom ocular prosthesis⁸ are the most commonly used techniques. The fabrication of a custom acrylic eye provides more esthetic and precise results because an impression establishes the defect contours and the iris and the sclera are custom fabricated⁹. Prosthetic rehabilitation of post evisceration patient has been explained in this case report.

A properly fitted and acceptable custom ocular prosthesis has the following characteristics:

- Retains the shape of the defect socket.
- Prevents collapse or loss of shape of the lids.
- Provide proper muscular action of the lids.
- Prevents accumulation of fluid in the cavity.
- Maintains palpebral opening similar to the natural eye.
- Mimics the colorations and proportions of the natural eye.
- Has a gaze similar to the natural eye¹⁰.

Using prefabricated iris button makes procedure less technique sensitive and faster with more predictable results. The main disadvantage of this technique compare to traditional iris button painting technique is that, there are more chances of getting better esthetics in our final prosthesis. Although patients can't see with such prosthesis but it can definitely help patients to live life with self-confidence and respect, without being stared by people⁵.

IV. Conclusion

The use of custom-made ocular prosthesis has been a boon to the patients who cannot afford for the implant placement¹¹ Fabrication of the custom ocular prosthesis is described using prefabricated stock eye shell.

References

- [1]. Jethwani, J., Jethwani, G., & Verma, A. (2011). Functional Impression Technique for an Ocular Prosthesis. *The Journal Of Indian Prosthodontic Society*, 12(1), 55-58. doi: 10.1007/s13191-011-0099-0
- [2]. Da Breo. Surgical and prosthetic considerations in the management of orbital tumors. *J Prosthet Dent* 1992;67:106-12.
- [3]. Ow RK, Amrith S. Ocular prosthetics: Use of a tissue conditioner material to modify a stock ocular prosthesis. *J Prosthet Dent* 1997;78:218-22.
- [4]. Gunaseelaraj R, Karthikeyan S, Kumar MN, Balamurugan T, Jagadeeshwaran AR. Custom-made ocular prosthesis. *J Pharm Bioall Sci* 2012;4:177-9.
- [5]. Doshi PJ, Aruna B. Prosthetic Management of patient with ocular defect. *J IndProsthodontSoc* 2005; 5: 37-38
- [6]. Cain, J. (1982). Custom ocular prosthetics. *The Journal Of Prosthetic Dentistry*, 48(6), 690-694. doi: 10.1016/s0022-3913(82)80030-9
- [7]. Taicher S, Steinberg HM, Tubiana I, Sela M (1985) Modified stock eye ocular prosthesis. *J Prosthet Dent* 54:95-98
- [8]. Benson P (1977) The fitting and fabrication of a custom resin artificial eye. *J Prosthet Dent* 38:532-538
- [9]. Artopoulou II, Montgomery PC, Wesley PJ, Lemon JC (2006) Digital imaging in the fabrication of ocular prostheses. *J Prosthet Dent* 95:327-330
- [10]. Taylor TD (2000) *Clinical maxillofacial prosthetics*, 3rd edn. Quintessence Publishing Co. Inc, Chicago, pp 265-276
- [11]. Gupta, R., & Padmanabhan, T. (2012). Prosthetic Rehabilitation of a Post Evisceration Patient with Custom Made Ocular Prosthesis: A Case Report. *The Journal Of Indian Prosthodontic Society*, 12(2), 108-112. doi: 10.1007/s13191-012-0115-z

Dr. Mrugnayani P. Patel "Prosthetic Rehabilitation Of Custom Made Ocular Prosthesis In Ocular Defect: A Case Report." *IOSR Journal of Dental and Medical Sciences (IOSR-JDMS)*, 19(3), 2020, pp. 15-21.