

Endodontic Management of Auxillary Roots in Mandibular First Molars : A Case Series

Dr.Sweta Rastogi¹, Dr.K.S.Banga², Dr.Shibani Grover³,
Dr.Ajinkya Mansing Pawar⁴

1.Tutor, Department Of Conservative Dentistryand Endodontics, ESIC Dental College And Hospital, Rohini, Delhi, India

2. Professor and Head Of Department, Department Of Conservative Dentistryand Endodontics, Nair Hospital Dental College, Mumbai, India

3. Professor and Head Of Department, Department Of Conservative Dentistryand Endodontics, ESIC Dental College And Hospital, Rohini, Delhi, India

4.Assistant Professor, Department Of Conservative Dentistryand Endodontics, Nair Hospital College, Mumbai, India

Abstract: Success or failure of any treatment equally depends on the technical expertise as well as on the diagnostic proficiency of the clinician. It is conventional to find a mesial and a distal root in a mandibular first molar. Hence if an additional supernumerary root is located distolingually it is called Radix Entomolaris. To prevent the endodontic mishaps and achieve a predictable outcome of endodontic therapy, it is important to have a detailed knowledge about prevalence, classifications, variations, morphology, diagnosis and management strategy of Radix Entomolaris. Use of advanced technologies like magnification, 3-D imaging cone-beam computed tomography (CBCT), and advanced nickel-titanium (Ni-Ti) rotary files enhance the success of endodontic treatment. The current case series presents the diagnosis and management of Radix Entomolaris.

Keywords: Disto-lingual root, Magnification, Mandibular first Molar, Radix Entomolaris, Supernumerary canal.

Date of Submission: 25-02-2020

Date of Acceptance: 09-03-2020

I. Introduction

As reported by several authors the permanent mandibular first molar most commonly has two roots (mesial and distal) with two root canals in mesial and mostly one in distal root.^{1,2} Carabelli first described the presence of supernumerary root in permanent mandibular first molar in 1844.³ Based on the location of the supernumerary root when located distolingually it is called Radix Entomolaris and when located mesiobuccally it is called Radix Paramolaris. The external morphology of mandibular first molar having an extra root located lingually or buccally has been described by Carlsen and Alexandersen.⁴ The percentage of Radix Entomolaris in Indian population is minor and it is not a predictable finding observed during dental procedures. Hence the knowledge of variations is important for the diagnosis as well endodontic management of the tooth. This article presents diagnosis of Radix Entomolaris with variations and its management.

II. Case Reports

Case 1: A 21 year old female patient had been referred to Dept of Conservative Dentistry and Endodontics with the chief complain of pain with respect to left mandibular posterior tooth region. She gave a history of pain being referred to head and ear on the left side due to which she visited a private clinic and sought treatment for the same. Clinical examination of the concerned tooth revealed an open dressing and the tooth was tender on percussion. Removal of the dressing showed that access opening had been attempted previously. There was an exaggerated pulp response to electric pulp test and thermal tests. Radiographic examination revealed coronal radiolucency extending up to the pulpal floor and a radiolucency surrounding the distal root. The tooth involved was 36. The diagnosis made was symptomatic apical periodontitis.

Root canal treatment was initiated after taking written informed consent from the patient. Local anesthesia (2% lidocaine with 1:2,00,000 adrenaline) was administered and tooth was isolated using rubber dam (Coltène Whaledent, Langenau, Germany). Access opening was modified with Endo access bur (Dentsply, Maillefer, Ballaigues, Switzerland) and then pulp chamber was visualized under magnification (ADMETEC LOUPES, 3.2X), it revealed 5 distinct orifices which were confirmed with endodontic explorer (DG-16, Hu-

Friedy). Mesially, 3 canals located were mesio-buccal, middle-mesial, mesio-lingual. Distally, two canals located were disto-buccal, disto-lingual. Identification of a separate disto-lingual canal orifice clinically and an additional root outline present disto-lingual radiographically according to SLOB technique was suggestive of presence of RE (Type II RE). Root canals were negotiated using Profinder (Dentsply Maillefer, Ballaigues, Switzerland). Working length was assessed using electronic apex locator [Propex pixi, Dentsply Maillefer] and then confirmed using IOPA radiograph. Bio-mechanical preparation was done using crown-down technique with rotary Ni-Ti files [Pro-taper gold, Dentsply-Maillefer]. Intermittent irrigation was done using 3% sodium hypochlorite [Hyposol Prevest Denpro Ltd] solution followed by final flushing with 17% EDTA solution [Prevest Denpro Ltd] to enable the smear layer removal. Calcium hydroxide-iodoform paste was used as an intracanal medicament [Metapex, META Biomed Co. Ltd., Korea]. In the subsequent visit, gutta-percha master cones were selected [ProTaper, Dentsply Maillefer] and verified radiographically, obturation was done using Gutta Percha cones and AH PLUS sealer [De Trey Dentsply, Konstanz, Germany]. Post endodontic restoration was done using composite. [SDR™ composite, Dentsply].

Case 2 : A 45 year old female patient reported with the chief complain of dislodged restoration and dull aching pain with respect to right mandibular posterior tooth region for past one month. Clinical examination showed a fractured amalgam restoration and secondary caries beneath the existing restoration with respect to 36. Radiographic examination showed secondary caries involving distal pulp horn and widening of the periodontal ligament space of the distal root. There was a delayed pulp response to electric pulp test and thermal tests. The diagnosis of chronic apical periodontitis was made. Identification of an additional root outline present disto-lingual radiographically according to SLOB technique was suggestive of presence of RE (Type I RE). After written informed consent from the patient root canal treatment was initiated aided by magnification, location of disto-lingual canal orifice confirmed presence of RE clinically. Bio-mechanical preparation was done using Ni-Ti rotary files, followed by obturation with Gutta Percha as per above mentioned protocol.

Case 3 : A 25 year old female patient reported with the chief complaint of spontaneous pain with respect to right mandibular posterior tooth region for past two days. Patient gave a history of amalgam restoration done in 36 three years back. Clinical Examination showed a discoloration surrounding the restoration suggestive of secondary caries beneath the existing restoration with respect 36. Tooth was tender on percussion. Radiographic examination showed secondary caries involving mesial pulp horn along with slight widening of the periodontal ligament space of the mesial root. There was an exaggerated pulp response to electric pulp test and thermal tests. The diagnosis of chronic apical periodontitis with acute exacerbation was made. After written informed consent from the patient root canal treatment was initiated and the entire procedure was performed following the above mentioned protocol. Identification of an additional root outline present disto-lingual radiographically according to SLOB technique is suggestive of presence of RE (Type III RE) which was confirmed clinically by locating the disto-lingual canal orifice.

III. Discussion

According to the literature, Radix Entomolaris is relatively a genetic trait than a developmental anomaly. The etiology behind Radix Entomolaris is unknown but could be due to disturbances during tooth formation or due to atavistic gene or polygenic system.^{5,6} The identification of Radix Entomolaris in mandibular first permanent molar⁷ is associated more with ethnic groups of mongoloid origin (>30%), rather low prevalence (<5%) is noticed in white Caucasian, Eurasian and Indian populations and (<3%) is noticed in African populations.^{5,6,8,9} Radix Entomolaris may be a finding in first, second and third mandibular molars, but is least common in mandibular second molar.¹⁰ There is greater prevalence for occurrence of RE in left mandibular molars.¹⁰ The tendency for the bilateral occurrence for RE ranges from 37 - 67%.^{4,10,11,12} Radix Entomolaris has been classified by **Carlsen & Alexandersen** (1990) into four different types depending on the location of its cervical part⁴

1. Type A: the RE is located lingually to the distal root complex which has two cone-shaped macrostructures.
2. Type B: the RE is located lingually to the distal root complex which has one cone-shaped macrostructures.
3. Type C: the RE is located lingually to the mesial root complex.
4. Type AC: the RE is located lingually between the mesial and distal root complexes.

De Moor et al. (2004) classified Radix Entomolaris depending on the curvature of the root or root canal into 3 types⁷:

1. Type I : a straight root or root canal.
2. Type II : a curved coronal third which becomes straighter in the middle and apical third.
3. Type III: an initial curve in the coronal third with a second buccally oriented curve which begins in the middle or apical third.

Song JS et al. (2010) added two more newly defined variants of Radix Entomolaris¹²:

1. Small type: length shorter than half of the length of the disto buccal root.

2. Conical type: smaller than the small type and having no root canal within it.

Clinically, a RE may present with a more rounded crown, a supernumerary cusp, prominent disto-lingual lobe or cervical prominence which are suggestive of a supernumerary root. Radiographically, RE presents with double outline of the distal root or root canal due to presence of an additional disto-lingual root, but at times it is not identified due to slender root and blurred outline of the distal root.^{10,13} Therefore diagnosis of RE requires thorough inspection of the pre-operative radiograph, additional radiographs taken with different horizontal angulations (20 to 30 degrees) and it is suggested that a mesial angled radiograph is superior to distal angled radiograph for the detection of RE.^{10,13}

Clinical methods like Champagne bubble test, use of instruments like an endodontic explorer i.e., DG-16 and JW-17, pathfinder and micro-openers, White line test and Red line test, transillumination test and periodontal probing are commonly used to identify missed or extra canals. Cone beam computed tomography (CBCT) has emerged as a useful tool in detection of complex root anatomies, missed canals, morphology of the roots hence it can be used to diagnose RE. CBCT in mandibular molars helps to identify middle mesial canals which is a rare finding. Use of CBCT is still limited due to its cost and availability.¹⁴ Magnification has become an indispensable tool especially for locating orifices, negotiating canals. Magnification aids commonly used in dentistry are magnifying dental loupes with magnification ranging from 2.5x to 3.5x and surgical operating microscope.

A group of epidemiological survey supports the impact of missed canals on endodontic failures, demonstrating a direct link between the complexity of the root canal system and the incidence of post-treatment disease.¹⁵ The more extensive and classic of these studies is the Washington study, which was conducted at the University of Washington, revealing an almost 9% failure rate 2 years after treatment.¹⁶ 42% incidence of missed roots or root canals was discovered while investigating association between asymmetric obturations and locating additional canal space clinically.¹⁷

The disto-lingual root of RE also possess numerous variations and complexities i.e., it ranges from being shorter/longer than the distal root, has a slender outline and is often curved beginning from middle third to apical third¹³. This may pose numerous endodontic problems like strip perforation, straightening of the root canal, ledge formation, transportation, instrument separation, loss of working length. These mishaps are mostly encountered during the attempt to locate the extra orifice, coronal enlargement and bio-mechanical preparation during endodontic therapy specifically in type III RE.^{10,13}

Clinical management of RE should be aimed at minimizing the potential complications. The management begins with the meticulous diagnosis using multiple angulated radiographs and CBCT. Followed by which access opening should be done using magnification aided by endodontic explorers, micro-openers, ultrasonics. Avoid excess removal of dentin to avoid perforations while searching the orifice disto-lingually. Bio-mechanical preparation requires adequate coronal pre-flaring and canal exploration should be done with smaller pre-curved files (size 8 or 10). Glide path should be prepared, accurate working length should be determined and depending on the knowledge of canal curvature and morphology of the canal, the shaping should be done with nickel-titanium rotary files using crown-down technique to create a centered and conservative canal preparation.^{10,13}

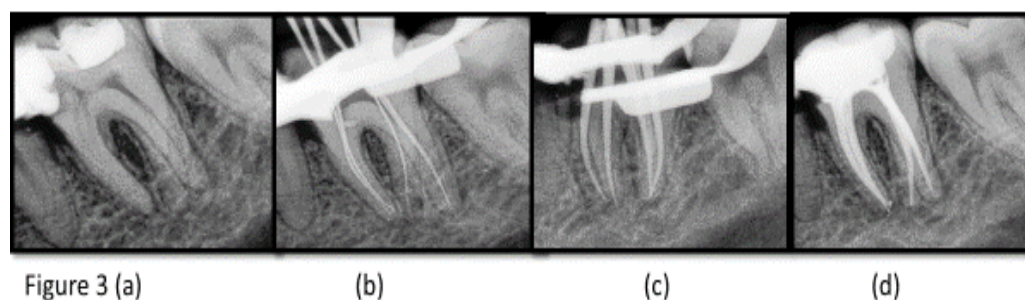
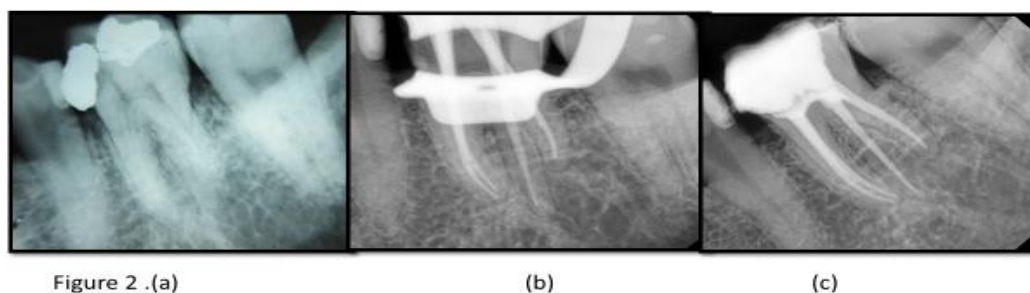
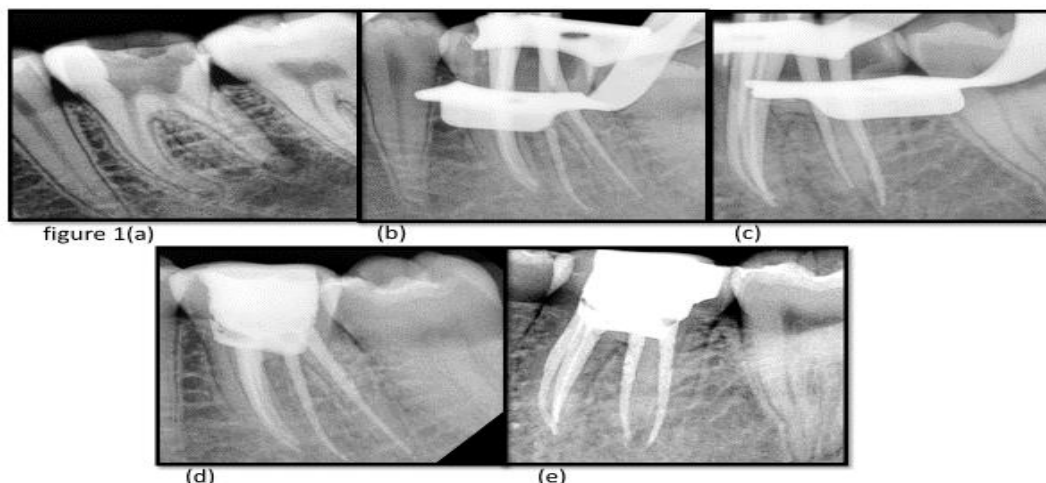
IV. Conclusion

The management of radix entomolaris begins with scrupulous diagnosis which can be enhanced using 3d radiography and magnification, followed by the meticulous preparation using the advanced Ni-Ti rotary endodontic files depending on the morphology of the tooth to achieve successful outcome of endodontic therapy.

References

- [1]. Barker B, Parsons K, Mills P, Williams G. Anatomy of root canals III, Permanent mandibular molars. *Aus Dent J*.1974; 19(6):408-13.
- [2]. Vertucci FJ. Root canal anatomy of the human permanent teeth. *Oral surg, Oral Med, Oral Pathol*.1984;58(5):589-99.
- [3]. Carabelli G, Carabelli G, von Lunkaszprie GC, Georg Carabelli E. *Systematisches Handbuch der Zahnheilkunde*: Georg OlmsVerlag; 1844.
- [4]. Carlsen O, Alexandersen V. Radix entomolaris: identification and morphology. *Scand J Dent Res*. 1990; 98: 363-373.
- [5]. Curzon ME, Curzon JA .Three-rooted mandibular molars in the Keewatin Eskimo. *J Can Dent Assoc (Tor)*.1971; 37: 71-72.
- [6]. Walker RT. Root form and canal anatomy of mandibular second molars in a Southern Chinese population. *Endodontics& Dental Traumatology*.1988;14: 325-329.
- [7]. De Moor RJ, Deroose CA, Calbertson FL.The radix entomolaris in mandibular first molars: an endodontic challenge. *Int Endod J*. 2004;37: 789-799.
- [8]. Ferraz J, Pecora JD. Three-rooted mandibular molars in patients of Mongolian, Caucasian and Negro origin. *Braz Dent J*. 1993;3(2):113-7.
- [9]. Curzon M. Three-rooted mandibular permanent molars in English Caucasians. *J Dent Research*. 1973;52(1):181-.

- [10]. Abella F, Patel S, Durán-Sindreu F, Mercadé M, Roig M. Mandibular first molars with disto-lingual roots: review and clinical management. *Int Endod J*.2012; 45: 963-978.
- [11]. Tu MG, Tsai CC, Jou MJ, Chen WL, Chang YF, et al. Prevalence of three-rooted mandibular first molars among Taiwanese individuals. *J Endod*. 2007; 33: 1163-1166.
- [12]. Song JS, Choi HJ, Jung IY, Jung HS, Kim SO. The prevalence and morphologic classification of distolingual roots in the mandibular molars in a Korean population. *J Endod*.2010; 36: 653-657.
- [13]. Calberson FL, De Moor RJ, Deroose CA. The radix entomolaris and paramolaris: Clinical approach in endodontics. *J Endod*. 2007;33:58-63.
- [14]. Aggarwal V, Singla M, Logani A, Shah N. Endodontic management of a maxillary first molar with two palatal canals with the aid of spiral computed tomography: a case report. *J Endod*. 2009;35: 137-139.
- [15]. Cantatore G, BeruttiE&Castellucci A. Missed anatomy: frequency and clinical impact. *Endodontic Topics* 2009, 15, 3–31
- [16]. Ingle JL, Beveridge EE, Glick DH, Weichman JA. *Modern endodontic therapy*. Endodontics, 4thEdn. Baltimore, MA: Williams and Wilkins, 1994: 27–53.
- [17]. HoenMMHoen MM, Pink FE. Contemporary endodontic retreatments: an analysis based on clinical treatment findings. *J Endod* 2002: 28: 834–836.



Legends to the figures

Figure 1 : RE with middle mesial canal

- (a) : Pre-operative radiograph
 (b) : master cone radiograph taken with mesial angulation
 (c) :master cone radiograph taken with distal angulation showing the mesiobuccal, middle mesial and mesiolingual canal in the mesial root
 (d)&(e) : obturation radiograph with post endo restoration

Figure 2 : RE

- (a) :Pre-operative radiograph
- (b) :master cone radiograph
- (c) :obturation radiograph with post endo restoration

Figure 3 : RE

- (a) :Pre-operative radiograph
- (b) :working length determination radiograph
- (c) :master cone radiograph
- (d) : obturation radiograph with post endo restoration

Dr.Sweta Rastogi,etal. "Endodontic Management of Auxillary Roots in Mandibular First Molars : A Case Series." *IOSR Journal of Dental and Medical Sciences (IOSR-JDMS)*, 19(3), 2020, pp. 57-61.