

Arrhenoblastoma of the Ovary (A Case Report)

Dr Jhantu Kumar Saha¹, Dr Sreeparna Roy², Dr Arjun Das³

¹Associate Professor Department Of Obstetrics And Gynaecology, Medical College, Kolkata

²Resident, Department Of Obstetrics And Gynaecology, Medical College, Kolkata

³Resident, Department Of Obstetrics And Gynaecology, Medical College, Kolkata

Corresponding Author: Dr Sreeparna Roy

Date of Submission: 20-01-2020

Date of Acceptance: 10-02-2020

I. Introduction:

Arrhenoblastoma of the ovary is a rare functioning ovarian neoplasm which occurs chiefly in young, previously normal women of childbearing age. It is usually associated with clinical evidence of defeminization and virilization. The name 'Arrhenoblastoma' was applied by Robert Mayer in 1930 to rare ovarian tumours accompanied by signs of masculinization. In 1965, Novak and Long reviewed all authentic cases of arrhenoblastoma collected from Ovarian Tumour Registry. Since then sporadic reports have been appearing in the literature. Removal of the tumour usually checks the masculinization and is followed by a return of femininity.

Herein, we report a case of a 31-year-old female presenting with amenorrhea, features of virilization, and abdominal pain. Histopathological examination revealed marked focal anaplasia in this tumor of, otherwise, intermediate differentiation along with the presence of heterologous elements. Reporting of such elements is imperative for adequate treatment and deciding follow-up.

II. Case Report:

Mrs. Manasi Hindu female 31 years of age was admitted in Eden Hospital of Medical College and Hospital, Kolkata on 18th July, 2017 with the complaint of cessation of menstruation, excessive growth of hair on face, hoarseness of voice, all since two years.

Obstetric History: Marital life ten years. Two children, no abortions. Both vaginal deliveries.

Gynaecological History: Menarche at 14 years. Cycles were previously regular but followed by amenorrhea since two years. General condition on admission patient was moderately nourished, not anemic, heart and lungs normal; temperature normal, pulse rate 86/minute, blood pressure 126/90 mmHg. Marked hirsutism was present. Voice was hoarse. Breasts were atrophic. (Fig. 1).

Abdominal Palpation: Abdomen was soft, no masses were felt. External examination, revealed male clitoral enlargement of 2.5 cm.

Speculum Examination: Cervix was found to be healthy.

Bimanual Examination: Vagina was of good depth. Uterus anteverted, normal size. A solid mobile mass was felt through right fornix, nontender separate from the uterus, around 5x6 cm in size.

Provisional diagnosis of a masculinizing tumour of ovary was made.

Investigations:

Blood: Haemoglobin 10.2 g/dl, Red blood cells 5.5 mill/c.mm. White blood cells 9,200/cu.mm. Differential count: Neutrophils 78 % lymphocytes 15% eosinophils 5% monocytes 2%.

Urine Examination: Albumin and sugar nil. Blood group 'A' Rh positive. Blood urea 24.5 mg. per cent. Vaginal smear showed a generally deficient oestrogenic pattern. The cells showed an arrest of maturation at the level of intermediate cells, which were present in clumps. Noparabasal cells seen. Endometrial biopsy was done. Testosterone 430.88 ng/dl, DHEAS 254.5 mcg/dl, prolactin 7.74 ng/ml, FSH-2.1 mIU/ml, LH 1.2 mIU/ml TSH - 2.04 mIU/mL. X-ray examination of sella turcica for evidence of any pituitary enlargement nil abnormal noted. X-ray chest did not reveal any secondaries. X-ray of long bones for evidence of osteoporosis, no osteoporosis noted. Glucose tolerance test was within normal limits. CT Whole abdomen showed a solid SOL in right adnexa 55*66 mm, no mesenteric lymph node enlargement seen.

Operative notes

On 20th July 2017, under spinal anaesthesia, pelvic examination was repeated and the pelvic findings were confirmed. At laparotomy both the ovaries were pearly white. On palpating the right ovary a firm nodular mass, size 5x6 cm was seen arising from right ovary. It was suspected to be the seat of an ovarian tumour and right salpingo-oophorectomy was done. No similar mass was found in the left ovary. Abdomen was closed in

layers. Naked eye examination of right ovary: (Fig-2 &3) Size 5cm. x 6cm. shape was oval, external surface smooth, greyish-white in colour, consistency solid. Cut Section: Showed variegated pattern with a well circumscribed neoplasm.

Microscopic Examination: The tumor was composed of open and closed tubules, alveolar pattern, along with cellular lobules and cords composed of darkly staining cells. The cells had scant-to-moderate amount of cytoplasm, round-to-oval nucleus, and 1 nucleoli. Admixed clusters and nests of Leydig cells were noted within the tumor. Delicate fibrous stroma was seen at places in which Leydig cells were found in small clusters, cords, and lying singly. Mitotic figures were identified. Heterologous elements in the form of glands lined by mucinous epithelium were seen. Focal area showed marked anaplasia in the form of many large, bizarre, and multinucleated cells. No capsular breach was identified.

The patient was followed up by weekly vaginal smears to note any improvement in oestrogen effect. Vaginal smear showed gradual but steady improvement. There was a steady rise of superficial cells. At the end of six weeks postoperatively, superficial cell count was 70 per cent indicating a return of oestrogenic activity.

She was discharged on 4th August 2017 with instructions to come for periodic check-up once a month (Fig-4).

Three months later she reported with a history of having had normal periods after discharge from the hospital.

On general examination, her habitus was found to be more feminine, breasts were enlarged with pigmentation of the nipple and areola. Facial hair, clitoral enlargement and hoarseness of voice were still present.

On bimanual examination, cervix was found to be soft. Uterus was anteverted, normal size. No palpable pathology felt through the fornices.

FIGURES TABLE:

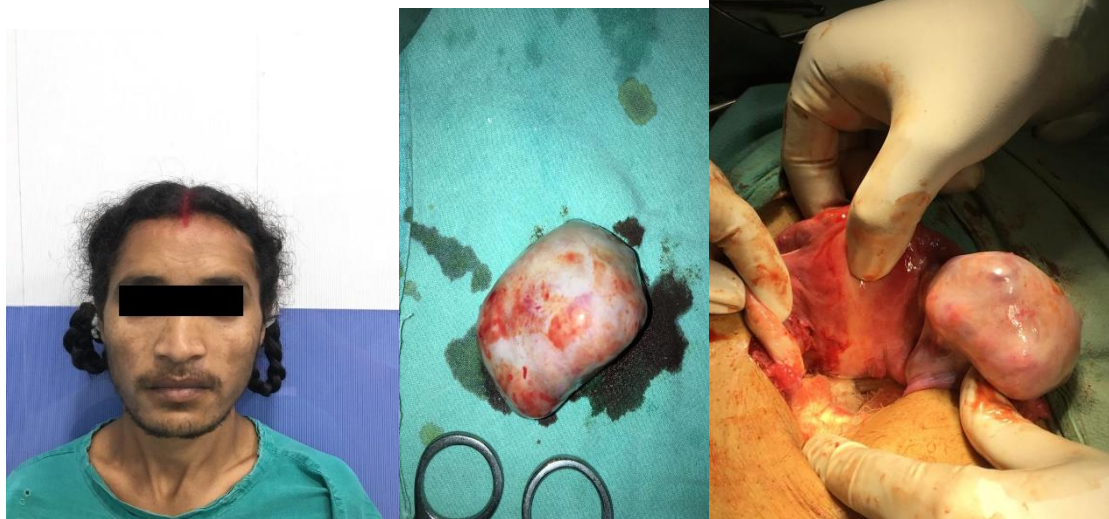


Fig-1

Fig-2

Fig-3

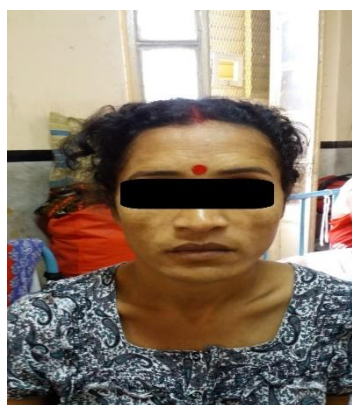

Fig-4

III. Discussion

We, hereby, report a case of SLCT of intermediate differentiation with gastrointestinal-type heterologous elements and marked focal anaplasia.

SLCT is a rare neoplasm and is more frequently seen in young women with a mean age of 25 years.[1] Macroscopically, the size ranges from 2 to 35 cm and may be solid, solid-cystic, or rarely cystic.

Microscopically, well- and moderately differentiated tumors are encountered most frequently.[2] Well-differentiated cases consisted of solid or hollow tubules composed of Sertoli cells which lack significant nuclear atypia or mitotic activity. Leydig cells are seen in delicate fibrous stroma in small clusters, cords, and lying singly. The tumors with intermediate differentiation, as in our case report, comprise cellular lobules of darkly staining Sertoli cells, typically with scant cytoplasm, and admixed in a jumbled fashion with Leydig cells. Nested to alveolar arrangement and solid and hollow tubules lined by Sertoli cells may also be seen. Mitotic figures average 5/10 HPF. Heterologous elements (endodermal elements or mesenchymal elements) are observed in one-fifth of this neoplasm. Endodermal elements are typically seen in tumors with intermediate differentiation. Mesenchymal elements are seen more in association with poorly differentiated tumors.[3]

The prognosis of SLCT is overall favorable although it is significantly correlated with stage and degree of differentiation.[4,5] Nineteen percent of tumors with heterologous elements were seen to be clinically malignant in a study by Young and Scully.[4]

Adjuvant chemotherapy is recommended for patients with advanced stage, intermediate and poor differentiation, retiform pattern, and presence of heterologous elements.[6]

Although focal anaplasia is described in cases with intermediate differentiation;[1] however, exact course of disease is not known in these cases due to lack of data in this area. Such cases may also behave in a clinically malignant way; therefore, we want to emphasize that more studies are required with proper follow-up of these cases. It might help in deciding the protocols for the use of adjuvant therapy in such cases. SLCT recurs relatively early (within 2–3 years of initial diagnosis[3,4] therefore, it becomes important to closely follow-up those cases where the tumor has got poor prognostic features. It will help in detecting and treating recurrence early.

IV. Conclusion:

SLCT typically has good prognosis. However, adequate sampling and through microscopic examination are required to look for heterologous elements and focal anaplasia as adjuvant therapy might have a role in these patients for a better outcome. Follow-up of these patients is crucial to detect recurrence at an early stage.

Declaration of Patient Consent:

The authors certify that they have obtained all appropriate patient consent forms. In the form the patient(s) has/have given his/her/their consent for his/her/their images and other clinical information to be reported in the journal. The patients understand that their names and initials will not be published and due efforts will be made to conceal their identity, but anonymity cannot be guaranteed.

References:

- [1]. Kurman RJ, Carcangiu ML, Herrington CS, Young RH. WHO Classification of Tumours of Female Reproductive Organs. 4th ed. Lyon: International Agency for Research on Cancer; 2014. [Google Scholar]
- [2]. Nouriani M, Felix JC, Dubeau L. Histogenesis and histopathological characteristics of Sertoli-Leydig cell tumors. *CME J GynecolOncol.* 2002;7:114–20. [Google Scholar]
- [3]. Lantzsch T, Stoerer S, Lawrenz K, Buchmann J, Strauss HG, Koelbl H, et al. Sertoli-Leydig cell tumor. *Arch Gynecol Obstet.* 2001;264:206–8. [PubMed] [Google Scholar]
- [4]. Young RH, Scully RE. Ovarian Sertoli-Leydig cell tumors. A clinicopathological analysis of 207 cases. *Am J SurgPathol.* 1985;9:543–69. [PubMed] [Google Scholar]
- [5]. Outwater EK, Wagner BJ, Mannion C, McLarney JK, Kim B. Sex cord-stromal and steroid cell tumors of the ovary. *Radiographics.* 1998;18:1523–46. [PubMed] [Google Scholar]
- [6]. Gui T, Cao D, Shen K, Yang J, Zhang Y, Yu Q, et al. A clinicopathological analysis of 40 cases of ovarian Sertoli-Leydig cell tumors. *GynecolOncol.* 2012;127:3849. [PubMed] [Google Scholar]

Dr Sreparna Roy, et al. "Arrhenoblastoma of the Ovary (A Case Report)." *IOSR Journal of Dental and Medical Sciences (IOSR-JDMS)*, 19(2), 2020, pp. 19-21.