

3D Reconstruction & Imaging Findings of Carotid Body Tumor

Dr Parveen Chandna¹, Dr Garima Pureha², Dr Rohtas K Yadav³,
Dr Shreyas Guha²

Senior Resident¹, Junior Resident², Director³, Deptt. Of Radio-Diagnosis, Pt.B.D.Sharma Post Graduate
Institute Of Medical Sciences, Rohtak, Haryana, India

Correspondence: Dr. Parveen Chandna

Abstract

Background and Objectives: The two most common paragangliomas represent in the form of a neck mass that arise at the carotid bifurcation (carotid body tumor) and along the nodose ganglion (ganglion nodosum) of the vagus nerve (glomus vagale). The same reflect as a typical mass which manifests as a painless slow-growing mass in the anterior triangle of the suprahyoid neck. Carotid body tumors originate in the juxtahyoid neck and isolate the internal and external carotid arteries on sectional imaging. Recent advents of multidetector CT have proved their efficacy with provision of even exceptional details improvising delineation of the normal structures of head & neck with pathological abnormalities.

To demonstrate usefulness of Toshiba lightning aquilion 16 slice multi detector computerized tomography (MDCT) scan in diagnosis of the carotid body tumor and assessment of the normal structures of head & neck with pathological abnormalities.

Material and Methods: The study had been carried out in the Department of Radiodiagnosis, PGIMS, Rohtak. In this method potential possibility has been explored confirming through cumulative observational study in which we evaluated 10 patients suspected of having carotid body tumor based on ultrasound & clinical findings. After taking a brief note of properly informed written consent and complete history, thorough clinical examination was done and these patients were subjected to CT scan.

Results: Dynamic CT scanning following I.V contrast administration has been duly recognised as a convincing tool for critically identifying carotid body paragangliomas. In our study, carotid body tumor had been detected in 8 patients out of 10.

Conclusion: The most characteristic feature of the glomus vagale or carotid body tumor on CT scans appear as an intense enhancement following intravenous contrast administration. Carotid body tumors can be very well depicted with this modern imaging technique with 3D reconstruction.

Key Words: Carotid Body, Paragangliomas, Glomus Vagale, Multi Detector Computerized Tomography (MDCT)

Date of Submission: 23-05-2019

Date of acceptance: 08-06-2019

I. Introduction

Paragangliomas, frequently said to be glomus tumors appear as slow growing neoplasms of neural crest cell origin that originate within the adventitial layer of blood vessels at multiple sites in the head and neck, including the middle ear and temporal bone (glomus tympanicum), parapharyngeal space (glomus jugulare tumors- that arise within the jugular foramen of the temporal bone and generally involve the lower cranial nerves), and larynx. Paragangliomas measuring more than 1.5 cm in diameter must demonstrate curvilinear areas of signal void representing areas of high vascular flow.^{1,2,3}

The imaging diagnosis of paraganglioma must envisage a meticulous exploring for additional lesions as multiple glomus tumors which are found in about 10% of the general population and approximately in 33% of patients with a family history of paraganglioma.^{4,5}

MRI is an absolute technique complete in all respects but multidetector CT with 3D reconstruction is also very useful in the imaging evaluation of suspected glomus or carotid body tumors. Schwannomas are

categorized as avascular lesions on angiography and do not show areas of signal void. Glomus vagale tumors arise accurately in the suprahyoid neck and repose the internal carotid artery anteromedially and the internal jugular vein posterolaterally.^{1,3,6}

II. Material and Methods

The study had been carried out in the Department of Radiodiagnosis, PGIMS , Rohtak. In this method potential possibility has been explored confirming through cumulative observational study in which we evaluated 10 patients suspected of having carotid body tumor based on ultrasound & clinical findings .After taking a brief note of properly informed written consent and complete history, thorough clinical examination was done and these patients were subjected to CT scan.

To demonstrate usefulness of Toshiba lightning aquilion 16 slice multi detector computerized tomography (MDCT) scan in diagnosis of the suspected cases of carotid body tumor and assessment of the adjacent structures.

III. Results

Dynamic CT scanning following I.V contrast administration has been duly recognised as a convincing tool for critically identifying paragangliomas from schwannomas, because the former is associated with a vascular flow curve but the latter is devoid of vascular flow .

In our study, Carotid body tumor had been detected in 8 patients out of 10. Distinguishing areas of signal void within a neck mass on MRI permits the concrete diagnosis of paraganglioma only when the mass is present exactly in the right described location. Other neck masses such as nodal metastases from renal cell or thyroid carcinoma with areas of signal void on MRI, do not depict these vascular repositions. Therefore , MRI depictions are not pathognomonic for paraganglioma and may be seriously viewed in a variety of high-flow lesions.

IV. Case Report

A 35 year old female patient presented with complaints of headache & gradually increasing painless swelling in the left side of neck for 5 months. On clinical examination, a pulsatile swelling which was movable side by side but not vertically noted in left side of neck below the mandible. There was no feature of any neurological deficit.

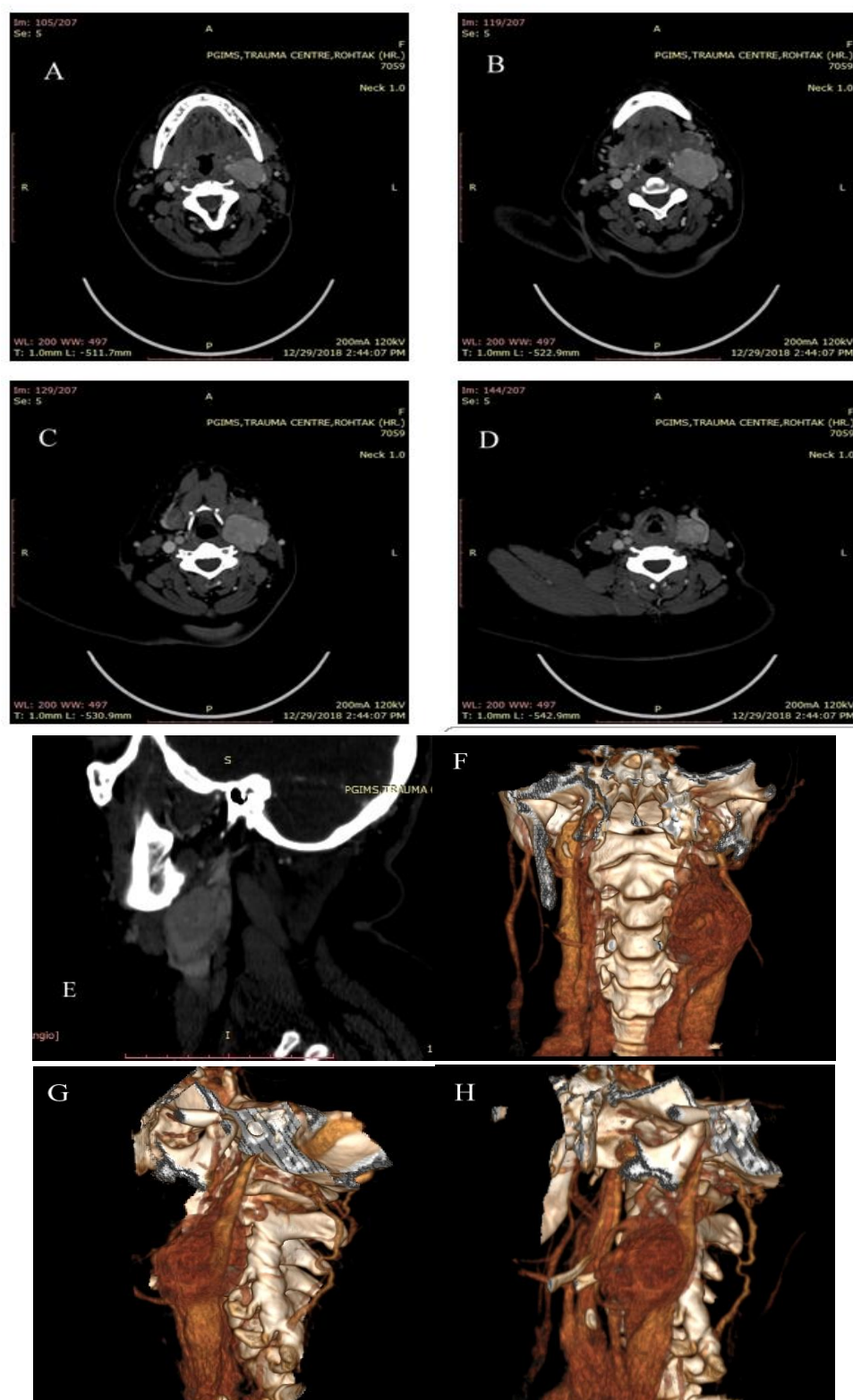


Figure: CECT (A,B,C,D) axial ,(E) sagittal, (F,G,H) 3D reconstruction images show an avidly enhancing well defined lesion measuring 35x34x45 mm noted in left carotid space causing splaying of left internal & external carotid artery showing 'Lyre sign'.The lesion is displacing left submandibular gland anteriorly & compressing upon left internal jugular vein causing luminal narrowing however shows normal contrast opacification.

V. Discussion And Conclusion

Recent advents of multidetector CT have proved their efficacy with provision of even exceptional details improvising delineation of the normal structures of head & neck with pathological abnormalities.

Carotid body tumors are generally pulsatile, and a peculiar bruit may be auscultated over it. Glomus jugular tumor may cause typical erosion of the jugular foramen . Hence, inducing a permeative pattern of destruction in contrast to a neurofibroma or schwannoma existing in the form of scalloped .The most characteristic feature of the glomus vagale or carotid body tumor on CT scans appear as an intense enhancement following intravenous contrast administration.^{1,3,6}

On MRI, paragangliomas appear as highly vascular soft tissue lesions depicting a collection of multiple punctuate and serpentine signal voids in consonance to high-flow intratumoral vessels and foci of high signal intensity due to intratumoral hemorrhages with methemoglobin inducing the characteristic salt-and-pepper appearance .^{4,5,6}

Acknowledgement

No words can ever express my deep sense of gratitude for my parents & my younger brother, for their affections, endurance, inspiration, support, unending blessings, innumerable sacrifices and unceasing encouragement that has moulded me into the person I am today. The expression of my gratitude's will remain incomplete if I fail to register my deep sense of indebtedness to my family members without whose perseverance and affection it would have not been possible for me to undertake this arduous assignment.

Funding : No funding sources.

Conflict of interest: None declared.

Ethical approval: The study was approved by the Institutional Ethics Committee.

Bibliography

- [1]. Van den Berg R. Imaging and management of head and neck paragangliomas. *Eur Radiol* 2005;15:1310–18
- [2]. Vogl R, Bruning H, Schedel, et al. Paragangliomas of the jugular bulb and carotid body: MR imaging with short sequences and Gd-DTPA enhancement. *AJR Am J Roentgenol* 1989;153:583–87
- [3]. Silver AJ, Mawad ME, Hilal SK, Ascherl GF, Chynn KY and Baredes S. Computed tomography of carotid space and related spaces. Part II: Neurogenic tumors. *Radiology* 1984; 150: 729-735.
- [4]. Muhm M, Polterauer P, Gstottner W, Temmel A, Richling B, Undt G, Niederle B, Staudacher M and Ehringer H. Diagnostic and therapeutic approaches to carotid body tumors. *Arch Surg* 1997; 132: 279-284.
- [5]. Shibuya Y, Umeda M, Yoshikawa T, Komori T. Carotid body tumour. *Oral Oncol*. 2002;38:313–7.
- [6]. Zhu J, Han D, Zhou J. Retrospective analysis of the diagnosis and treatment of 11 cases of carotid body tumor. *Lin Chuang Er Bi Yan Hou Ke Za Zhi*. 2005;19:817–9.

Dr. Parveen Chandna. "3D Reconstruction & Imaging Findings of Carotid Body Tumor." IOSR Journal of Dental and Medical Sciences (IOSR-JDMS), vol. 18, no. 6, 2019, pp 10-13.