

Cobwebs in the Brain

Dr.Jemima Evangelyn .T^{*}, Prof.Dr.Rama.K^{**}

^{*} Postgraduate Resident, Institute of Pathology, Madras Medical College

^{**} Professor and Head of the Department of Neuropathology, Institute of Neurosurgery, Madras Medical College

Correspondence Author - Dr.T.Jemima Evangelyn

ABSTRACT

OBJECTIVES: To analyse presentations of fungal infections of the brain clinically and radiologically and role of histopathological examination in the diagnosis of the infections.

MATERIALS AND METHODS: This was a retrospective study for a period of two years. The diagnosis was based on morphology of biopsy material with the aid of special stains.

OBSERVATION AND RESULTS: Of the 1380 specimen received in two years, 550 cases were non-neoplastic. Out of which 98 were infections, and fungal infections accounted for 10 of them. One case presented with otalgia, six had ophthalmic manifestations and three patients presented with paralysis of upper and lower limbs. Radiologically four were diagnosed as granuloma, two as abscess, three cases as space occupying lesion and one case as meningioma. All these cases were diagnosed to have fungal infection using morphology and special stains. Five patients had Aspergillosis, four had mucormycosis and one had maduramycosis.

CONCLUSION: Fungal infections in the brain present in different ways according to the site of invasion and histopathological examination plays a vital role in the diagnosis.

KEY WORDS: Aspergillosis, brain, fungal infections, maduramycosis, mucormycosis.

Date of Submission: 22-05-2019

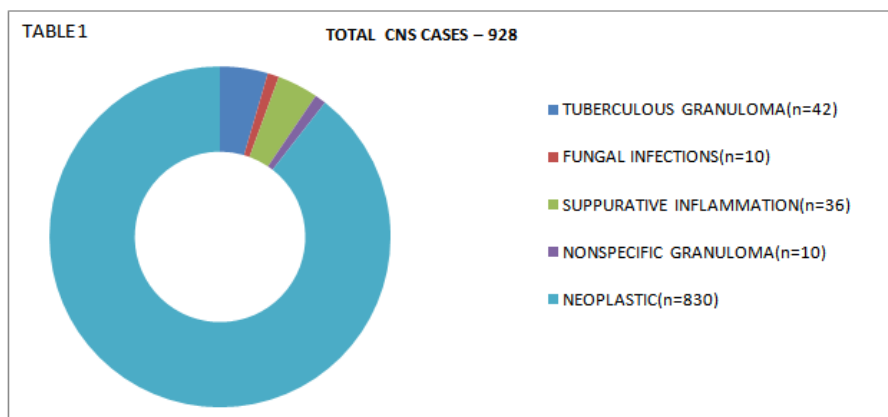
Date of acceptance: 07-06-2019

I. Introduction

The greater incidence of diabetes, organ transplantation, HIV pandemic and chemotherapy for hematological malignancies, have all increased the risk of fungal infection in the brain. The presenting symptoms do not differentiate fungal infections from neoplastic lesions. There are no specific radiological findings too. This study is to analyse the clinical and radiological presentation of various fungal infections of the brain and to find out the importance of histopathological examination in the diagnosis of these infections.

II. Materials And Methods

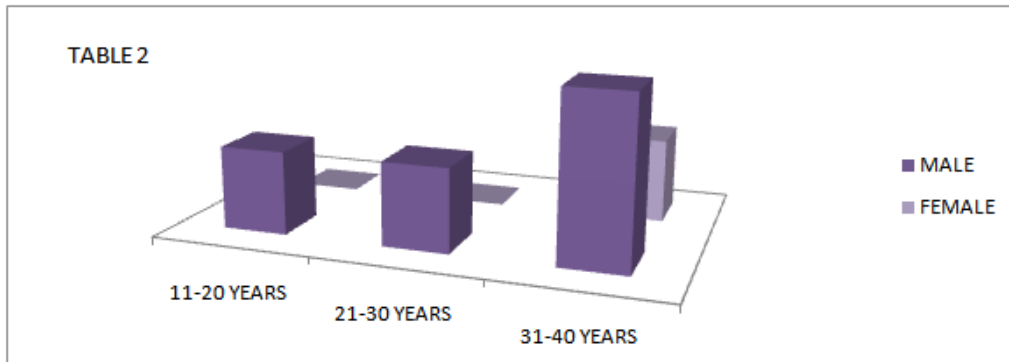
This study is a retrospective study for a period of two years. The diagnosis was based on the morphology of fungi in the tissue sections with the aid of special stains and culture as the gold standard. All cases diagnosed to have fungal infection were included irrespective of age, gender and predisposing factors. The special stains used were periodic acid Schiff and Gomori's methenamine silver. Out of the 928 cases received during the two year period, 830 were neoplastic and 98 cases were nonneoplastic. The distribution of cases is shown in TABLE 1.



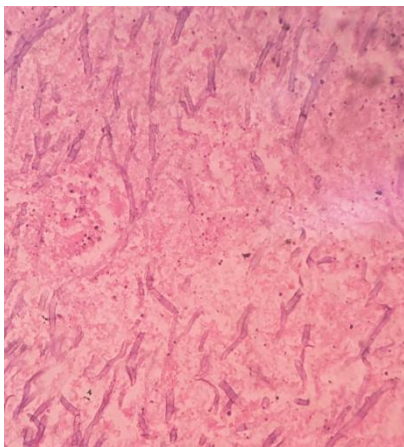
III. Results

The fungal infections of the central nervous system accounted for 1% of the total cases. Out of the ten cases, five were diagnosed as aspergillosis, four were diagnosed as mucormycosis and one was a case of maduramycosis.

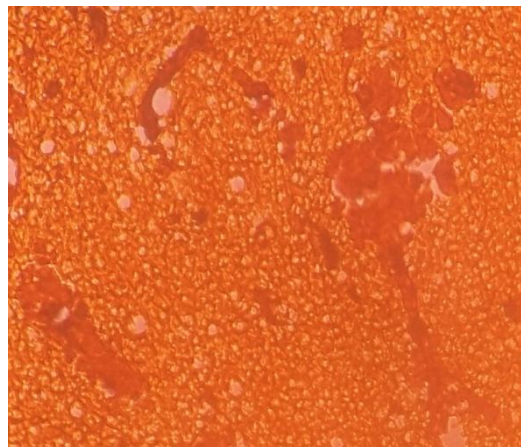
The age and gender distribution of patients with Aspergillosis in the study is shown in Table 2.



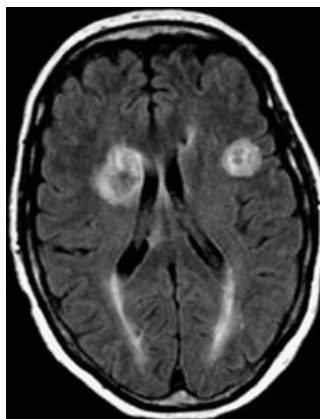
Out of the five, one had history of craniotomy following trauma. He presented with wound discharge from the craniotomy site. Another patient had history of renal transplantation and he was on immunosuppressive treatment. He presented with weakness of limbs. Other three patients had no predisposing factor. They presented with otalgia. CT finding of the postcraniotomy patient was abscess. MRI finding of the posttransplant patient was extradural space occupying lesion. Out of the other three patients, one revealed abscess and two showed granuloma in MRI. Histopathology of the posttransplant patient was different from others. There were extensive areas of necrosis, little inflammation and groups of slender septate hyphae showing acute angle branching were seen. Others showed granulomatous inflammation and fibrosis. (FIGURES 1- 3)



ASPERGILLUS H&E 100x(FIGURE1)

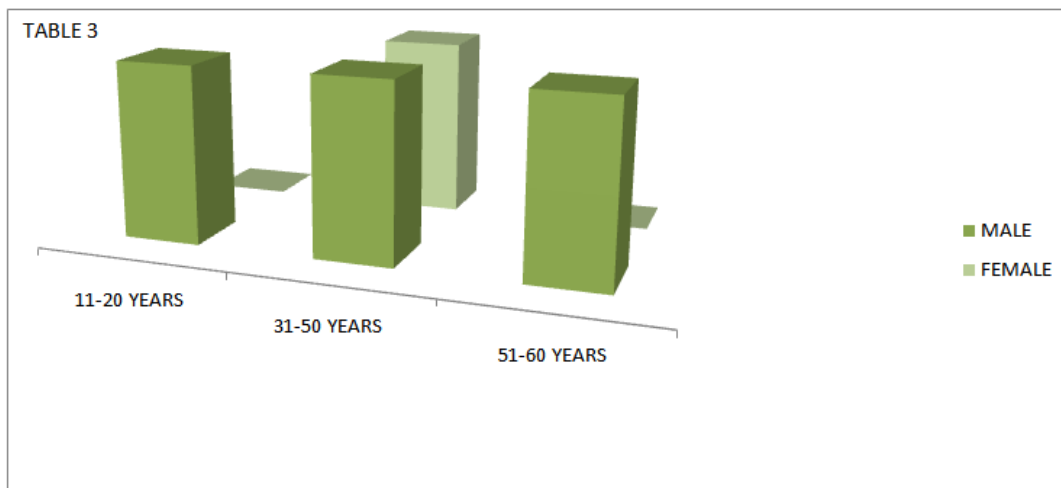


ASPERGILLUS GMS 400x(FIGURE 2)

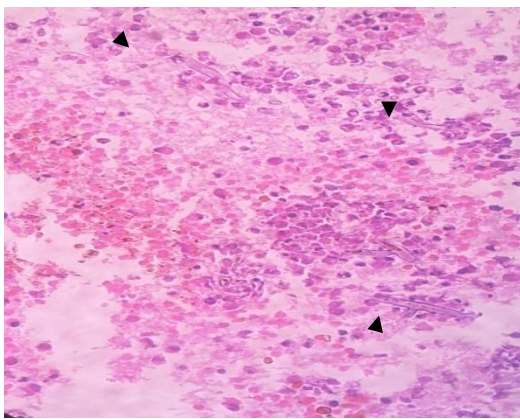


MRI OF ASPERGILLOSIS(FIGURE 3)

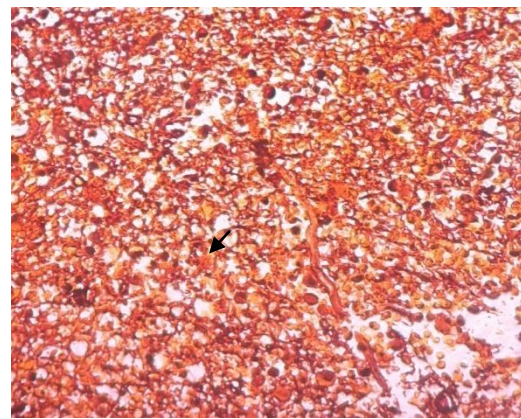
The age distribution of the patients with Mucormycosis is shown in Table 3.



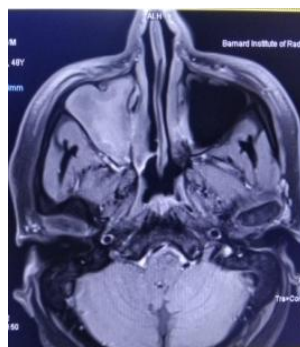
One on the second decade had history of type I diabetes mellitus. All the four patients had history of fungal sinusitis. Three presented with otalgia and two patients with visual disturbances. MRI findings include intracranial abscess, intracranial mass, aggressive infiltrative tumor and superior orbital fissure syndrome. Histopathological examination showed granulomatous inflammation, areas of necrosis and presence of broad aseptate hyphae with right angle branching. (FIGURES 4 – 6)



MUCORMYCOSIS H&E 400x (FIGURE 4)



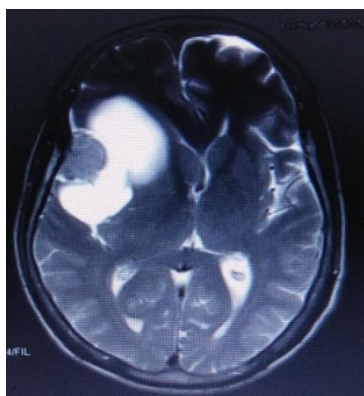
MUCORMYCOSIS GMS 400x (FIGURE 5)



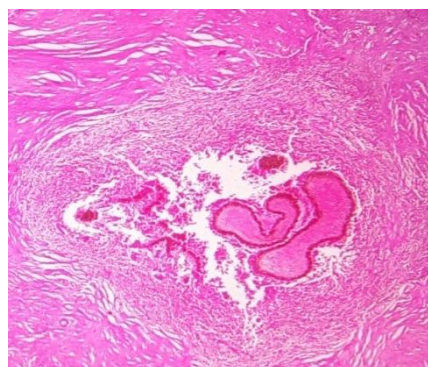MRI – MUCORMYCOSIS(FIGURE 6)

The last case was a 37 years old male with history of trivial head injury. He presented six months later with weakness of right upper and lower limbs. There were no discharging sinuses. MRI showed an extra-axial lesion with irregular margins and adjacent cystic lesion showing heterogenous enhancement. Possibility of peritumoral cystic meningioma was thought of. Histopathology of biopsy specimen showed numerous fungal elements composed of pigmented hyphae exhibiting Splendore- Hoeppli phenomenon along with multiple

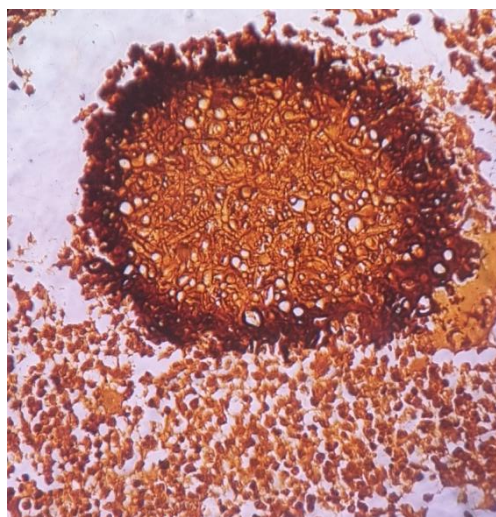
multiple granulomas, foamy macrophages, acute and chronic inflammatory cells. Fungal stains which include periodic acid Schiff and Gomori's methenamine silver confirmed the hyphae to be of fungal origin. (FIGURES 7-10)



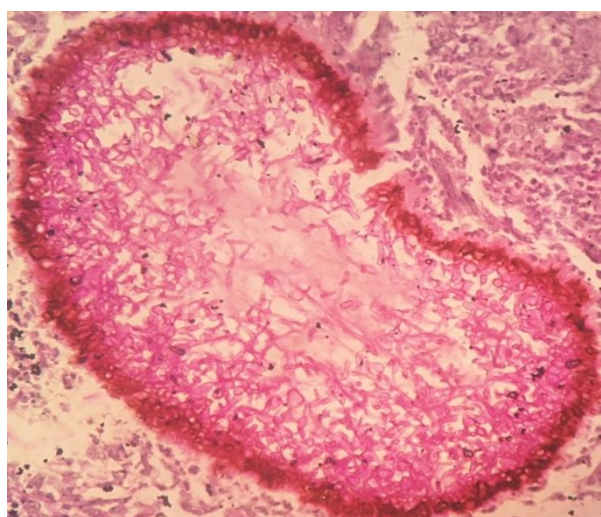MRI – MADURAMYCOSIS(FIGURE 7)



MADURAMYCOSIS H&E 100x(FIGURE 8)



MADURAMYCOSIS GMS 400x (FIGURE 9)



MADURAMYCOSIS PAS 400x (FIGURE 10)

The age distribution of fungal infections of brain is wide. Two patients were immunocompromised and eight patients were immunocompetent. The patients in the younger age group had a definite predisposing factor. Out of the ten cases, eight were direct spread from sinonasal cavity and two were due to direct inoculation. The clinical and radiological features were varying. Histopathology revealed the presence of hyphal elements and confirmed to be of fungal origin with the aid of special stains. The inflammation was varying according to the immune status of the individuals.

IV. Discussion

Fungi are eukaryotic organisms that have their own machinery to survive freely in the environment. They can be unicellular (yeasts) or multicellular forming filamentous structures called hyphae that germinate forming conidia that are released into the environment. These enter the hosts through inhalation or inoculation or rarely through ingestion multiplying in suitable environment. Immune status of the individual plays a vital role in the manifestation of the disease. The two main inflammatory cells involved in defence against fungi. Macrophages act as first defence through pathogen associated molecular patterns. The receptors that recognize the fungal products are Toll- like receptor 2 (TLR2) and C- type lectin receptors (CLR). (1) TLR causes activation of transcription factors like nuclear factor- kappa B (NF-kB) and interferon regulatory factors (IRF) that recruit leucocytes and stimulate cytokine production respectively. Neutrophils provide defence against fungal hyphae by elaborating reactive oxygen species that kill hyphae. T cells, microglia, astrocytes and endothelial cells prevent growth of fungi by producing cytokines like interferon (IFN) gamma, tumor necrosis factor(TNF) alpha, interleukins(IL) 1beta, IL-6 and IL-12.

Fungal infections of the central nervous system are increasing in incidence because of the increasing incidence of HIV, advancement in treatment of hematological malignancies, transplantation and increasing

incidence of diabetes mellitus. The frequently occurring CNS fungal infections include *Aspergillus* species, *Mucorales* genera, *Cryptococcus neoformans*, *Candida* species, *Chromomycotic* fungi, *Histoplasma capsulatum*, *Blastomyces dermatitidis* and *Eumycotic mycetoma*. Of these *Cryptococcus neoformans* is the most common fungi because of HIV pandemic. In non-HIV individuals, *Aspergillus* and *Mucorales* top the list. In present study HIV coinfection was not seen in any patient. This correlates with the study by Sundaram et al.(2)

Clinical manifestations of fungal infections depend on the immunity of the host and the location of fungal infection in brain. Fungal infections that produce mass effect can present as paresis or paralysis of limbs, hydrocephalus, vomiting and coma. Fungal infections that produce meningitis can produce symptoms like fever, neck stiffness and mental disturbance. Fungal infection can be cerebritis, meningitis, abscess, stroke or infarction. Angioinvasive fungi like *Mucorales* and *Aspergillus* can present with stroke or infarction.(3) Though the radiological presentations of fungal infections are nonspecific, combined study of CT and MRI can help diagnose fungal infections of brain.(4) Advancements in imaging technique have provided access to previously inaccessible sites, thus aiding in diagnosis of these infections.

Aspergillosis is one of the most common CNS fungal infections in HIV negative individuals. These are filamentous fungi that form fruiting bodies in lung. They also form septate filaments of thickness 5 to 10 microns, branching at acute angles. Though culture is the gold standard investigation, newer techniques like polymerase chain reaction (PCR) and in situ hybridization techniques help in diagnosis. It is the most common filamentous fungal infection in transplant recipients who are on calcineurin inhibitors.(5) This is in correlation with the present study in which a posttransplant patient who was on tacrolimus showed *Aspergillus* infection. Because calcineurin inhibitors suppress T cell activity that are important for secretion of cytokines against fungi, these infections are common in transplant recipients. Pitfall in histopathological diagnosis of *Aspergillosis* is its similarity with hyaline septated fungi like *Fusarium*. Culture or PCR can help differentiate between them.(6)

Mucorales genera includes *Mucor*, *Rhizopus*, *Lichtheimia*. These produce infections in neutropenia, diabetes mellitus and iron overload. These have thin walled, sparse septate hyphae of varying thickness that can appear folded. Because culture of *Mucor* does not produce good yield, histopathologic diagnosis plays a vital role. Fungal stains like PAS and GMS stain the hyphae.(6) Further *Mucorales* are the most common filamentous fungal infection in diabetes mellitus.(7) The present study also shows mucormycosis in a patient with type I diabetes mellitus. The factors favouring *Mucor* infection in diabetics include impaired activity of neutrophils, hyperglycemia and decreased release of inflammatory cytokines.(7)

Eumycotic mycetoma is one of the rarest CNS fungal infections. It is caused by *Pseudallescheria boydii* and *Madurella mycetomatis*. This infection occurs from implantation during trauma. Scalp swelling and discharging sinuses are seen. Atypical features without involvement of scalp has been reported in three series before by Hickey et al, Natarajan et al and Kommu et al.(8)(9)(10) this study also shows an atypical presentation of eumycotic mycetoma caused by *Madurella mycetomatis*. The patient had no scalp swelling or discharging sinuses. He had no previous history of such an infection. Routine histopathological examination along with PAS and GMS stains showed the presence of fungal colonies exhibiting Splendore-Hoeppli phenomenon. Fungal infection was not suspected pre or intraoperatively, rather infiltrative meningioma was thought of. This case is fourth in the series to be reported in literature.

Present study is compared with two other studies in Table 4.

	Study in Southern India (2)	Study in Northern India (11)	Present study
Aspergillus	56%	16%	50%
Mucorales	32%	50%	40%
Madurella	0.7%	-	10%
Cryptococcus	1.5%	34%	-
Candida	3.8%	-	-
Pheohyphomycosis	1.5%	-	-
Mixed infection	3.7%	-	-
Miscellaneous	0.8%	-	-

V. Conclusion

The neuroradiological presentation of the fungal infections of the central nervous system is nonspecific. Though culture is the gold standard investigation, in situations when the preoperative suspicion of fungal infection doesn't occur, histopathological examination remains the mainstay in the diagnosis of these infections. Because recurrence is more common with fungal infections and in addition it produces mass effect in brain, early diagnosis and treatment of CNS fungal infections help reduce mortality and morbidity in these patients.

References

- [1]. de Pauw BE. What are fungal infections? *Mediterr J Hematol Infect Dis* [Internet]. 2011 [cited 2019 Feb 21];3(1):e2011001. Available from: <http://www.ncbi.nlm.nih.gov/pubmed/21625304>
- [2]. Sundaram C, Umabala P, Laxmi V, Purohit AK, Prasad VSS V, Panigrahi M, et al. Pathology of fungal infections of the central nervous system: 17 years' experience from Southern India. *Histopathology* [Internet]. 2006 Oct [cited 2019 Feb 21];49(4):396–405. Available from: <http://www.ncbi.nlm.nih.gov/pubmed/16978203>
- [3]. Góralaska K, Blaszkowska J, Dzikowiec M. Neuroinfections caused by fungi. *Infection* [Internet]. 2018 Aug 21 [cited 2019 Jan 22];46(4):443–59. Available from: <http://www.ncbi.nlm.nih.gov/pubmed/29785613>
- [4]. Gavito-Higuera J, Mullins C, Ramos-Duran L, Olivás Chacon C, Hakim N, Palacios E. Fungal Infections of the Central Nervous System: A Pictorial Review. *J Clin Imaging Sci*. 2016;
- [5]. Vazquez JA, Miceli MH, Alangaden G. Invasive fungal infections in transplant recipients. *Therapeutic Advances in Infectious Disease*. 2013.
- [6]. Guarner J, Brandt ME. Histopathologic diagnosis of fungal infections in the 21st century. *Clin Microbiol Rev* [Internet]. 2011 Apr 1 [cited 2019 Feb 21];24(2):247–80. Available from: <http://www.ncbi.nlm.nih.gov/pubmed/21482725>
- [7]. Casqueiro J, Casqueiro J, Alves C. Infections in patients with diabetes mellitus: A review of pathogenesis. *Indian J Endocrinol Metab* [Internet]. 2012 Mar [cited 2019 Feb 22];16 Suppl 1(Suppl1):S27-36. Available from: <http://www.ncbi.nlm.nih.gov/pubmed/22701840>
- [8]. HICKEY BB. Cranial maduramycosis. *Trans R Soc Trop Med Hyg* [Internet]. 1956 Jul [cited 2019 Feb 22];50(4):393–6. Available from: <http://www.ncbi.nlm.nih.gov/pubmed/13360990>
- [9]. Natarajan M, Balakrishnan D, Muthu AK, Arumugham K. Maduromycosis of the brain. *J Neurosurg* [Internet]. 1975 Feb [cited 2019 Feb 22];42(2):229–31. Available from: <http://www.ncbi.nlm.nih.gov/pubmed/1167580>
- [10]. Rao KV, Praveen A, Megha S, Sundaram C, Purohith AK. Atypical craniocerebral eumycetoma: A case report and review of literature. *Asian J Neurosurg* [Internet]. 2015 [cited 2019 Feb 21];10(1):56. Available from: <http://www.ncbi.nlm.nih.gov/pubmed/25767591>
- [11]. Sethi PK, Khanna L, Batra A, Anand I, Sethi NK, Torgovnick J, et al. Central nervous system fungal infections: Observations from a large tertiary hospital in northern India. *Clin Neurol Neurosurg*. 2012;

Dr.T.Jemima Evangelyn. “Cobwebs in the Brain.” *IOSR Journal of Dental and Medical Sciences (IOSR-JDMS)*, vol. 18, no. 6, 2019, pp 36-41.