

Cerebral Hydatidosis: Mustapha Pacha Neurosurgery Department Experience

Atroun.L¹, Habchi.N^{1,2}, Benalleg.S¹, Djafer.M¹

¹(Mustapha Pacha Hospital, Neurosurgery Department, Algiers, Algeria)

¹(FSB-USTHB, Endocrinology Department, Algiers, Algeria)

Abstract: *Introduction:* Cerebral hydatidosis is a rare affection, representing 1 to 4% of the different hydatid localizations in literature.

Materials and methods: Our study concerns 19 cases of cerebral hydatidosis, collected in Mustapha Pasha's neurosurgery department in Algiers for a period of 16 years (from 2000 to 2016).

Results: The average age of patients was 19 years old, with extremes that varies between 1 and 69 years. The most affected age group was 10-19, presenting 42% of the cases (8/19); More common in females and represents 68% of the cases. The average duration of symptoms before diagnosis is 4 months. The clinical signs were dominated by intracranial hypertension associated or not with neurological deficit. Neuro-imaging (CT scan/ MRI) are the key exams. MRI is important especially in the development of surgical planning. Collected radiological data reported 8 multiple cysts (42%) and 11 single cysts (58%). The left parietal location was the most frequent location in our series. All our patients were operated on by the Arana-Iniguez method. Albendazole was used to manage Intraoperative rupture of the hydatid cyst. The evolution was satisfactory for the majority of patients. However, complications such as wound infection, postoperative meningitis, sequential blindness, diplopia, sequential paralysis of the sixth cranial nerve, and diplopia were noted. We deplore the death of a patient presented with Staphylococcal epidermidis meningitis.

Conclusion: The neurological sequelae, sometimes major, reflect the importance of prevention as the only guarantee of a good control of the disease.

Keywords: cerebral hydatid cyst, endemic, age

Date of Submission: 14-06-2019

Date of acceptance: 29-06-2019

I. Introduction

Cerebral hydatidosis or cerebral hydatid cyst (CHC) is a parasitic disease that is endemic in many countries that produces livestock traditionally, including Algeria. [14,39] It can reach any organ with a predilection for the liver and lung, cerebral localization remains relatively rare. In endemic areas, the hydatid cyst deserves a special place among intracranial expansive processes. The prognosis of this cerebral affection is a good subject to early diagnosis and proper therapeutic management. The goal of our work is to establish a well-codified action plan that leads to a better management of our patients for a better life and to limit the economic effects of this condition. Hydatidosis is an endemic disease in the Maghreb (Morocco, Algeria, Tunisia and Libya). [39] 93% of the studies published about hydatidosis in North Africa concerned Tunisia, Morocco and Egypt, with only 7% of the indexed publications concerning the other countries (Algeria, Libya, and Sudan). In Algeria, the prevalence rate of hydatidosis reported by Dar and Alkarmi [14] is 3.4 to 4.6 cases per 100 000 inhabitants, the figures reported by Seimenis in 2003 [32] being 1.8 to 2, 3 cases per 100,000 inhabitants. In Algeria, the ovine strain of *E. granulosus* appears to be the most incriminated in human infection in 2003 [5], although a camelina strain has also been demonstrated, with possible crosses between the different strains. [28]

II. Materials And Methods

We conducted a 16-year retrospective study of the medical records of 19 cases of cerebral hydatid cysts operated at the Neurosurgery Department of the CHU Mustapha BACHA in ALGIERS between January 2000 and December 2016. Different data were collected from medical records of the department. The patients in our series all benefited from either a CT scan without contrast injection or a brain MRI, which allowed to specify the nature of the process, its location, the number of lesions, the density, the size, the presence of hydrocephalus and perilesional edema as well as the impact of the cyst on the surrounding structures. The therapeutic protocol was based on:

Medical treatment: anti-parasitic specific and symptomatic based on the prescription of analgesics in some patients preoperatively to reduce headaches in intracranial hypertension. Postoperative anticonvulsant treatment was instituted in all our patients as a preventive measure.

Surgical treatment: All patients underwent surgical treatment by forced delivery of the cyst using hypertonic saline solution introduced under and around the cyst, according to the ARANA-INIGUEZ technique.

The medical follow-up targeted: The search for postoperative complications and the assessment of clinical signs and evaluate the aftermath of the affection.

III. Results

Our series included 19 KHC cases collected over a 16-years period from January 2000 to December 2016 with an average of 2 cases per year. In our series, the average age of patients is 19 years old varying from 1 to 69 years. The most affected age group was 10-19 years old, it represents 42% of our population (8/19), 9 of our patients were children under the age 15 (47% of cases), while 53% of patients were older than 15; More common in females and represents 68% of the cases. The rural origin was found in all our patients. The evolution of the disease lasted an average of 4 months with extremes ranging from 3 weeks to one year. Most patients consulted more than one month after the first symptoms. Clinically the affection was presented by:

Intracranial Hypertension: In our study, more than 90% of our patients consulted at the ICHT stage, marked by diffuse helmet headaches, associated by jet vomiting and visual disturbances.

Neurological focal signs:

- Motor deficit: 3 cases of hemiplegia and 10 cases of hemiparesis have been reported in our series.
- Cerebellar syndrome: we have identified two cases of statokinetic cerebellar syndrome (PCA)
- Seizures: no case of convulsion has been reported.
- Consciousness disorders: none of our patients has presented an alteration in their consciousness.

Clinical signs	Number of cases	Percentage%
ICHT	17	90
Deficit signs:		
- Hemiplegia	3	15,7
- Hemiparesis	10	52,6
Cranial Nerves' Involvement:		
Exoptalmia	2	10,5
Blindness	2	10,5
Cerebellar ataxia	2	10,5

Table 1: Distribution of clinical signs by number of cases

Neuro-imaging: Patients' CT scan of the brain was able to show a well-defined hypodensity, of rounded or oval shape, large in the majority of cases, with a density close to that of cerebrospinal fluid (CSF) and without enhancement after injection of the contrast product.

Number: Among the 19 patients, in whom brain CT scan was performed, 11 had a single hydatid cyst and only 8 had multiple hydatid cysts.

localisation: Supratentorial location was the most common in our series, with the left side being the most dominant 52.6% (Table 2).

Localisation	Right	Left
Fronto-parietal	2	1
Fronto-temporo-parietal	2	0
Parieto-temporo-occipital	1	2
Frontal	2	1
Parietal	1	3
Occipital	1	1
Cerebellopontine angle	0	2
TOTAL	9	10

Table 2: Distribution of cerebral hydatid cysts by location

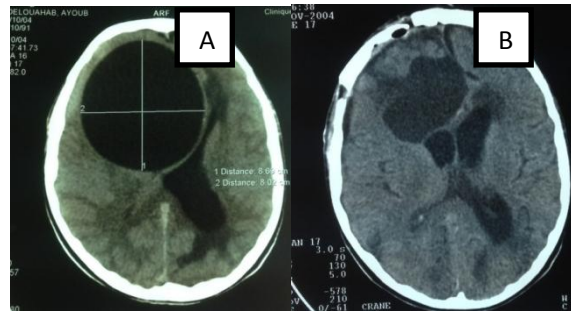


Fig 1: frontal hydatid cyst before (A) and after surgery (B)

The postoperative outcome: was marked by the occurrence of Staphylococcal epidermidis meningitis in 2 patients; one had died, while in the second case, the meningitis was curbed by antibiotic therapy.

Functional rehabilitation: Motor rehabilitation has been proposed for six patients with neurological deficit.

Anatomopathological study: All operative specimens were sent for an anatomopathological examination that confirmed the parasitic origin of the cyst.

IV. Discussion

Hydatidosis is a cosmopolitan condition that is endemic in countries that uses traditional livestock farming. [2,30]The Mediterranean basin currently has one of the world's largest foci of hydatidosis.[23]These regions share several factors that may explain this endemicity, namely the traditional breeding of livestock, the high number of stray dogs and the humidity suitable for the maintenance of embryophores in the external environment, factors which are often added to a defective hygiene.[7]The frequency of CHC is variable according to different studies. The study conducted by ABBASSIOUN (Iran) [1]concerns 69 patients over a period of 35 years, with an average of 1.97 cases / year. That of GUPTA (India) [20]studies the cases of 5 patients collected over 14 years with an average of 0.35 cases/year. KHALDI (Tunisia) [23]reports a higher frequency of 4.5 cases/year. Our series covers 19 cases collected in 16 years with an average of 2 cases per year. Intracranial hydatid disease mainly affects pediatric groups [6,9,10], with an incidence of 50% to 80% of all diagnosed CHC.[17]It occurs more often before the age of 15.[9]TURGUT [36,37]believes that the reason for this predominance is probably due to the fact that this age group is more in contact with dogs than adults. In our series, 9 of the 19 patients were under the age of 15 (47%). In literature, the male sex seems to dominate in hydatid disease compared to the female sex [4,12,30]which is not consistent with our results, where we report a female dominance of 68%. But there is work that shows the predominance of women such as BENBECHER [6]who reports a female predominance: 4 girls had a CHC against only 2 males and TLILI-GRAIESS [16]where 14 patients from 25 of his series were female. In Algeria, Larbaoui and Alloula showed that women were the most affected in two studies.[25]These authors showed that the presence of dogs in the patients' entourage was a significant risk factor in the onset of hydatidosis, ie 74.5% of cases. Hydatidosis is a disease of the rural world. The urban cases described are peasants recently settled in the city or city dwellers who have spent time in the country. For example, ABBASSIOUN [1]reports that 80% of its patients lived in rural areas. In our series, rural origin is found in all our patients (100%). Regardless of the cyst's localization, and despite the importance of its size, the clinical expression is poor. Its growth is slow, so there is a long interval before the appearance of first symptoms.[23]The clinical progression of the disease in adults is faster than in children.[23]The start of Hydatidosis varies both in its manifestations and duration: EL SHAMAM [16]reports a period of time from 2 days to 2 years between the first symptoms and diagnosis with an average of 4 months and 4 days. In the GUPTA [20]series, this period varies from 1 month to 2 years. BRAHEM [9]speaks of duration between 1 and 12 months with an average of 5 months. In the EL ABBASSI-SKALLI [1]series, the period between onset of first symptoms and diagnosis was on average 10 months. In our series, this period varies between 3 weeks and 1 year with an average of 4 months. There is no clinical picture specific to CHC.[31,36]However, ICHT syndrome remains the usual inaugural manifestation of cerebral hydatidosis.[23]ICHT is found in 96% of cases followed by deficit syndrome found in 50 to 77% of cases.[11,16]It is often isolated and well tolerated in children whose skull is quite extensible.[6]In adults, however, the ICHT is poorly tolerated.[9]In our series, all patients consulted with an ICHT syndrome. Neurological Deficit signs are the second most common mode of revelation for CHC. They may be associated with an ICHT syndrome; either directly related to the localization of the cyst or as a consequence of ICHT.[10]EL SHAMAM [16]in a study involving 16 patients reported that 6% had

hemiparesis, 19% had Babinski sign and 6% an exaggeration of osteo-tendinous reflexes. When at GUPTA [19], hemiparesis was the common symptom found in all patients. KHALDI [23] reports a pyramidal syndrome in 71% of his patients. In our series, we report 10 cases of hemiparesis (52.6%) and 3 cases of hemiplegia (15.7%). CHC is rarely located in the posterior fossa. [34] ABBASSIOUN [1] reports 5 cases of cerebellar syndrome (7%); they all had a cerebellar location of the hydatid cyst. KHALDI [23] reports 2 cases of cerebellar syndromes in his series with kinetic disorders (2%). In our series, we received two cases presenting with a cerebellar syndrome, of statokinetic type. This can be explained by the involvement of the cortico-ponto-cerebellar fibers. [24] The involvement of cranial pairs can also be seen during cerebral hydatidosis. [3,5] Some of them are related to the ICHT such as the involvement of the sixth cranial pair and optical pathways responsible for visual disturbances ranging from a simple discomfort of vision to blindness. [5] In our series, among 13 of our patients, two had bilateral blindness (10.5%). CHC develops in the white matter and preferring supra-tentorial localization. The parietal lobe is the most affected, it is the territory of the middle cerebral artery, the largest branch of the internal carotid. [8,38] The left hemisphere is the most affected because of the direct birth of the left common carotid from the aorta. [16] Polylobal involvement was the most observed in our series, always including the parietal lobe, often on the left side. Currently, the only cure for CHC is surgery. [3,4,8,19,21,34,36] It should be considered whenever possible. The combination of medical treatment is indicated in the forms associated with bone localizations, multiple forms, and diffused forms and in case of recurrences. [18,22] Postoperative meningitis is one of the most dangerous complications due the high mortality. ABBASSIOUN [1] reports 3 cases of purulent meningitis in *Escherichia Coli*, all of whom died. In our series, ONE patient died because of *Staphylococcus epidermidis* meningitis.

V. Conclusion

The cerebral location of hydatid cyst is rare and touches especially children in endemic areas; the clinical symptoms are dominated by an ICHT associated or not with a progressing deficit syndrome. Early preoperative diagnosis is capital for surgical success. It is currently better known thanks to neuro-imaging techniques, especially CT scan and MRI. Facing any cyst hydatid cerebral diagnosis, surgical treatment is necessary to avoid complications and neurological aftermath. A prophylactic plan must be imposed and rigorously exercised at all levels of the epidemiological chain to interrupt the parasite cycle, which requires close collaboration between the medical, veterinary and agricultural sectors.

References

- [1]. **ABBASSIOUN-K.; AMIRJAMCHIDI-A.** Diagnosis and Management of Hydatid Cyst of the Central Nervous system: Part1: General considerations and hydatid Disease of the Brain. *Neurosurgery Quarterly*, 2001; 11(1): 1-9.
- [2]. **AIT BENALI S, HILMANI S, CHOUKRI M, SAMI A, EL AZHAR A, ACHOURI M, OUBOUKHLIK A, EL KAMAR A, BOUCETTA M.** Hydatidose cérébrale multiple d'origine cardiaque. A propos d'un cas. *Neurochirurgie*, 1999 ; 45(5) : 426-9.
- [3]. **AKDEMIR G, DAGLIOGLU E, SECEM M ; ERGÜNGÖR MF.** Hydatid cysts of the internal acoustic canal and jugular foramen. *J Clin Neurosci*, 2007; 14(4):394-6.
- [4]. **BALAK N, CAVUMIRZA C, YILDIRIM H, OZDEMIR S, KINAY D.** Microsurgery in the removal of a large cerebral hydatid cyst: technical case report. *Neurosurgery*, 2006; 59(4 Suppl 2).
- [5]. **BARDONNET, K., BENCHEIKH -ELFEGOUN, M.C., PIARROUX R., BART J.M., HARRAGA S., DIA L.M., SCHNEEGANS F, CHOLLET J.Y., BEURDELET A., VUITTON D.A. (2003).** "Cystic echinococcosis in Algeria: cattle act as reservoirs of a sheep strain and may contribute to human contamination". *Veterinary Parasitology*, 116 : 35-44.
- [6]. **BEN BECHER S, CHEOUR M, BEN HASSINE L, HLIOUI S, HOUAS F, GHARAM N, HAMMOU A, BOUDHINA T.** Les kystes hydatiques cérébraux chez l'enfant. *Arch Pédiatr*, 1997; 4: 1107-10.
- [7]. **BEZZARI M, BIGAIGNON G, NACHEGA J, LAASOU K, GIGOT JF, AYADI A.** L'hydatidose: Echinococcosse d'importation en BELGIQUE. *Louvain Med*, 1999 ; 118 : 64-71.
- [8]. **BRAHAM E., BELLIL S., BELLIL K., CHELLY I., MEKNI A., HAOUET S., KCHIR N., KHALDI M.,** Kyste hydatique de la fosse cérébrale postérieure. *Med Mal Infect*, 2007 ; 37: 281-3.
- [9]. **BRAHEM M., HLEL K., AYADI A., BEDOUI A., HMILA F., MAHJOUB B., BOUSSOUFFARA R., SFAR MT.,** Kystes hydatiques cérébraux de l'enfant : à propos de quatre observations. *Med Mal Infect*, 2006; 36(8): 434-7.
- [10]. **BRONSTEIN J A , KLOTZ F. ,** Cestodoses larvaires. *Encycl Méd Chir - maladies infectieuses*, 2005 ; 2 : 59-83.
- [11]. **BÜKTE Y, KEMANOGLU S, NAZAROGLU H, ÖZKAN Ü, CEVIZ A, SIMSEK M.** Cerebral hydatid disease: CT and MR imaging findings. *Swiss Med Wkly*, 2004; 134: 459-67.
- [12]. **CIUREA AV, VASILESCU G, NUTEANU L, CARP N.** Cerebral hydatid cyst in children. Experience of 27 cases. *Childs Nerv Syst*, 1995; 11: 679-686.
- [13]. **CORDOLIANI YS, SARRAZIN JL, LEVEQUE C, GOASDOUE P, SABBAB P.** Imagerie des parasitoses encéphaliques. *J Neuroradiol*, 1998 ; 25: 290-305.
- [14]. **DAR FK, ALKARMI T.** "Public health aspects of cystic echinococcosis in the Arab countries". (1997). *Acta Tropica*, 67 : 125 -31.
- [15]. **DASKAS N, AGGELOPOULOS E, TZOUFI M, KOSTA P, SIAMOPOULOU A, ARGYROPOULOU M.** Accidental drainage of a cerebral hydatid cyst into the peritoneal cavity (brief reports). *Pediatr Infect Dis J*, 2004; 23 (7): 685-6.
- [16]. **EL SHAMAM C, AMER T, ABO EL ATTA M.** Magnetic resonance imaging of simple and infected hydatid cysts of the brain. *Magn Reson Imaging*, 2001; 19: 965-74.
- [17]. **EVLİYA OGLU C, KESKİL S.** Possible spontaneous "birth" of a hydatid cyst into the lateral ventricle. *Childs Nerv Syst*, 2005; 21:425-8.

- [18]. **GAZAZ M, BOUYAAKOUB FA, AKHADDAR A, DERRAZ S, EL KHAMLICH A.** Kyste hydatique extradural de la fosse cérébrale postérieure. Neurochirurgie, 2000 ; 46(4) : 387-90
- [19]. **GOASGUN J, BEQUET D.** Parasitologie du système nerveux central. EncyclMédChir Neurologie, Editions techniques, 1991 ; n°17052.
- [20]. **GUPTA S, DESAI K, GOEL A.** Intracranial hydatid cyst a report of five cases and review of literature. Neurol India, 1999 ; 47(3) : 214-7.
- [21]. **IYIGUN O, UYSAL S, SANCAK R, HOKELEK M, UYAR Y, BERNAY F, ARITURK E** Multiple Organ Involvement Hydatid Cysts in a 2-year-old Boy. J Trop Pediatr, 2004; 50(6):374-6.
- [22]. **KALAITZOGLOU I, DREVELENGAS A, PETRIDIS A, PALLADAS P.** Albendazole treatment of cerebral hydatid disease: evaluation of results with CT and MRI. Neuroradiology, 1998; 40: 36-9.
- [23]. **KHALDI M, MOHAMED S, KALLEL J, KHOUJA N.** Brain hydatidosis : report on 117 cases. Childs NervSyst , 2000; 16 : 765-9.
- [24]. **KLOTZ F, NICOLAS X, DEBONNE JM, GARCIA JF, ANDREU JM.** Kystes hydatiques du foie. EncyclMédChir hépatologie, 2000 ; 7-023-A-10 : 16.
- [25]. **LAMMAT E.** Kyste hydatique encéphalique à l'hôpital IBN TOFAIL de Marrakech. Thèse Méd Casablanca, 1998 ; n°109.
- [26]. **LARBAOUI D, ALLOULA R, (1979).** «Étude épidémiologique de l'hydatidose en Algérie: Résultat de deux enquêtes rétrospectives portant sur 10 ans». La Tunisie Médicale,6: 318-326.
- [27]. **Llanes EG D.V., STIBAL A, MÜHLETHALER K, VAJTAI I, HÄUSLER R, CAVERSACCIO M.** Echinococcosis presenting as an otogenic brain abscess: An unusual lesion of the middle ear cleft and temporal lobe. AurisNasus Larynx 2007, 35 (1) : 115-20.
- [28]. **MAILLARD, S.,BENCHIKH-ELFEGOUN, M.C.,KNAPP, J., BART, J.M., KOSKEL, P., GOTTSTEIN, B.,PIARROUX, R. (2007).** "Taxonomic position and geographical distribution of the common sheep G1 and camel G6 strains of Echinococcusgranulosus in three African countries".Parasitol Res,100: 495-503.
- [29]. **MENKÜ A, KULAKSIZOGLU O, TUCER B, KURTISOY A, AKDEMIR H.** Successful surgical excision of a gigantic cerebral hydatid cyst. MinimInvasNeurosurg, 2000; 47: 61-4.
- [30]. **ROBERT-GANGNEUX F, TOURTE-SCHAEFER C.** Valeur comparée de deux techniques de Western-blot pour le diagnostic de confirmation d'une hydatidose. Parasitologie, 1998, Manuscrit n°1991.
- [31]. **SAHIN-AKYAR G.** Computed tomography and magnetic resonance imaging findings in cerebral hydatid disease. Radiography, 2002; 8: 251-8.
- [32]. **SEIMENIS, A. (2003).** "Overview of the epidemiological situation on echinococcosis in the mediterranean region". ActaTropica, 85: 191-195.
- [33]. **SENTURK S, OGUZ KK, SOYLEMEZOGLU F, INCI S** Cerebral Alveolar Echinococcosis Mimicking Primary Brain Tumor. Am J Neuroradiol, 2006; 27: 420-2.
- [34]. **TALAN-HRANILOVIC J, SAJKO T, NEGOVETIC L, LUPRET V, KALOUSEK M .**Cerebral Cysticercosis and Echinococcus is: a Preoperative Diagnostic Dilemma Arch Med Res, 2002; 33: 590-4.
- [35]. **TSIDOURIS J, DIMITRIADIS AS, KAZANA E. MR** in Cisternal Hydatid Cysts. Am J Neuroradiol, 1997; 18: 1586-7.
- [36]. **TURGUT M.**Hydatidosis of central nervous system and its coverings in the pediatric and adolescent age groups in Turkey during the last century: a critical review of 137 cases.ChildsNervSyst, 2002; 18: 670-83.
- [37]. **TURGUT AT.** Magnetic resonance imaging of hydatid cysts of the brain (letter to the editor). MagnReson Imaging, 2004; 22: 1339-40.
- [38]. **TURGUT AT, ALTIN L, TOPCU S, KILICOGLU B, ALTINOK T, KAPTANOGLU E, KARADEMIR A, KOSAR U.** Unusual imaging characteristics of complicated hydatid disease. Eur J Radiol, 2007 ; 63(1): 84-93
- [39]. **TURGUT M.** Intracranial hydatidosis in Turkey : its clinical presentation, diagnostic studies, surgical management, and outcome. A review of 276 cases. NeurosurgRev, 2001; 24 (4): 200-8.
- [40]. **YENA, S., SANOGO, Z.Z., KEÏTA, A., SANGARE, D., SIDIBE, S., DELAYE, A., DOUMBIA, D., DIALLO, A. SOUMARE, S. (2002).**«La chirurgie du kyste hydatique pulmonaire au Mali». Ann Chir,127: 350-355.
- [41]. **YURT A, AVCI M, SELCUKI, ÖZER F, CAMLAR M, UCAR K, TASLI F, ALTINÖRS N.** Multiple cerebral hydatid cysts. Report of a case with 24 pieces. ClinNeurolNeurosurg, 2007; 109: 821-6.

Atroun.L. " Cerebral Hydatidosis: Mustapha Pacha Neurosurgery Department Experience."
IOSR Journal of Dental and Medical Sciences (IOSR-JDMS), vol. 18, no. 6, 2019, pp 64-68.