

Foley's In Ureter-An Unfortunate Bull's Eye: A Rare Case Report

Dr. Avinash Kaul¹, Dr. Kalpit Goriwal², Dr. Sandeep Singh³,
Dr. Harshit Malhotra⁴, Dr. Kanika Sharma⁵

¹M.S (GENERAL SURGERY)

²DNB General Surgery

³M.S (GENERAL SURGERY)

⁴DNB General Surgery

⁵M.S (GENERAL SURGERY)

Corresponding Author: DrKalpitGoriwal

M.S. Office Indraprastha Apollo Hospitals SaritaVihar New Delhi 110076 India

Abstract:

INTRODUCTION: Foley's Catheter is currently the mainstay as far urinary bladder drainage is concerned. Being a blind procedure, at times it is associated with injuries of the part of urinary tract it traverses, most common being urethra. Rarest of the rare foley's catheter associated injuries is inadvertent ureteral injury. Only isolated cases have been reported.

PRESENTATION OF A CASE: A 46 year old gentleman, a known case of pan urethral stricture, contracted bladder presented to the ER of our institute with the chief complaint of severe pain abdomen following foley's catheterisation. On evaluation, it was discovered that the foley's catheter had entered left ureteric orifice and the inflated balloon was in the distal left ureter. Patient was managed with left DJ stent placement. Recovery was uneventful.

DISCUSSION: Although ureteric injury with foley's catheter is rare but a problematic one. Symptomatology spectrum is a varied one. CT scan – KUB region will confirm the diagnosis. Management will depend on the extent of injury and is chiefly aimed at splinting the injury.

CONCLUSION: Ureteric injuries with inadvertent foley's catheterisation is a rare entity and requires prompt diagnosis and management. If apt management is offered in apt time, an uneventful recovery should be expected.

Keywords: ureteral foley's, foley's related injuries, inadvertent ureteral catheterisation, ureteral injury

Date of Submission: 06-06-2019

Date of acceptance: 21-06-2019

I. Introduction

Ureteral Injury: [Perforation/Transection/Avulsion/False Passage...]^[1,2]

- A) EXTERNAL TRAUMA)
- B) IATROGENIC : (>90 % in distal ureter)
 - i) Urological Procedures [42 %]
 - ii) Gynecological Procedures [34 %]
 - iii) General Surgical Procedures [24 %]

The two most common complications of Foley catheter placement are urethral trauma and retention of the Foley balloon in the urethra^[3]. Inadvertent placement of a Foley balloon within the ureter is a rare complication of urethral catheterization, with only few cases reported in the medical literature^[1,4-11].

STUDY	AGE	GENDER	URETER AFFECTED	1° PATHOLOGY
Singh et al ^[5]	26	F	Right	Paraplegia
Ogan et al ^[6]	47	F	Right	-
Muneer et al ^[7]	77	F	Right	Fibrotic bladder
Kim et al ^[8]	38	F	Right	Paraplegia
Papacharalabous et al ^[9]	68	F	Left	Iatrogenic (during laparotomy)
Hara et al ^[10]	51	F	Left	Iatrogenic (during laparotomy)
Kato ^[11]	74	F	Left	Chronic indwelling catheter
Baker et al ^[11]	59	F	Left	Multiple sclerosis
Greenlund et al ^[4]	48	F	Right	Quadriplegia
Greenlund et al ^[4]	69	M	Right	Quadriplegia
Locherback et al ^[12]	64	F	Left	Iatrogenic (ureterorenoscopy)

Table-1 Consolidation of Literature*

*adopted from Greenlund et al ^[4]

Clinical picture in such patients can be varied depending on various factors such as volume of saline used to inflate the bulb of the foley's, existing calibre of the ureter, comorbidities, mode of injury and many more.

These patients can present with an array of clinical symptomatology which includes, but is not limited to, :

- a) Asymptomatic and discovered incidentally on imaging or intraoperatively. ^[5,9]
- b) Ascites in the setting of persistent urinary leakage. ^[10,11]
- c) Groin pain ^[7]
- d) Back pain ^[10]
- e) Peritonitis
- f) Clinical picture of urosepsis
- g) Hydroureteronephrosis

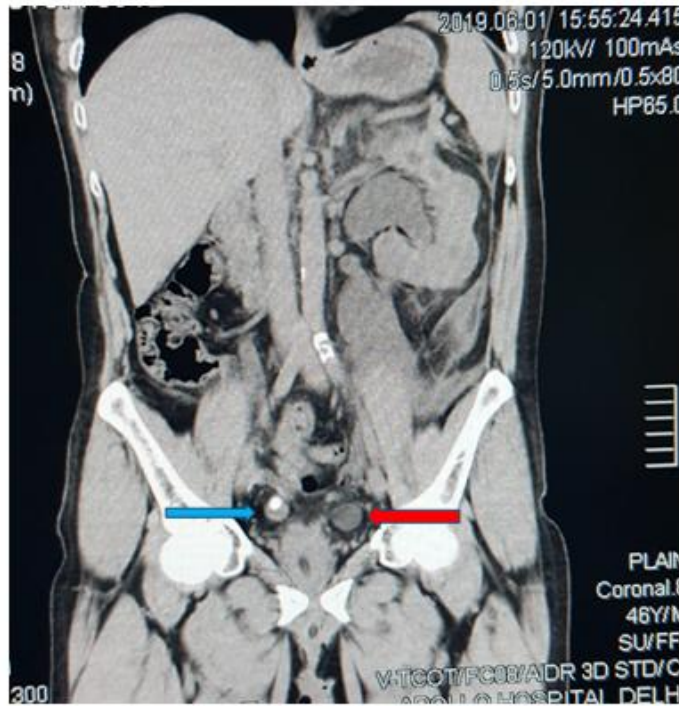
Diagnosis requires a high index of suspicion and aid of imaging modalities. Foley's bulb can be visualised with Ultrasound but the inherent issue being operator dependency. Foley's bulb is visualised clearly with a CT scan of the KUB region. The bulb will be imaged as a spherical fluid filled structure with attenuation similar to that of water, along the expected normal course of ureter. ^[1] CT scan will additionally provide details about the segment of ureter compromised, extent of hydroureteronephrosis and much more.

Majority of the reports on the issue have advocated removing the foley's catheter and have a drainage procedure to aid in the healing of disrupted segment of ureter. These can range from a Double J stent to a formal radiological guided Per cutaneous Nephrostomy. ^[1,4-12]

II. Case Report

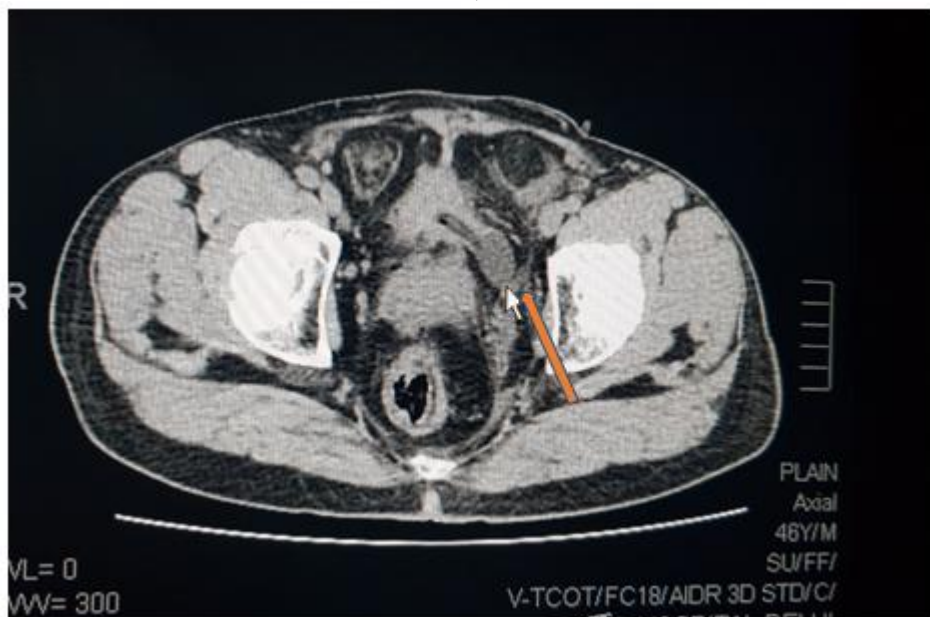
A 46 year old gentleman, a known case of pan urethral stricture, contracted bladder presented to the ER of our institute with the chief complaint of severe pain abdomen following foley's catheterisation. Patient presented to us with foley's catheter in situ. Clinical examination was unremarkable and there were no signs of peritonitis. Blood investigations demonstrated an elevated level of serum creatinine (8.2mg/dl). Patient was evaluated with imaging modalities. USG-KUB region demonstrated Hydroureteronephrosis on left side with a grossly dilated pelvi-calyceal system. CT scan – KUB region demonstrated an atrophic right kidney with an obstructing calculus in the distal right ureter and multiple calculi in the pelvi-calyceal system. Foley's catheter was seen traversing contracted urinary bladder and inflated bulb was visualised in distal left ureter. No gross collection was noted in the peritoneal cavity. In view of elevated serum creatinine, patient underwent hemodialysis as a part of pre operative optimization. Foley's catheter was removed and patient taken up for the procedure. Intraoperatively no gross injury of ureter was noted. Patient underwent Double J stenting on left side. Post operatively patient's clinical profile improved and serum creatinine levels returned to normal levels. Patient was discharged in stable condition with a plan of DJ stent removal after 6 weeks and definitive management of pan urethral stricture in later stages of management.

A)



Blue arrow: obstructive calculus (right side)
Red arrow: foley's bulb (left side)

B)



Arrow: foley's catheter (distal part) with inflated bulb in left ureter

III. Discussion

Injuries of the ureter have a varied etiological array, although Iatrogenic injuries lead the lot. Urological interventions are by far the most common etiological associations. Injuries of ureter need prompt identification and management. Despite urgent redressal, these injuries are notorious in view of high incidence of stricture formation.

Of the various etiological associations, inadvertent trauma due to bulb of Foley's catheter is by far the least common and the most unfortunate one. It typically involves the distal ureter. Although a patulous ureter seems a lucrative accused, it has been implicated in only one previous case report; ours happens to be the second.

Small contracted urinary bladders are more prone due to the obvious proximity of the ureteric orifices to the bladder outlet.

Our patient had a combination of contracted urinary bladder and patulous left ureter, which for obvious reasons seems a multiplicative or at least an additive causation.

CT scan-KUB region seems a safe and a more objective diagnostic tool and tracing the foley's catheter from penile urethra toward the balloon end gives a picture beyond all elements of doubt.

Management, as per majority of case reports (including ours) and in accordance with basic principles of ureteric trauma, should Centre at splinting ureteric injury for partial tears and avulsions; and operative repairs for complete transections.

IV. Conclusion

Ureteric injuries due to foley's bulb are more unfortunate than iatrogenic. Our case report and review of literature shouts out loud to be a little extra cautious in patients with known urological issues, in view of high chances of underlying altered anatomy.

These injuries are not entirely avoidable but caution should be observed while inflating the bulb of foley's catheter. If free flow of urine, in case of a full urinary bladder, is not obtained or resistance is felt while inflating the balloon, an element of suspicion should be duly addressed.

Sometimes foley's may be on an ego trip and an iconic phrase by author **Ayn Rand** aptly describes this egoist bulb in ureters:

*“The question is not who's going to allow me in;
The question is : WHO'S GOING TO STOP ME!”*

References

- [1]. Kevin S Baker, B. D. (2013). Ureteral rupture from aberrant Foley catheter. *Genitourinary Radiology*, 33-40.
- [2]. Selzman AA, S. J. (1996). Iatrogenic ureteral injuries: a 20-year experience in treating 165 injuries. *J Urol*, 878-88.
- [3]. St Luce S, Ninan AC, Hall JA, Kimberl II, Petros JA, Issa MM. Role of transrectal ultrasonography in diagnosis and treatment of retained Foley catheter. *Urology*. May 2005;65(5):1001.
- [4]. Bradley W. Anderson, Andrew C. Greenlund. Ureteral Cannulation as a Complication of Urethral Catheterization. *Korean J Urol* 2014;55:768-771.
- [5]. Singh NP, Eardley I. An uncommon complication of urethral catheterization. *Br J Urol* 1996;77:316-7.
- [6]. Ogan K, Berger RM. Aberrant Foley catheter placement into the proximal right ureter. *BJU Int* 2001;88:124.
- [7]. Muneer A, Minhas S, Harrison SC. Aberrant Foley catheter placement into the proximal right ureter. *BJU Int* 2002;89:795.
- [8]. Kim MK, Park K. Unusual complication of urethral catheterization: a case report. *J Korean Med Sci* 2008;23:161-2.
- [9]. Papacharalabous E, Ford M, Butler-Manuel S, Tailor A. Inadvertent insertion of a Foley's catheter through the orifice of a duplex ureter during catheterisation for laparotomy. *GynecolSurg* 2011;8:99-101.
- [10]. Hara N, Koike H, Bilim V, Takahashi K. Placement of a urethral catheter into the ureter: An unexpected complication after retropubic suspension. *Int J Urol* 2005;12:217-9.
- [11]. Kato H. Incorrect positioning of an indwelling urethral catheter in the ureter. *Int J Urol* 1997;4:417-8.
- [12]. F. Löcherbach , P. Grimsehl, A. Sauer, S.Wyler, andM. Kwiatkowski. Ureteral Rupture Caused by Accidental Intubation of the Ureterwith a Foley-Catheter during Ureterorenoscopy.HindawiCas rep in uro. 2018. pp 1-3.

DrKalpitGoriwal. "Foley's In Ureter-An Unfortunate Bull's Eye: A Rare Case Report." IOSR Journal of Dental and Medical Sciences (IOSR-JDMS), vol. 18, no. 6, 2019, pp 35-38.