

Rhinolith in an Adult – A Rare Presentation

Dr. Vivek Kumar Pathak⁽¹⁾, Dr. Himani Sharma⁽²⁾, Dr. Rohit Chaudhary⁽³⁾

¹Assistant Professor Department of otorhinolaryngology, SMS&R, Sharda University, Greater Noida, U.P.

²JR-2 Department of otorhinolaryngology, SMS&R, Sharda University, Greater Noida, U.P.

³JR-1 Department of otorhinolaryngology, SMS&R, Sharda University, Greater Noida, U.P.

Corresponding author: Dr. Vivek Kumar Pathak

Date of Submission: 01-06-2019

Date of acceptance: 17-06-2019

I. Introduction

Rhinoliths are rare entity in adults. They are calcareous concretions that are formed by the deposition of salts on an intranasal foreign body found as a chance finding (1-3). Nasal foreign bodies can either be endogenous or exogenous presented as progressive unilateral nasal obstruction, rhinorrhea & epistaxis. Surgical removal is treatment of choice. We are reporting a case rhinolith in nasal cavity in an adult patient which is a rarity (1-3).

II. Case Report

A case of 45 year old male, came to ENT OPD with complaints of prolonged foul smelling nasal discharge associated with progressive unilateral nasal obstruction since last 1 year. Also having complaint of right ear discharge since last 7 months which was profuse purulent, non foul smelling, not blood stained. Patient also gave history of 2-3 episodes of epistaxis in last 3 months. On routine anterior rhinoscopy whitish mass seen in floor of right nasal cavity with irregular surface which was non tender and feels stony hard on probing. Diagnostic nasal endoscopy was done to confirm the diagnosis in which whitish, irregular mass seen extended upto choana and collection of purulent discharge seen in right maxillary, ethmoid and sphenoid sinuses.

NCCT PNS was advised which revealed a hyperdense irregular mass seen in right ethmoid sinus and mucosal thickening in right maxillary, ethmoid sinuses suggestive of Rhinolith. (FIG 1 & 2)

Under general anaesthesia, the nasal cavities were inspected by 0 degree nasal rigid endoscope. A rhinolith was found lying impacted between the inferior turbinate and septum in the middle of the right nasal cavity. It was mobilised and removed in pieces.

The specimen measured approximately 5cm * 3cm with irregular shape and rough surface. (FIG 3 & 4).

III. Discussion

Rhinolith should always be considered of a differential diagnosis in a patient presenting with foul smelling, unilateral nasal discharge. Anterior rhinoscopy, Diagnostic nasal endoscopy, NCCT PNS should be carried out to reach the diagnosis and planning of surgery.

Differential diagnosis are calcifying angiofibroma, calcifying polyps, chondrosarcoma, chondroma and osteosarcoma.

IV. Conclusion

• Although Rhinoliths are rare clinical entity, attending clinicians should be aware of this entity. It requires a high degree of suspicion when dealing with nasal symptoms such as progressive unilateral nasal obstruction, rhinorrhea, cacosmia and unilateral nasal bleeding.

References

- [1]. Brehmer D and Riemann R. The rhinolith - a possible differential diagnosis of a unilateral nasal obstruction. Case rep med 2010 Jun; 1-8.
- [2]. Shah FA, George S and Reghunandan N. A case presentation of a large rhinolith. Oman Med J. 2010 Jul; 25(3):230-1.
- [3]. Yaroko AA, Mohamad I, Hashim HZ. Rhinolith: an important cause of foul smelling nasal discharge. Malays Fam Physician 2014 Apr; 9(1):30-2.

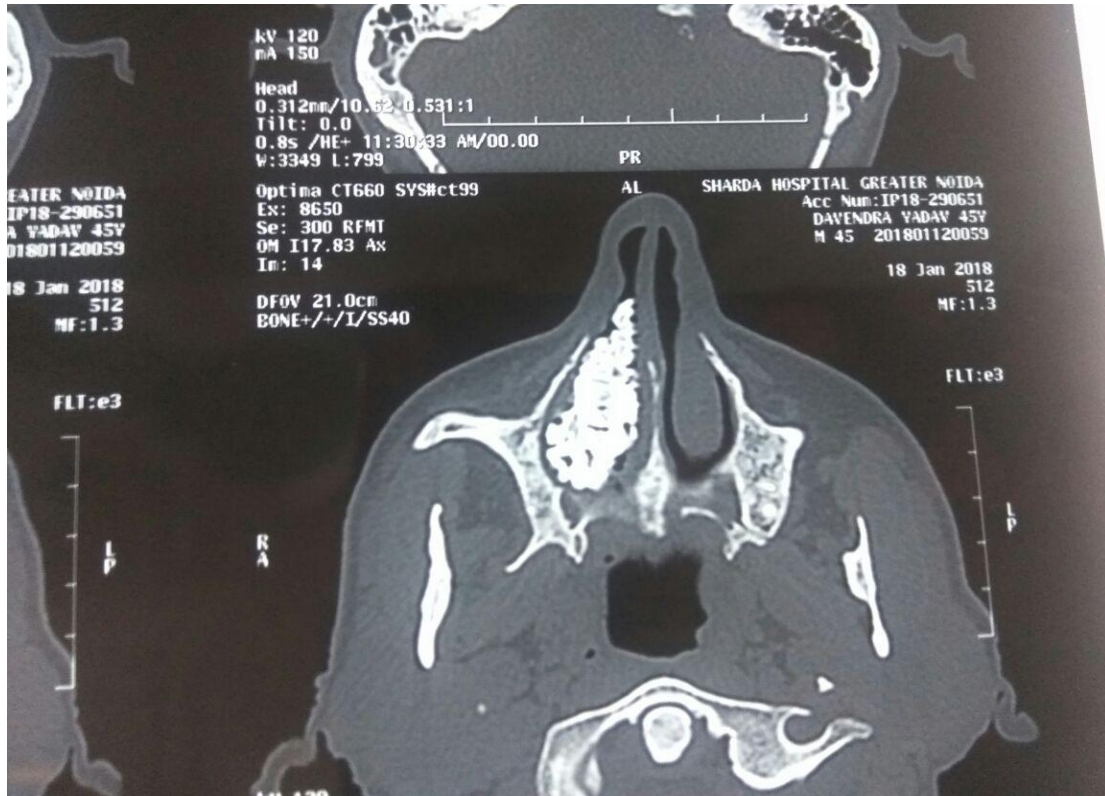


FIG 1: NCCT NOSE AND PNS AXIAL VIEW SHOWING HYPERDENSE CALCIFIED MASS WITH IRREGULAR SURFACE IN RT . NASAL CAVITY

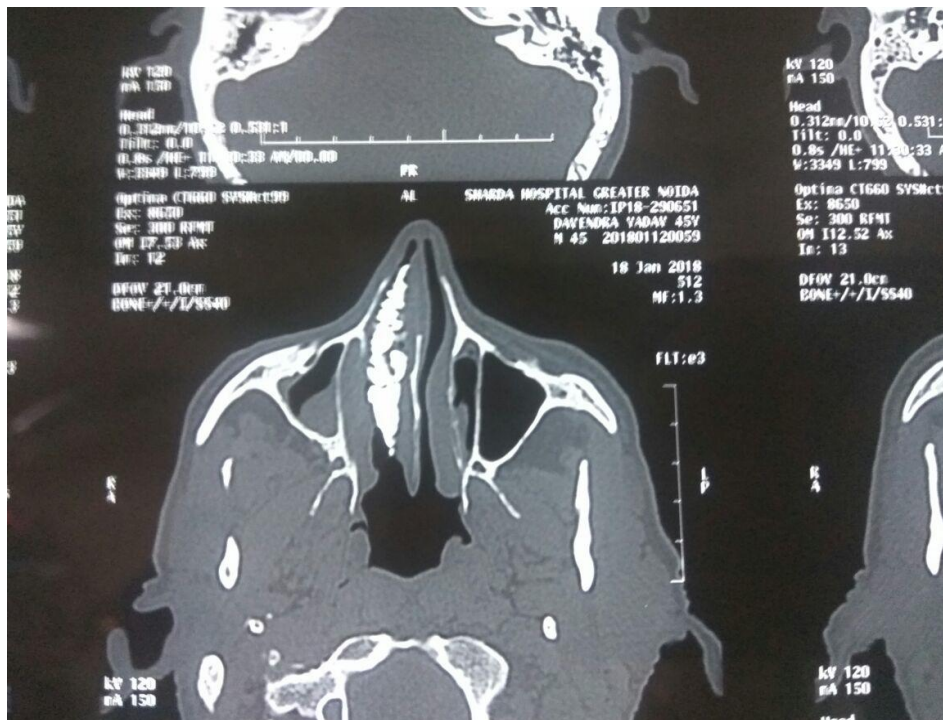

FIG 2: NCCT NOSE AND PNS CORONAL VIEW SHOWING HYPERDENSE MASS IN RT. NASAL CAVITY WITH SECRETIONS IN RT. MAXILLARY SINUS

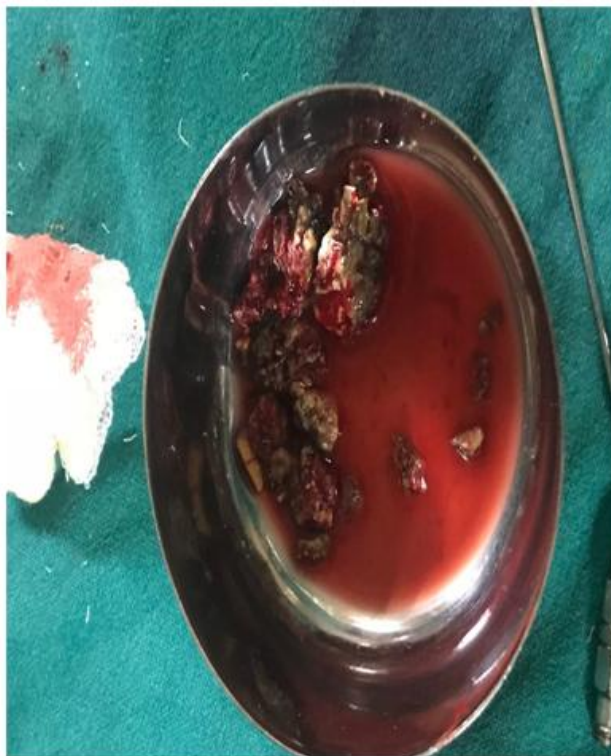


FIG 3: INTRA-OPERATIVE PICTURE SHOWING REMOVED RHINOLITH

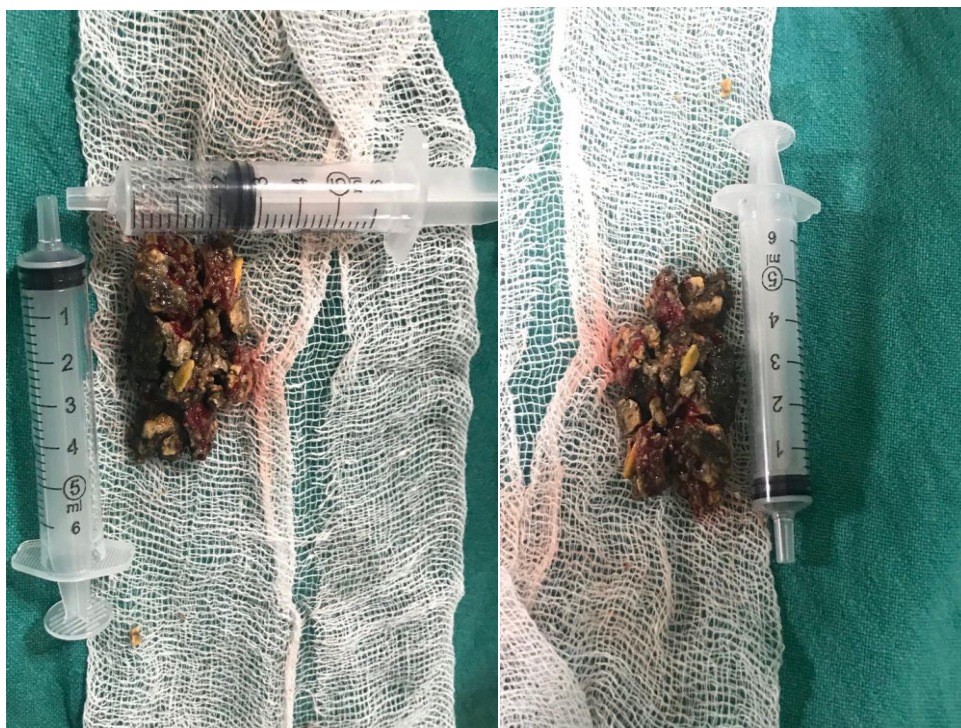


FIG 4 : INTRAOPERATIVE PICTURE SHOWING REMOVED MASSIVE RHINOLITH APPROX. 5CM X 3 CM .

Dr. Vivek kumar Pathak. "Rhinolith in an Adult – A Rare Presentation." IOSR Journal of Dental and Medical Sciences (IOSR-JDMS), vol. 18, no. 6, 2019, pp 37-39.