

## Implant Supported Overdenture: A Viable Treatment Option for Edentulous Patient

Dr Manu verma<sup>1</sup>, Dr brajendradubey<sup>2</sup>, Poonam Agrawal<sup>3</sup>

<sup>1</sup>Senior lecturer chhattisgarh dental college and research institute Rajnandgaon Chhattisgarh

<sup>2</sup>Senior lecturer, vananchal dental college and hospital garwa Jharkhand

<sup>3</sup>3 rd year PG student chhattisgarh dental college and research institute Rajnandgaon Chhattisgarh

Corresponding Author: Dr Manu verma

---

**Abstract:** The prosthetic management of the edentulous patient has long been a major challenge. Complete maxillary and mandibular dentures have been the traditional standard of care. However, most of the patients report problems adapting to their mandibular denture due to a lack of comfort, retention, stability and inability to masticate. Implant-supported overdentures have been a common treatment for edentulous patients for the past 20 years and predictably achieve good clinical results. Implant supported overdentures offer many practical advantages over conventional complete dentures and removable partial dentures. These include decreased bone resorption, reduced prosthesis movement, better esthetics, improved tooth position, better occlusion, increased occlusal function and maintenance of the occlusal vertical dimension. This article presents a design and fabrication technique of the implant-retained overdenture that uses four freestanding mandibular and maxillary implants.

---

Date of Submission: 01-06-2019

Date of acceptance: 17-06-2019

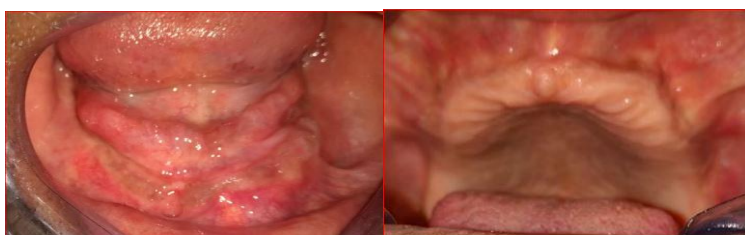---

### I. Case report

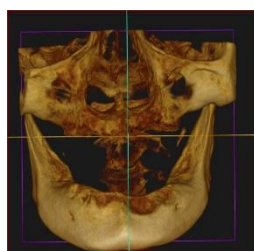
A 67-year-old male patient reported for the prosthodontic rehabilitation of his edentulous jaws. The chief complaint of the patient was difficulty in chewing and poor esthetics. Past medical history was not significant. His dental history included extraction of the periodontally involved teeth 5-6 month before. Clinical examination included an evaluation of size and shape of the edentulous ridge, palpation for undercut and an assessment of condition of the mucosa. Clinical examination revealed completely healed maxillary and mandibular edentulous ridges [Fig-1]. Mandibular ridge exhibited a moderate degree of alveolar ridge resorption in posterior region. Overlying mucosa was healthy and normal. Temporomandibular joint examination was found to be normal. CBCT (cone beam computed tomography) was advised to evaluate bone availability and architecture [Fig-2]. The inter-ridge distance was assessed. Routine blood examination revealed no abnormal findings. A treatment plan was prepared after a standard protocol. It included fabrication of a 2 implant supported overdenture for the maxillary arch and a 2- free standing implant-supported overdenture for the mandibular arch. Position B, D were selected for implant placement [1]. This decision was taken considering the resorption of the posterior region. This treatment plan was explained to the patient and was approved by him.

**Treatment procedure:** Maxillary and mandibular dentures were fabricated in conventional manner. Bilateral balanced occlusal scheme was selected. Deflecting contacts in both centric and dynamic parafunction were eliminated. Patient was instructed regarding the maintenance at the time of denture insertion. The denture was duplicated in a 2-part top and bottom poly vinyl siloxane (ReprosilTMDentsply) using clear auto-polymerized acrylic resin (DPI self cured Acrylic resin, Clear). This was used as a surgical template. The desired implant location was marked on the duplicate denture and stone cast. Corresponding implant position and angulations were marked on the surgical template with an indelible ink pencil. Vertical space analysis of the denture was performed. Equinox myriad implants of 11 mm length and 3.8 mm diameter was selected for mandibular arch and 4.5 mm diameter and 9.5 mm length for maxillary arch was selected. It was decided to use locator. Implant surgery included alveolar ridge reduction and placement of the implants with the help of a surgical template (duplicate denture). Implant surgery was carried out in a 2-stage surgical protocol. Surgery was performed under local anesthesia. The osteotomy sites were prepared in the B, D region with the help of surgical template. A guide pin was used to ensure that the second implant was as parallel as possible to the first. The selected implants were placed at the prepared sites. Surgical cover screws were placed [Fig 3]. The flaps were approximated with primary closure. The patient was told not to wear the lower denture for two weeks following surgery. Antibiotics were prescribed for seven days. Patient was advised to use disinfectant mouth rinse (chlorhexidine) 3-5 times daily. Instructions were given regarding oral hygiene maintenance. The sutures were

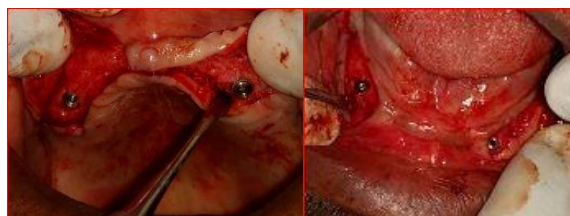removed in two weeks. Dietary restrictions were lifted after 2 weeks of implant placement. The intaglio surface of the denture was relieved. Soft tissue conditioning material (GC Reline Soft TM) was applied to the intaglio surface of the denture according to the manufacturer's directions and the excess liner material was trimmed. The denture was finished, polished and inserted into the patient's mouth. This allowed the patient to wear the removable prosthesis during the period of osseointegration without transmitting excessive forces to the surgical sites. The patient was seen on a regular follow-up visits and the denture was relined as needed. Three months later and after confirmation of the osseointegration, the patient was presented for the second stage surgery. At this stage, the implants were exposed, the surgical cover screws were removed and the sites were irrigated with sterile normal saline (Normal saline Flush). Healing collars were placed, and the gingival tissues were allowed to mature for one month. Mandibular denture was relined with a soft-tissue conditioning material (GC Reline Soft TM). After one month, the comfort and fit of the dentures was checked before proceeding with the addition of attachments. Locator over-denture abutment of 2 mm diameter was selected. Seating of the abutments was verified [Fig 4]. The attachments were placed and O rings were blocked-out on the abutments. Acrylic resin from the intaglio surface of the denture was removed to allow passive fit of the denture against the tissue. Pressure indicating paste (Mizzy Prestige Dental Products) was used to verify that no contact of the denture base with abutment or attachment. A No. six round bur was used to vent the pick up space toward the surface of the denture. The vent was situated lingual to the denture teeth. The pick-up space was half filled with CG Pattern Resin and the mandibular denture was placed over the abutments. The complete seating of the denture was verified and the patient was asked to maintain light occlusal pressure in the centric relation position while the resin polymerizes. The pick-up resin was trimmed and polished in the venting area. Fit and occlusion of the dentures was rechecked in centric relation position. Centric relation records were obtained and a laboratory remount for final occlusal refinement was done [Fig-5, 6, 7]. Home care instructions were given to the patient. The patient was trained to place and remove the prosthesis properly. First recall was attended after 24 hours. The regular follow up was advised every six months. Patient was instructed to remove their prosthesis at night. A soft single-tufted brush was indicated to keep attachments free from plaque and calculus. The patient is successfully using the overdenture since two years and is satisfied with it.



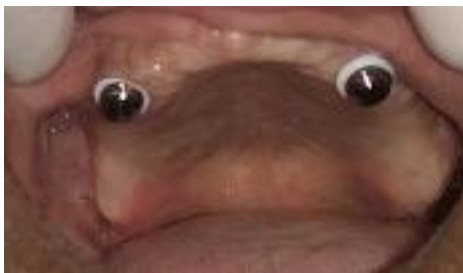**Fig 1-** Edentulous maxillary and mandibular arch



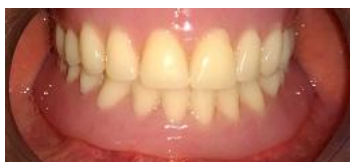**Fig 2-** CBCT



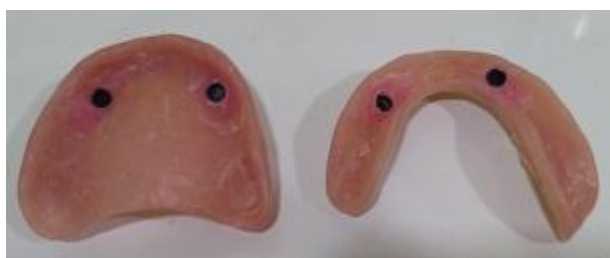**Fig 3-** Implant placement in maxillary and mandibular arch



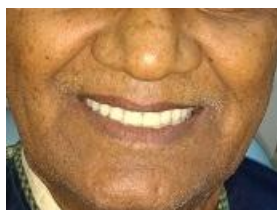**Fig 4-** Locator



**Fig 5-** complete denture



**Fig 6-** Final overdenture (intaglio surface)



**Fig 7-** Extra oral view

## **II. Discussion**

The implant-supported overdenture remains in place during mandibular movements which allows the tongue and perioral musculature to resume a more normal function since they are not required to control mandibular denture movements [2-5].

The design of the implant-retained overdenture can be carried out in 2 ways [2,3,6]. In the first approach, implants are splinted with a rigid interconnecting bar that incorporates an attachment mechanism for the overdenture retention. In the other approach, implants are not connected to each other, and the retention mechanism is provided by an abutment that incorporates some form of retentive mechanism. A major advantage of the freestanding implants is the fact that they allow for the use of the prefabricated stock retentive abutments. The use of the interconnecting implant bar requires additional laboratory and clinical procedures for its fabrication and the associated increase in treatment cost. However, in case of the misaligned or malpositioned implants, stock abutments may not provide the desired compensation, and the splinting of the implants with the interconnecting bar can overcome these problems. Another advantage of the prefabricated stock abutments is that the abutment itself can be easily replaced in case of abutment failure. Because stock abutments are identical, their replacement does not require remaking the overdenture. On the other hand, if the implant interconnecting bar has to be remade in the case of failure, it usually requires remaking the overdenture. Performance data of the implant-retained overdenture indicate that most of the complications and prosthodontic maintenance are related to the attachment components of the overdenture [3,7-9].

Another dilemma associated with overdenture treatment is the technique of incorporating the attachment matrices into the overdenture literature. One approach includes incorporation of the matrices into the overdenture in the dental laboratory. This is an extremely important step and, if not performed correctly, can negatively influence overdenture fit or contribute to the dislodgement of the matrix from the overdenture. This

method ensures acceptable fit of the overdenture. However, it requires additional clinical time and is technique sensitive. The other approach is pick-up intraorally in the clinic [9-12]. In this case four free standing implants were placed in B,D position of maxillary and mandibular arch. Due to financial constraints the patient was not ready for the fixed type of restoration immediately. The same implants can be used for the fixed restoration in future after placing some additional implants.

As with any treatment modality, aftercare and maintenance is vital if the overdenture is to be successful. The patient must be advised of this and reviewed regularly. Optimal surgical implant positioning is essential for the success of implant supported restorations. An implant-retained overdenture requires meticulous treatment planning than a conventional complete denture. Final placement of the implants should follow the principles of ideal implant parallelism and maximum initial stabilization, and path of placement and removal.

### **III. Conclusion**

Restoration of the edentulous arch is a challenge specially the mandibular arch. Among different treatment options, an implant-retained overdenture is a simple, cost effective solution in the rehabilitation of the edentulous mandible. Despite widespread acceptance of this treatment, some controversies still exist with regard to the design of the overdenture, selection of the appropriate attachment system, and the most optimal techniques for the overdenture fabrication. Clinicians and dental technicians have to adhere to sound design principles such as simplicity in fabrication, ease of maintenance and repair and cost control.

### **References**

- [1]. Naert I, Alsaadi G, van Steenberghe D, et al. A 10-year randomized clinical trial on the influence of splinted and unsplinted oral implants retaining mandibular overdentures: peri-implant outcome. *Int J Oral Maxillofac Implants*. 2004;19:695- 702.
- [2]. Naert I, Alsaadi G, Quirynen M. Prosthetic aspects and patient satisfaction with two-implant-retained mandibular overdentures: a 10-year randomized clinical study. *Int J Prosthodont*. 2004;17:401-10.
- [3]. Timmerman R, Stoker GT, Wismeijer D, et al. An eight-year follow-up to a randomized clinical trial of participant satisfaction with three types of mandibular implant-retained overdentures. *J Dent Res*. 2004;83:630-3.
- [4]. Oetterli M, Kiener P, Mericske-Stern R. A longitudinal study on mandibular implants supporting an overdenture: the influence of retention mechanism and anatomic-prosthetic variables on periimplant parameters. *Int J Prosthodont*. 2001;14: 536-42.
- [5]. Cornell K. Lee, and John R. Agar. Surgical and prosthetic planning for a two-implant-retained mandibular overdenture: A clinical report. *J Prosthet Dent*. 2006;95:102-3.
- [6]. Klemetti E, Chehade A, Takanishi Y, et al. Two-implant mandibular overdentures: simple to fabricate and easy to wear. *J Can Dent Assoc*. 2003;69:29-33.
- [7]. Watson GK, Payne AG, Purton DG, et al. Mandibular overdentures: comparative evaluation of prosthodontic maintenance of three different implant systems during the first year of service. *Int J Prosthodont*. 2002;15:259-66.
- [8]. Walton JN. A randomized clinical trial comparing two mandibular implant overdenture designs: 3-year prosthetic outcomes using a six-field protocol. *Int J Prosthodont*. 2003;16:255-60.
- [9]. O. Boudrias P, Chehade A. Two-implant overdentures with ball attachments: a step-by-step approach. In: Feine JS, Carlsson GE, eds. *Implant Overdentures: The Standard of Care for Edentulous Patients*. Carol Stream, Ill: Quintessence Publishing Co; 2003;129-43.
- [10]. Shifman A, Marshak B. Implant-retained mandibular overdentures: A simplified, cost-effective treatment approach. *Quintessence Int*. 1994;25:825-8.
- [11]. Dominici JT, Kinderknecht KE, Patella-Clark E. Clinical procedure for stabilizing and connecting O-ring attachments to a mandibular implant overdenture. *J Prosthet Dent*. 1996;76:330-3.
- [12]. Van Wass MA. The influence of clinical variables on patient satisfaction with complete dentures. *J Prosthet Dent*. 1990;63:307-10.

Dr Manu verma. "Implant Supported Overdenture: A Viable Treatment Option for Edentulous Patient." *IOSR Journal of Dental and Medical Sciences (IOSR-JDMS)*, vol. 18, no. 6, 2019, pp 28-31.