

## Evaluation of Topical Ozone Therapy in Traumatic Ulcer Healing in the Tongue of Rats

ImanM.S, Matar<sup>1</sup>, LawahezEL.M.Ismail<sup>2</sup>

<sup>1</sup>(ProsthodonticsDepartment, Faculty of Dentistry, Pharos University,Alexandria, Egypt)

<sup>2</sup>(Oral PathologyDepartment, Faculty ofDentistry/ MansouraUniversity, Mansoura,Egypt)

Corresponding Author: ImanM.S, Matar

**Abstract:** Ozone therapy was reported as a promising agent used medicinally for the treatment of various diseases which leads to increase the interest to it. Thus, this study was carried to assess the effect of on ozonized gel on the healing of traumatic ulcers conducted in the rat's tongue. Twenty four Wistar rats were used and divided randomly into two groups of 12 animals each of the study group (with ozone gel) and the control group (without ozone). An excisional ulcer circular in shape with 5 mm diameter were made in the middle of the ventral surface of their tongue. After 24h, samples for microbiological analysis were taken and ozone gel was applied topically to the ulcers daily. On the fourth and the eighth days postoperatively 12 rats, six of both the control group and the ozone group were euthanized for histological evaluation. Before animals sacrifice, other microbiological samples, as well as clinical evaluation of the traumatic ulcers, were performed. The results clarified that the size of the ulcers in the ozonized group were significant speedily decreased ( $P \leq 0.01$ ) at all the experiment periods in comparison to the control group. Moreover, after seven days of treatment with ozone, all the ulcers were healed completely. Ozonized group showed a highly significant reduction in the total aerobic count (CFU/mL) by comparing to the control group ( $P \leq 0.002$  after three days and  $P \leq 0.001$  after seven days), as well as it was manifested promotion of re-epithelialization of the ulcers, increases of collagen fibers as well as increases of blood supply in it.

**Conclusion:** Ozone has a worthy therapeutic influence in accelerating and promoting healing of the traumatic ulcer clinically and histologically. Moreover, it has a significant reduction of the bacterial colonies on the healing ulcers due to its strong antibacterial effect.

**Keywords:** Anti-inflammatory, Antimicrobial, Ozonized gel, Re-epithelialization, Ulcer healing.

Date of Submission: 07-04-2019

Date of acceptance: 22-04-2019

### I. Introduction

Oral traumatic ulcers are small, painful, and irregular in shape lesions covered by a thin grayish necrotic membrane and encircled by inflammatory tissues<sup>1</sup>. Amongst the worthy causing factors of traumatic ulcers, the mechanical repeated irritating action to oral mucosa plays a remarkable role. This can be due to sharp margins or rough surfaces either with fracture teeth or restorations, malocclusion, parafunctional habits. In addition, the removable prosthesis can cause traumatic ulceration due to ill-fitting dentures, lack of stability or retention, overextension of the flanges, roughness and pressure sites in the tissue surface of the dentures<sup>2</sup>. The shape of these ulcers takes the same shape of the denture segment which causing the trauma. The most involved sites occur on the lateral sides of the tongue, the labial and buccal mucosa, maxillary and mandibular vestibules<sup>3</sup>.

Treatment of traumatic ulcers caused by dentures was performed by the elimination of the cause either by correction of the denture (relief the peripheries of flanges & pressure sites) or discontinuation of the use of the denture. In addition many methods and materials have been used in an effort to accelerate the repair of the tissue and prevent the infection like low-level laser therapy<sup>4</sup>. Mouth washes act as antiseptic, (e.g. Chlorhexidine Povidone-iodine) topical antibiotics (e.g. erythromycin)<sup>5</sup>. In spite of great effort to improve ulcer healing, the results of these agents are far from ideal results. Furthermore, studies have shown that chlorhexidine and Povidone-iodine have a cytotoxic influence on oral epithelial and fibroblast cells<sup>6,7</sup>.

Ozone therapy was used successfully for a lot of dental and medical purposes moreover, its benefits and effects were reported in many studies in the literature which resulting in increasing attention to it<sup>8</sup>. Ozone has been reported to be very safe, has no side effects and free from medicaments, like antibiotics<sup>9</sup>.

Ozone (O<sub>3</sub>) is tri-atomic oxygen, pungent odor, with a light blue color. It is unstable and disbands to an oxygen molecule (O<sub>2</sub>) and one oxygen atom (O) which is highly reactive<sup>10</sup>.

In dentistry, ozone is applied topically in the form of gas or dissolved in deionized water to produce (ozonated water) or in plant oils, like olive oil to produce (ozonated oil). Studies have reported that ozonated oil

is the ideal form of O<sub>3</sub> due to its stability which can stay stable for two years while stored at 4°C.<sup>11,12</sup> Moreover, it is non-toxic and considered the safest medical therapy introduced<sup>13</sup>.

Ozone therapy can be used topically for promoting and accelerating healing of wounds in the oral mucosa due to its strong antimicrobial effect, anti-inflammatory, its abilities to encourage circulation of blood and stimulating immune reaction<sup>14</sup>.

Ozone has been advised for the treatment of various kinds of ulcers; include oral aphthous ulcers and aphthous stomatitis<sup>15</sup>, ulcers in the gastrointestinal tract<sup>16</sup>, and ulcers in the skin<sup>17</sup>.

Nevertheless, in the previous investigations, there is an absence of evaluating the influence of the usage of ozonized gel topically on traumatic ulcers in the oral cavity therefore; a preclinical investigation has been needed.

Thus, the present study designed to assess the effect of on ozonized gel on the healing of traumatic ulcers conducted in rats tongue which performed by microbiological, clinical and histological analysis.

## **II. Material And Methods**

The samples of the animals consisted of 24 male Wistar rats weighing 300–350g and have seven weeks old. The experiment was done in the animal house of Pharos University. The rats stayed in cages with free access to food and water. They were divided randomly into two groups of 12 animals each of the control Group & the study group (ozone gel).

### **Anesthesia**

The rats were anesthetized with intramuscular injection of ketamine hydrochloride (0.1ml/100mg weight) and xylazine hydrochloride (0.05ml/100mg weight).

### **Surgery procedure**

The rats were laid in the supine posture and the tongue was dragged out with a clinical tweezers to reveal its ventral surface. An excisional ulcer circular in shape with 5 mm diameter and 1 mm depth were made using a punch-out biopsy device in the middle of the ventral surface of the tongue and about 3 mm from its apex to permit the precise position of the ulcer to be specified during follow up even after healing<sup>18</sup>.

### **After 24 hours of surgery**

1. **The first microbiological samples:** were performed for both groups control group and ozone group by using sterile swabs to collect the bacteria from the ulcers followed by their transmission to sterile individual tubes have 10 mL of sterile saline to allow suspension of the adherent bacteria.
2. **Topical application of Ozone gel:** Peclavus olive oil healing gel\* was used which prepared by allowing ozone gas (14µg/mL concentration) generated from an ozone generator to be bubbled into pure olive oil for several days until it becomes a gel<sup>19</sup>. The rats were randomly divided to either the ozone group (where the rats received a suitable amount of ozone gel was applied with cotton applicator to the ulcer area or the control group (where the ulcers of the rats had not been treated with ozone). After each application, food and water were taken away for thirty minutes to keep ozone gel in contact with the ulcer as long as possible. This procedure was repeated every 24 hours respectively during the time of the experiment, totaling three and seven days. On the fourth day and the eighth day postoperatively 12 rats, six of both the control group and the ozone group were euthanized followed by the following procedures:
  1. Clinical and macroscopic evaluation of the healing of the traumatic ulcers was performed which was assessed through visual inspection, in addition, macroscopic evaluation of the ulcer closure was done by measuring the diameter of the lesions in millimeters using a periodontal probe which placed near the ulcer
  2. The second microbiological samples were collected from the ulcers on the fourth day
  3. The third microbiological samples were collected at the end of procedure on the eighth day.

### **Microbiological analysis**

The antimicrobial effect of ozone gel was evaluated using total aerobic counts as a parameter, which was expressed as colony forming units per milliliter (CFU/mL). Bacteria were cultured on a petri dish with a growth medium (Nutrient Agar Medium) this method is known as a Pour plate (PP) method. The plates were aerobically incubated at 37 °C for 48 h. then the bacterial colonies can be counted utilizing a counting chamber<sup>20</sup>.

---

\* Hellmut Ruck Company Germany

**Samples preparation for Histological analysis**

The tongue of rats was surgically resected and its tissues were fixed in 10% formalin. After 24 h the samples were embedded in paraffin and 5- $\mu$ m-thick sections were cut from each sample in the central area of ulcers then the samples were stained with hematoxylin and eosin (H &E) and submitted to routine histological evaluation. All stained slides were examined under light microscope Olympus binocular microscope (model BX50)

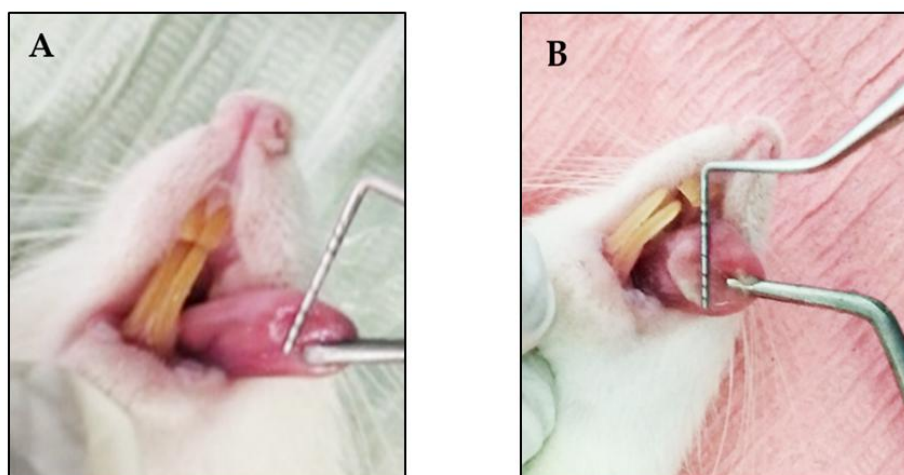
**Statistical analysis**

Data were collected and analyzed by IBM SPSS software package version 20.0. All parametric variables were analyzed by ANOVA, Post-hoc Tukey's and Student's t-test. The statistical significance was taken at p-value  $\leq 0.05$ .

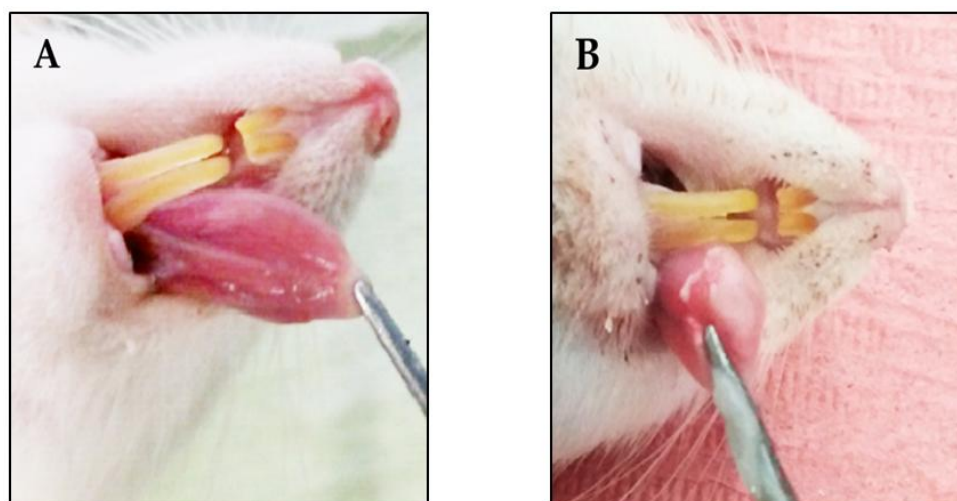
**III. Result**

**Clinical and macroscopic observations**

It was observed that there were no undesirable sideeffects in the ozone group after application of ozone gel therapy and in the control group(no ozonized). The clinical healing progression of the ulcers of the ventral surface of the rats was viewed in both groups at different time intervals (base line, after three and seven days but ozone group showed faster healing in comparison to control group. After three days of ozonized gel treatment, the ulcers of the study group were speedily decreased in size in comparison to the control group Figure no 1. Moreover, after seven days of treatment with ozone, all the ulcers were healed completely and remaining shallowdepression at the site of the excisional ulcer while the ulcers in control group were not completely healed Figure no 2.



**Fig. no 1:** After 3-day the ulcers decreased in size in ozone group (A) than the control group (B).



**Fig. no 2:** After 7-day Ozone Group (A) showing complete healing of the traumatic ulcer Control Group (B) showing the presence of traumatic ulcer.

In table no 1 and graph no 1 showed differences in the mean and standard deviation of the ulcer size in mm at various time intervals of ozone and control groups by using ANOVA test and Post Hoc Test (Tukey) There was a significant decrease in the mean of ulcer size between the three periods in both ozone and control groups. After seven days of treatment, there were the lowest mean values of the ulcer size of both groups, however, the lowest reduction (zero) manifested in the ozone group only.

In addition, when comparing the mean of the ulcers size between the ozone groups and control groups at various time intervals of the research using Student's t-test there was a significant decrease ( $P \leq 0.01$ ) in the mean ulcer size after three days of treatment in the ozone group. After seven days the mean ulcer size was significantly decreased ( $P \leq 0.01$ ) in the ozone group to zero, indicating complete epithelization in addition, there were no remaining ulcers in the ventral surface of the tongue of rats. These results displayed that the application of ozone gel topically on traumatic ulcers has enhanced and accelerated healing.

**Table no 1:** Comparison between the two studied groups according to ulcers size

Ulcer size	Baseline	After treatment		F	p0
		3 days	7 days		
Control group					
Mean ± SD.	5.0a±0.0	4.2b±0.8	2.0c±0.6	78.478*	<0.001*
Median (Min. – Max.)	5.0(5.0–5.0)	4.0(3.0–3.0)	2.0(1.0–3.0)		
Sig. bet. periods	p1=0.006*,p2<0.001*,p3<0.001*				
Test group					
Mean ± SD.	5.0a±0.0	1.7b±0.8	0.0c±0.0	354.375*	<0.001*
Median (Min. – Max.)	5.0(5.0–5.0)	1.5(1.0–3.0)	0.0(0.0–0.0)		
Sig. bet. periods	p1<0.001*,p2<0.001*,p3<0.001*				
t		5.514*	7.746*		
p		(<0.001*)	(<0.001*)		

t: Student t-test

p: p value for comparing between the two studied groups

F: F for ANOVA test, Pairwise comparison bet. each 2 groups was done using Post Hoc Test (Tukey)

p0: p value for comparing between the three periods

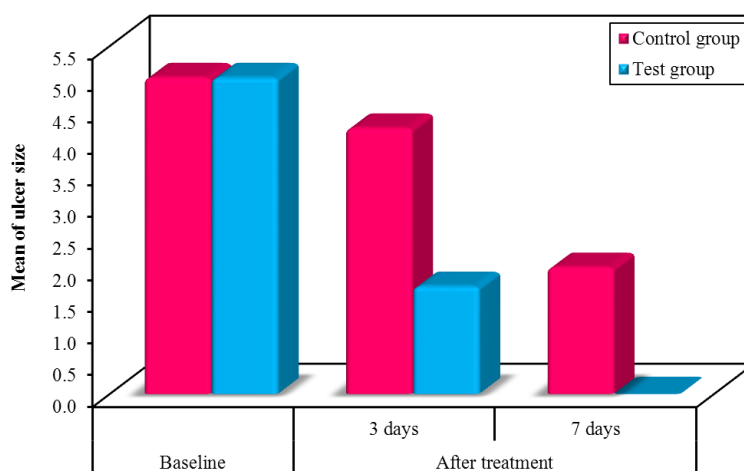
p1: p value for comparing between baseline and after 3 days after treatment

p2: p value for comparing between baseline and after 7 days after treatment

p3: p value for comparing between after 3 days and after 7 days after treatment

Means with Common letters are not significant (i.e. Means with Different letters are significant) for comparing between the three periods

\*: Statistically significant at  $p \leq 0.05$



**Graph no 1:** Comparison between the two studied groups according to ulcers size

### Microbiological results

Table no 2 and graph no2 showed the mean values of total aerobic count (CFU/mL) and standard deviations of the study group (with O3) at three periods of treatment (Before treatment after 24 hours of surgery and three and 7 days After treatment) when compared with the control group (without O3) by the use of ANOVA test and Post Hoc Test (Tukey). It was found that there was a decrease in mean values of total aerobic count during

the periods of the experiments in both control and test groups, however, before treatment both control and test groups had the highest mean values while after seven days of treatment they had the lowest mean values. The statistical analysis indicated that regarding the periods of treatment there was no significant difference in total aerobic count values was detected in the control group. However, in the test groups, there was a significant reduction in the values between all the periods of treatment until the end of the experiment. In addition, there was a high reduction in the total aerobic count values after three and seven days of treatment. Although there was a reduction between the values after 3 days of treatment and after 7 days of treatment there was no significant difference between them.

Student t-test was used to compare between the two studied groups at different periods of treatment according to total aerobic count (CFU/mL). It was detected that before treatment there was no significant difference in the values between the two groups.

After three days of treatment, there was a highly significant reduction in the values of the test group in comparing to the control group. As well as, there was a highly significant reduction in the values of the test group in comparing to the control group after seven days of treatment.

**Table no2:** Comparison between the two studied groups according to total aerobic count (CFU/mL)

Total aerobic count (CFU/mL)	Before treatment After 24 hours of surgery	After treatment		F	p <sub>0</sub>
		3 days	7 days		
Control group					
Mean ± SD.	2954.0±1425.9	2948.0±867.9	1613.4±176.2	3.175	0.078
Median (Min. – Max.)	2540(1310–4500)	3200(1900– 4100)	1535(1460– 1895)		
Test group					
Mean ± SD.	2952.0 <sup>a</sup> ±859.2	830.0 <sup>b</sup> ±514.3	181.8 <sup>b</sup> ±41.4	31.352*	<0.001*
Median (Min. – Max.)	2680(1990–4200)	700(200–1550)	174(136–248)		
Sig. bet. periods	p <sub>1</sub> <0.001*, p <sub>2</sub> <0.001*, p <sub>3</sub> =0.220				
t	0.003	4.694*	17.689*		
p	(0.998)	(0.002*)	(<0.001*)		

**t: Student t-test**

p: p value for comparing between **the two studied groups**

**F: F for ANOVA test**, Pairwise comparison bet. each 2 groups was done using **Post Hoc Test (Tukey)**

p<sub>0</sub>: p value for comparing between **the three periods**

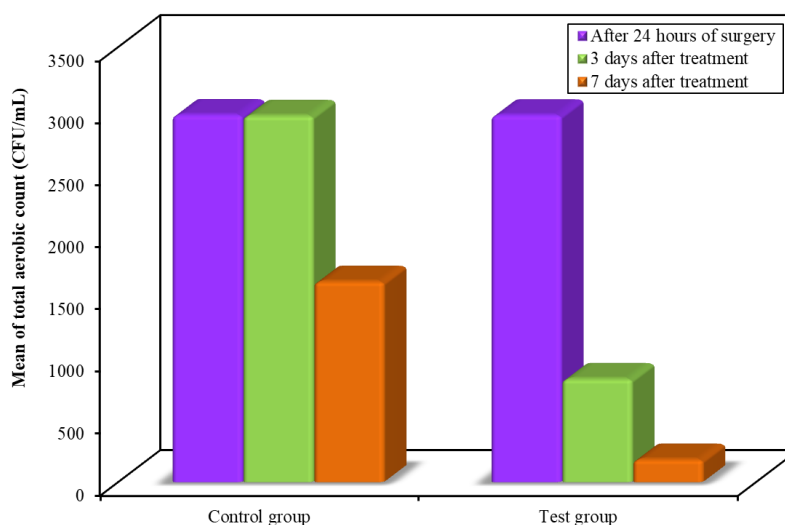
p<sub>1</sub>: p value for comparing between **After 24 hours** and **after 3 days after treatment**

p<sub>2</sub>: p value for comparing between **After 24 hours** and **after 7 days after treatment**

p<sub>3</sub>: p value for comparing between **after 3 days** and **after 7 days after treatment**

Means with **Common letters** are not significant (i.e. Means with **Different letters** are significant) for comparing between **the three periods**

\*: Statistically significant at p ≤ 0.05

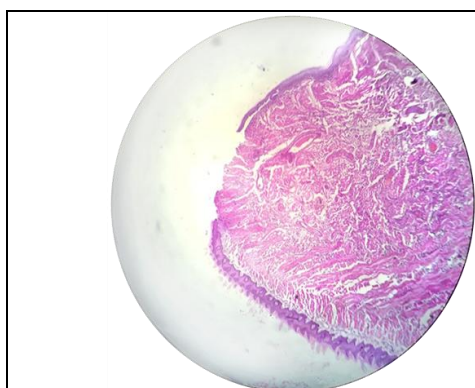


**Graph no 2:** Comparison between the two studied groups according to total aerobic count (CFU/mL).

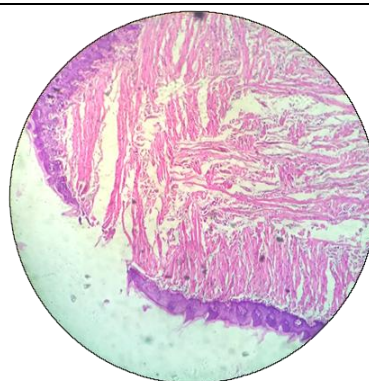
**Histological analysis**

After 3 days of ozonized gel treatment in the study group Figure no 3 displayed incomplete wound healing of surface epithelium. The underlying connective tissue shows: Moderate inflammatory cells infiltration, large number of collagen fibers as well as dilated blood vessels with extravasated RBCs. In control group (no ozonized gel) Figure no 4 showed incomplete wound healing of surface epithelium. The underlying connective tissue shows less number of collagen fibers, mild inflammatory infiltration & edematous spaces are also observed.

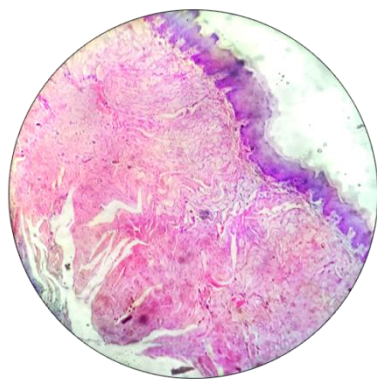
In study group after 7 days of ozonized gel treatment Figure no 5 showed complete closure of the ulcer. The underlying connective tissue shows: moderate amount of inflammatory cells with prominent collagen fibers as well as dilated blood vessels with extravasated RBCs. In control group Figure no 6 clarified incomplete wound healing of the surface epithelium. The underlying connective tissue shows: Moderate amount of inflammatory cells as well as collagen bundles.



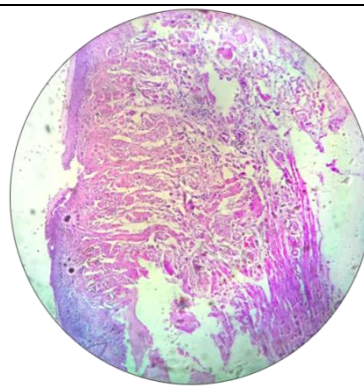
**Fig. no 3:**Photomicrograph of ozone group after 3-days shows: Incomplete wound healing of surface epithelium. The underlying connective tissue has moderate inflammatory cells infiltration. Less number of collagen fibers as well as dilated blood vessels with extravasated red blood corpuscles (H &E stain, original mag.X40)



**Fig. no 4:**Photomicrograph of control group after 3-days shows: Incomplete wound healing of surface epithelium. The underlying connective tissue has large number of collagen fibers, mild inflammatory infiltration & edematous spaces are also observed (H &E stain, original mag.X40)



**Fig. no 5:**Photomicrograph of ozone group after seven days shows: complete wound closure of the ulcer. The underlying connective tissue has moderate amount of inflammatory cells with prominent collagen fibers as well as dilated blood vessels with extravasated RBCs. (H &E stain, original mag.X40)



**Fig. no 6:** Photomicrograph of control group after seven days shows: Incomplete wound healing of the surface epithelium. The underlying connective tissue has moderate amount of inflammatory cells as well as collagen bundles. (H &E stain, original mag.X40)

#### **IV. Discussion**

Oral ulcerations are a challenge to the clinical practitioners since the lesions are susceptible to infection and additional painful traumatization. Recently researchers have recommended the use of ozone for therapeutic sakes which was used for a long time as alternative medicine and as an adjuvant to the traditional medicine. Therefore, the present study was carried to assess the therapeutic influence of topical ozonized gel on the healing of traumatic ulcers conducted in the rat's tongue.

Our clinical results showed that after ozonized gel application in test group there was faster healing of the ulcers of the ventral surface of the rats when compared to the control group.

In the ozone group after three days of application of ozonized gel, the ulcers were decreased faster in size in comparison to the control group. In addition, after seven days of application of ozone therapy in the ozone group, all the ulcers were healed completely and remaining shallow depression at the site of the excisional ulcer while the ulcers in control group were not completely healed.

This could be because ozone enhances the efficiency of blood for carrying on oxygen, which increases the metabolism of the cells of inflamed tissues and enhances energy that used by promoting aerobic metabolism. Therefore, ozone enhances the regeneration of cells and their activity and improves the healing of the tissues<sup>21</sup>.

Another explanation stated by Zielins et al. (2014)<sup>22</sup> and Zhang et al. (2014)<sup>23</sup> who reported that there was a correlation between greater reduction in wound size ( $p < 0.001$ ) and a significant increases in growth factor (PDGF) expressions which resulted after application of ozone therapy to the patients suffering from ulcers in the diabetic foot.

These processes of the functions of ozone hasten the healing of ulcers and clarified the notified decrease in the size of ulcers in this study.

Our study was consistent with a recent study conducted by AlZarea B K. (2019)<sup>24</sup> who assessed the efficiency of ozone therapy in the healing of the traumatic ulcers related to the dentures. They applied ozone gas by healOzoneapparatus to the ulcers of the study group ( $n=75$  patients) for 60 seconds and air to the ulcers in the control group ( $n=75$  patients) for 60 seconds. The size of ulcers was measured in each patient at baseline of the experiment and every day until 15 days, the levels of pain have evaluated and duration of the ulcers was calculated from the interval it took to be healed completely and disappear. They concluded that applying ozone gas for 60 seconds to traumatic ulcers related to dentures was accompanying with decrease the size of the ulcer, duration of the ulcer, the levels of pain and enhancing the healing of the ulcer.

A study carried out by Patel P V et al (2011)<sup>19</sup> also supported our results, they estimated the influence of ozonated oil on the healing of wounds performed in the palate of 18 patients performed by free gingival graft surgery. The patients were divided to either the ozone group (where ozonated olive oil was applied to the wound) or the control group (where non -ozonated olive oil was used) they were put in for one week daily. Their results showed significant enhancement in the size of the wound and epithelial healing after the application of ozonized oil topically in comparison to the control group on the wounds of the palatal.

In addition, our clinical analysis results emphasized by the results of Filippi<sup>25</sup> who manifested that the when ozonated water was applied to a wound in the oral cavity it will hasten its healing within the first 48h compared to placebo water, resulting in faster epithelial closure of the wound after seven days.

Finally, the outcomes of this study supported by results of two studies introduced by Noritaka<sup>26</sup> and Kim et al.<sup>11</sup> where they have proven similar closure of the wound in rats after ozonated oil application topically.

The microbiological analysis was revealed no significant difference in total aerobic count values in the control group (without O<sub>3</sub>) regarding the periods of treatment. In the test group (with O<sub>3</sub>), there was a significant reduction in the total aerobic count values between all the periods of treatment (Before treatment after 24 hours of surgery and three and seven days After treatment). In addition, the test group showed a highly significant reduction in the mean values after three and seven days of treatment in comparison to the control group.

These results displayed the antimicrobial effect of ozone therapy which can explain promoting the healing of the traumatic ulcers. This important mechanism of ozone owing to the fact that wounds in the oral cavity are persistently exposed to comparatively large numbers of oral flora, it is obvious that bacteria have influence healing of the wounds because Increasing of the bacterial colonies on the surface of the wounds which leads to increase their inflammation as well as granulation tissue that may lead to prolonging the healing<sup>27</sup>.

Moreover, increasing the bacterial levels lead to a decrease of epithelialization due to metabolites of bacteria prevent migration of epithelial cells, increase the formation of cytotoxic enzymes and neutrophil proteases that injury newly formed epithelium<sup>28</sup>.

Ozone was found to have a strong antibacterial action which may work directly by disrupting the envelope integrity of the bacterial by peroxidation of phospholipids<sup>29</sup>. Additionally, ozone has an inhibitory influence on NF-kappa B system resulting to be a powerful anti-inflammatory agent and can cessation of the

activity of the disease<sup>30</sup>. Ozone has another role which oxidized the proteins in the intracellular bacteria leading to loss of its organelles functions<sup>31</sup>.

In facts, Ozone has controlled oxidative stress because its action is selective only to microbial cells and has no effect on the cells of the human body due to the presence of antioxidants<sup>32</sup>. Therefore, bacteria can be controlled by ozonized gel which may act directly or indirectly on them and can hasten ulcer healing.

In vitro study by Nagayoshi et al. (2004)<sup>33</sup> reported that ozone was highly antibacterial effective against both gram positive and gram negative oral microorganisms.

Our results are consistent with a study performed by Dmitrieva et al.<sup>34</sup> who evaluated the healing of wound created in the skin of 30 Wistar rats and polluted with microorganisms. The rats were randomly divided into three groups, each group had 10 rats. The skin wounds were irrigated with 10–15mL of perftoran solution (non-ozonized) ozonized perftoran, and physiological solution, respectively to each group. Their results clarified reduction in the mean values of microorganisms in the wounds in the ozonized group, as well as epithelization, was promoted in comparison to the non-ozonized groups.

Additionally, this result was supported by an in vitro study performed by Eick et al. (2012)<sup>35</sup> who detected that ozone has powerful antibacterial effectiveness against perio-dontopathogenic microorganisms and recommended that it can be used as adjunctive therapy in patients suffering from periodontitis.

Conversely a study by, Pietrocola G et al (2018)<sup>36</sup> evaluated, the antibacterial effect of a newly ozonized oil (Ozone gel) against pathogens in the periodontal and oral cavity and compared that with two common CHX agents. The results showed the newly ozonized oil was a mild antiseptic; it was more effective against Gram-negative bacteria than Gram-positive ones. In addition, the ozonized oil manifested a reduction in antibacterial effectiveness in comparison to the CHX- agents.

Histological results supported and explained the previous investigations in the ozonized group which showed faster progresses in the healing process of ulcers at all the study periods in comparison to the control group (non-ozonized). In addition, the ozonized group showed complete closure of all the ulcers at the end of the study which manifested promotion of re-epithelialization of the ulcers, increases of collagen fibers as well as increases of blood supply in it.

After three days of treatment In the ozone group, the histological results showed that there was incomplete wound healing of surface epithelium and the underlying connective tissue showed moderate inflammatory cells infiltration, large number of collagen fibers as well as dilated blood vessels with extravasated RBCs. which progress the healing process by infiltration of white blood cells into the ulcer area which formed cytokines like interleukin and interferon which are concerned with regulating the response of the immune system to infection and inflammation<sup>37</sup>.

This advocates that ozone inhibits the inflammation and control the infection which could enhance healing of ulcers. In addition, the mechanism of healing of the wounds by ozonized oil might be due to its antimicrobial effect, activation of the mechanisms of local antioxidant and enhances repair of the tissues<sup>38</sup>.

The control group after 7 days shows incomplete wound healing of the surface epithelium and the underlying connective tissue shows a moderate quantity of inflammatory cells as well as collagen bundles.

While promising findings in the ozone group after 7 days of O<sub>3</sub> treatment displayed a complete closure of the ulcer which thought to be due to the effectiveness of ozone gel in promoting the healing process which manifested by significantly promoting re-epithelialization of the ulcers. Besides, the underlying connective tissue showed moderate amount of inflammatory cells with prominent collagen fibers as well as dilated blood vessels with extravasated RBCs.

These outstanding findings in the ozone group might be due to the action of ozone on angiogenesis out of VEGF leading to increasing the blood supply to ulcer site<sup>39</sup>. The antimicrobial feature of ozone is another significant mechanism that can clarify the enhancement epithelial healing of the ulcers<sup>40</sup>. In addition, ozone accelerates the epithelial cells migration, from the periphery of the ulcer towards the central part of the defect<sup>19</sup> therefore, it promotes and accelerates healing.

## **V. Conclusion**

1. Ozone has a worthy therapeutic influence in accelerating and promoting healing of the traumatic ulcers of the ventral surface of the tongue in the rats.
2. Ozonized gel showed faster decreasing in the ulcers size at all the study periods in comparison to the control group (non-ozonized).
3. Ozonized group manifested complete closure of all the ulcers at the end of the study
4. Ozone therapy was proven to have powerful bactericidal effectiveness which showed a significant reduction of the bacterial colonies on the healing ulcers
5. Ozonized gel exhibited a significant promotion of re-epithelialization of the ulcers, increases of collagen fibers together with increasing the blood supply



## VI. Recommendations

1. The results of this study encourage the use of ozonized gel in the future for the treatment of traumatic ulcers. However, more clinical studies are needed to evaluate the effect of these drugs on the oral mucosa of humans.
2. In the future, it shows warranted to study the immunohistochemical effect and cytotoxicities of ozone gel on the traumatic ulcers to ascertain its efficiency for their healing.
3. Further research is recommended to compare the influence of ozonized gel with other therapies utilized in the treatment of traumatic ulcers.
4. More studies needed to assess topical ozone gel on other different kinds of oral ulcers.
5. Finally, More investigations are needed to estimate the influence of ozone on the traumatic ulcers using several routes of topical application, various doses and in varied application times during the investigation period..

## References

- [1]. Bombeccari GP, Guzzi G, Pallotti F, Porrini M, Gianni AB, Spadari F. Large oral ulcer of tongue related to dental trauma. *Stomatologija* 2017;19(2):51-54.
- [2]. Piemonte ED, LazosJP, Brunotto M. Relationship between chronic trauma of the oral mucosa, oral potentially malignant disorders and oral cancer. *J Oral Pathol Med* (2010) 39: 513–7.
- [3]. Martori E, Ayuso-Montero R, Martinez-GomisJ, VianasM, PeraireM. Risk factors for denture-related oral mucosal lesions in a geriatric population. *J Proshet Dent* 2014;111:273-9.
- [4]. Kurtulmus-Yilmaz S, Yilmaz HG, Tumer H, Sadettinoglu K. Clinical evaluation of the Er, Cr: YSGG Laser therapy in the treatment of denture-related traumatic ulcerations: a randomized controlled clinical study. *Photomed Laser Surg* 2015;33:224-9.
- [5]. Teixeira DDS, Figueiredo M A Z, Cherubinia, K, Garcia M C R b, Sílvia de Oliveirab, SD, Salum F G. Topical chlorhexidine, povidone iodine and erythromycin in the repair of traumatic ulcers on the rat tongue: Clinical, histological and microbiological evaluation. *Arch Oral Biol*. 2018;87:218-225.
- [6]. Thomas GW, Rael LT, Bar-Or R et al. Mechanisms of delayed wound healing by commonly used antiseptics. *J Trauma* 2009; 66: 82–90.
- [7]. Huth Karin C, Jakob FM, Saugel B et al. Effect of ozone on oral cells compared with established antimicrobials. *Eur J Oral Sci* 2006; 14: 435–40.
- [8]. Singh T, Majumdar S, Ghosh AK, Pal SP, Waghle SR, Dakchiyani MB. Application of Ozone Therapy in Dentistry – A Review. *J Adv Med Dent Scie Res* 2014;2(3):44-47.
- [9]. Sujatha B, Manoj Kumar MG, Pratap Gowd MJS, Vardhan R. Ozone therapy – a paradigm shift in dentistry. *Health Sciences* 2013;2(3):JS003A.
- [10]. Borges G A', Elias S T, da Silva SM, Magalhaes PO, Macedo S B, Ribeiro A P, Guerra EN. In vitro evaluation of wound healing and antimicrobial potential of ozone therapy. *J Craniomaxillofac Surg* 2017 Mar;45(3):364-370.
- [11]. Kim HS, Noh SU, Han YW et al. Therapeutic effects of topical application of ozone on acute cutaneous wound healing. *J Korean Med Sci* 2009; 24: 368–74.
- [12]. Valacchi G, Fortino V, Bocci V. The dual action of ozone on the skin. *Br J Dermatol* 2005; 153: 1096–100.
- [13]. Le'ón OS, Menende'z S, Merino N et al. Ozone oxidative preconditioning: a protection against cellular damage by free radical. *Mediators Inflamm* 1998; 7: 289–94.
- [14]. Sushma Das. Application of Ozone Therapy in Dentistry. *IJDA* 2011; 3(2), 538-542.
- [15]. AL-Omiri MK, Alhijawi MM, AlZarea BK, Abul Hassan R, Lynch E. Ozone treatment of recurrent aphthous stomatitis: a double blinded study. *Sci Rep* 2016;6:27772.
- [16]. Zamora Z, González R, Guanche D, Merino N, Menéndez S, Hernández F, et al. Ozonized sunflower oil reduces oxidative damage induced by indo-methacin in rat gastric mucosa. *Inflamm Res* 2008;57:39-43.
- [17]. Wainstein J, Feldbrin Z, Boaz M, Harman-Boehm I. Efficacy of ozone-oxygen therapy for the treatment of diabetic foot ulcers. *Diabetes Technol Ther* 2011;13:1255-60.
- [18]. Kozlovsky A, Artzi Z, Israeli-Tobias C, Reich L, Hirshberg A. Effect of local antimicrobial agents on excisional palatal wound healing: a clinical and histomorphometric study in rats. *J Clin Periodontol* 2007; 34: 164–171.
- [19]. Patel PV, Kumar V, Kumar S, Gd V, Patel A. Therapeutic effect of topical ozonated oil on the epithelial healing of palatal wound sites: a planimetric and cytological study. *J Invest Clin Dent*. 2011;2(4):248-58.
- [20]. Reasoner DJ. Heterotrophic plate count methodology in the United States. *International journal of food microbiology*. 2004; 92:307-315.
- [21]. Srikanth A, Sathish M, Harsha AVS. Application of ozone in the treatment of periodontal disease. *J Pharm Bioallied Sci* 2013;5:S89-94.
- [22]. Zielins ER, Atashroo DA, Maan ZN, Duscher D, Walmsley GG, Hu M, et al: Woundhealing: an update. *RegenMd* 2014; 9: 817-830.
- [23]. Zhang J, Guan M, Xie C, Luo X, Zhang Q, Xue Y: Increased growth factors play a role in wound healing promoted by noninvasive oxygen-ozone therapy in diabetic patients with foot ulcers. *Oxid Med Cell Longev*. 2014;2014:273475.
- [24]. Bader K. AlZarea, JPD Management of denture-related traumatic ulcers using ozone. *J Prosthet Dent*. 2019;121(1):76-82.
- [25]. Filippi A. The influence of ozonised water on the epithelial wound healing process in oral cavity (in German). *Dtsch Zahnarztl* 2001; 56: 104–8.
- [26]. Noritaka K. Histo-Pathological Research of Wound Healing by Ozone Ointment Application. *J-STGE* 2006; 26: 338–47.
- [27]. Edwards R, Harding KG. Bacteria and wound healing. *Curr Opin Infect Dis*. 2004; 17: 91–6.
- [28]. McGuckin M, Goldman R, Bolton L, Salcido R. The clinical relevance of microbiology in acute and chronic wounds. *Adv Skin Wound Care*. 2003; 16: 12–23.
- [29]. Agapov VS, Smirnov SN, Shulakov VV, Tsarev VN. Ozone therapy in treatment of local sluggish suppurative inflammation of maxillofacial soft tissues. *Stomatologija* 2002;1:23-7.

- [30]. Ramzy MI, Gonna HE, Mostafa MI, Zaki BM. Management of aggressive periodontitis using ozonized water. *Egypt Med J NRC* 2005;1:229-45.
- [31]. Sawadaishi K, Miura K, Ohtsuka E, Ueda T, Ishizaki K, Shinriki N. Ozonolysis of supercoiled pBR322 DNA resulting in strand scission to open circular DNA. *Nucleic Acids Res.* 1985 25;13(20):7183-94.
- [32]. Benita P. Ozone Therapy – A New Approach in Periodontal Management. *IOSR Journal of Dental and Medical Sciences.* 2014;13(3):20-24.
- [33]. Nagayoshi M, Kitamura C, Fukuizumi T, Nishihara T, Terashita M. Antimicrobial effect of ozonated water on bacteria invading dentinal tubules. *J Endod* 2004;30:778-81.
- [34]. Dmitrieva NA, Zyrianova NV, Grigor'ian AS, VasilishinaSlu. [Microflora dynamics in purulent skin wound in rats after ozonized perflorane applications] [in Russian]. *Stomatologiia (Mosk)* 2009; 88: 14–6.
- [35]. Eick S, Tigan M, Sculean A. Effect of ozone on perio- dontopathogenic species in vitro study. *Clin Oral Investig* 2012;16:537-44.
- [36]. Pietrocola G, Ceci M, Preda F, Poggio C, Colombo M .Evaluation of the antibacterial activity of a new ozonized olive oil against oral and periodontal pathogens .*J ClinExp Dent.* 2018;10(11): 1103-8.
- [37]. MoriguchiT.Mechanisms of Effecting Factors in Healing of Wounds.In: Harii EK, Moriguchi T. *Treatment of Wound Recent Progression.* 2<sup>nd</sup>ed. Plastic Surgery Advance Series1-3 .tokyo,Japan: Kokueido; 2005.1-13.
- [38]. Martinez-Sanchez G, Al-Dalain SM, Menendez S et al. Therapeutic efficacy of ozone in patients with diabetic foot. *Eur J Pharmacol* 2005; 523: 151–61.
- [39]. Barakat S B, Seif-El Nasr A, Abdel-Maksoud N, El-EbiaryF, Amer H, Zaghoul A et al. The possible role of medical ozone in angiogenesis. *European ozone seminar* 2003;1-2.
- [40]. Kaul R, Angrish P, Jain P et. al. Ozone therapy- a paradigm shift in dentistry. *Int J Health Sci Res.* 2015; 5(5):410-415.

ImanM.S, Matar. “Evaluation of Topical Ozone Therapy in Traumatic Ulcer Healing in the Tongue of Rats.” *IOSR Journal of Dental and Medical Sciences (IOSR-JDMS)*, vol. 18, no. 04, 2019, pp 26-35.