

Case Report: Orthodontic Management of Case with Skeletal Class Iii Malocclusion and Anterior Crossbite

Dr. Jiju Mohan¹, Dr. Arbab Anjum², Prof. Mohd. Tariq³Dr. Irum Uzma Siddiquie⁴

¹(Department of orthodontics and dentofacial orthopaedics, Dr Ziauddin Ahmad Dental College/ Aligarh muslim University, India)

²(Department of orthodontics and dentofacial orthopaedics, Dr Ziauddin Ahmad Dental College/ Aligarh muslim University, India)

³(Department of orthodontics and dentofacial orthopaedics, Dr Ziauddin Ahmad Dental College/ Aligarh muslim University, India)

⁴(Department of orthodontics and dentofacial orthopaedics, Dr Ziauddin Ahmad Dental College/ Aligarh muslim University, India)

Corresponding author: Dr. Jiju Mohan

Abstract: Class III malocclusion is among the most difficult malocclusion to be corrected, especially using orthodontic means alone. This is a case report of 23-year-old male patient with a chief complaint of irregularly placed teeth and difficulty in mastication, having skeletal class III base and anterior crossbite treated successfully by orthodontic camouflage and non extraction treatment approach.

Keywords: skeletal class III, Camouflage, Non-extraction, Anterior crossbite.

Date of Submission: 20-02-2019

Date of acceptance: 06-03-2019

I. Introduction

Class III malocclusion is far more prevalent in Asian countries than in the West.¹ The incidence of anterior crossbite is 2.3-13 per cent among Japanese, 9.4-19 per cent among Koreans and 12.8 per cent among Chinese² and 14.5 per cent in southern Chinese³. Accordingly, class III malocclusions account for a large proportion of orthodontic patients in these countries—for example, 33 per cent of orthodontic patients in Japan and 20 per cent in China.² In contrast, the prevalence of class III malocclusion in the United States is only about 1.0 per cent of the total population, and only 5 per cent of orthodontic patients.¹

There are three main treatment options for skeletal class III malocclusion: growth modification, dentoalveolar compensation (orthodontic camouflage), and orthognathic surgery. Growth modification should be commenced before the pubertal growth spurt, after this spurt, only the latter two options are possible.

Kerr *et al.*⁴ tried to establish cephalometric yardsticks to objectify treatment decisions. The most important factors that differentiated the surgery and orthodontic patients in their study were size of the anteroposterior discrepancy, inclination of the mandibular incisors, and appearance of the soft-tissue profile..

Successful camouflage treatment for class III malocclusion can be achieved by proclination of maxillary incisors, retrusion of mandibular incisors, and downward and backward rotation of mandible.⁵ Surgical correction of class III malocclusion can be achieved by mandibular setback, maxillary advancement, or a combination of both procedures.⁵

II. Case Report

This is a case report of 23 year old male patient with a chief complaint of irregularly palced teeth and difficulty in mastication.

History: His medical and dental history are non contributory while his family history reveals brother having similar malocclusion

Extra-Oral Examination(Fig.1) shows an apparently symmetrical, mesoprosopic face concave profile with competent lips.



Fig. 1 Pretreatment Extra-Oral Photographs

Intra-Oral features (Fig.2) reveals U-shaped maxillary and mandibular arch with Super Class I Molar relationship on right side and Class I molar relationship on left side, Reverse overbite of 10% Crossbite in relation to 11,21,31 & 41 and rotated 14,15 & 24, 35 & 45. Attrited 11,12.

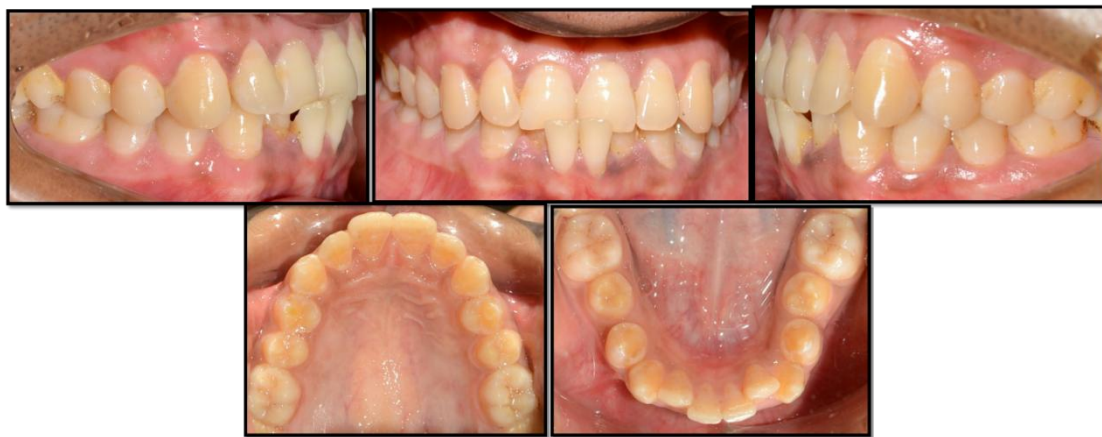

Fig.2 Pretreatment Intra-Oral Photographs

A standard OPG and lateral cephalogram of the patient was obtained. Third molar bud is absent in 1st quadrant. (Fig.3)

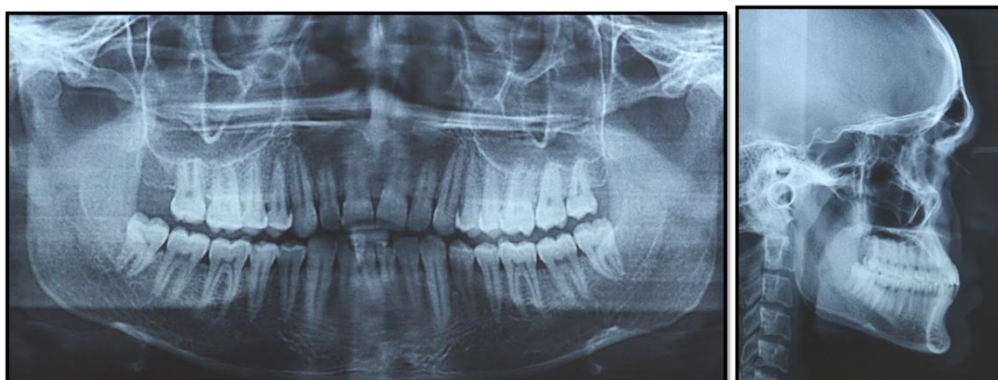

Fig.3 Pre Treatment OPG And Lateral Cephalogram

Cephalometric Analysis Indicates (Table.1,2,3) Class III skeletal base ANB angle 0° . Wits -3mm and hypodivergent growth pattern FMA of 21° and SN-MP of 25° , with Maxillary length of 48mm and Mandibular length 82mm. In addition up U1 to A- Pog of 4mm and U1 to NA = 5mm/ 26° while L1 to A- Pog -5mm L1 to NB = $8/25^{\circ}$ and IMPA was 99° . Inter Incisal Angle of 118° . Soft tissue finding with respect to Ricketts E-line (UL- E-line = 0mm) (LL- E-line = 1mm) and Stieners S-line (UL- S-line = 2mm) (LL- S-line = 3mm). Thenasolabial angle increased to 120° .

CEPHALOMETRIC FINDINGS

Dental Findings	Pre –Treatment	Post -Treatment
Mx 1 to A-Pg	4 mm	8mm
Mx 1 to NA	5mm	7mm
Mx 1 to NA	26°	33°
Md 1 to A-Pg	5 mm	4mm
Md 1 to NB	8mm	6mm
Md 1 to NB	25 °	23 °
IMPA	99°	98°
Inter-incisor Angle	118 °	110°

Table 2: Pre And Post Treatment Cephalometric Dental Finding

CEPHALOMETRIC FINDINGS

Skeletal Findings	Pre –Treatment	Post -Treatment
SNA	87°	87°
SNB	87°	87°
ANB	0°	0°
Wits	-3 mm	-1mm
FMA	21 °	23°
SN-MP	25 °	26 °
Maxillary length(pns-A ⁺) :	48 mm	49 mm
Mandibular length(Go-Pg):	82 mm	84mm

Table 1: Pre And Post Treatment Cephalometric Skeletal Finding

CEPHALOMETRIC FINDINGS

Soft Tissue Findings	Pre –Treatment	Post -Treatment
E – line (mm)	Upper lip-0mm	Upper lip-2mm
	Lower lip-1mm	Lower lip-0mm
S – line (mm)	Upper lip-2mm	Upper lip-3mm
	Lower lip-3mm	Lower lip-3mm
Nasolabial angle	120°	103°

Table 3: Pre And Post Treatment Cephalometric Soft Tissue Finding

StudyModel Analysis Shows: Crowding of 4 mm in maxillary arch and of 3 mm in mandibular arch is present.
Bolton analysis is suggestive of: Mandibular anterior excess of 1.4 mm and overall mandibular excess of 2.4mm.

Diagnosis: Based on patients clinical and cephalometric findings diagnosis of skeletal class III with mandibular prognathism was reached.

III. Treatment Objective /Goal

- Correction of anterior crossbite.
- Levelling and alignment of arches.
- Correction of Overjet and Overbite.
- Tooth coloured restoration with 11,12.
- Long term retention

IV. Treatment Plan

Non extraction Fixed orthodontic mechanotherapy with preadjusted edgewise (MBT-022X028" slot) appliance followed by Long term retention in upper and lower arch

V. Treatment Progress

Initially upper bonding was done with preadjusted edgewise (MBT-022X028" slot) ,along with placement of bite block to disocclude anteriors so as to procline anteriors and as well as to prevent trauma to lower anterior (*Fig.4*)After proclination of upper incisor and reverse overjet correction lower bonding was undertaken.Levelling and alignment was initiated with 0.016"HANT round niti and were progressed till 19X25 stainlesssteel wire.

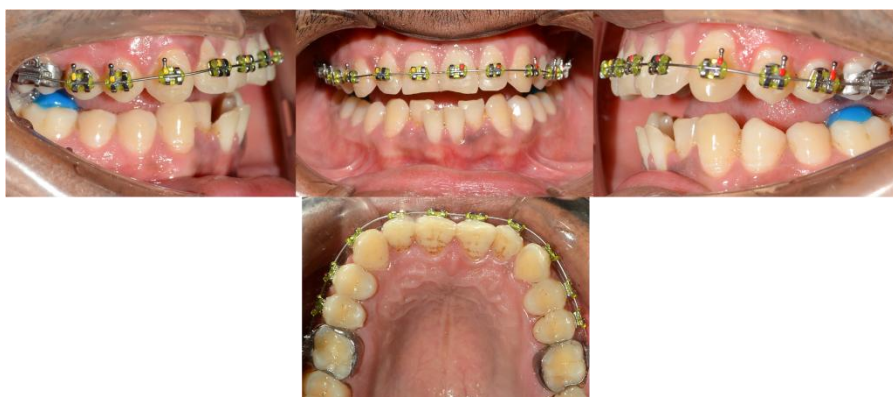

Fig.4 Initial Bonding Of Upper Arch And Placement Of Biteblocks

VI. Result

Treatment duration continued for 2 years, post debonding photographs(*Fig.5,6*)shows correction of anterior crossbite resulting in well aligned dentition with normal overjet and overbite.Molar relation and canine relation was maintained as that of pretreatment .Post treatment radiograph(*Fig.7*) showed that root parallelism and root size was preserved.There were no significant changes in the position of the maxilla or the mandible. Cephalometric superimpositionof pretreatment and post treatment cephalogram(*Fig8,9,10*) showed proclination of upper incisors and retroclination of lower incisors has occurred during. Treatment results were satisfactory.The final harmonious smile pleased the patient and improved his selfesteem and quality of life.

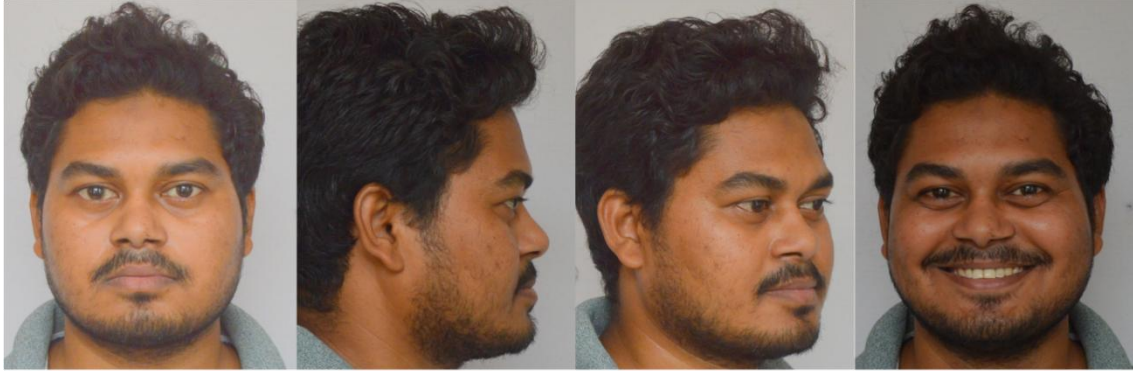

Fig.5 Post Treatment Extra Oral Photographs

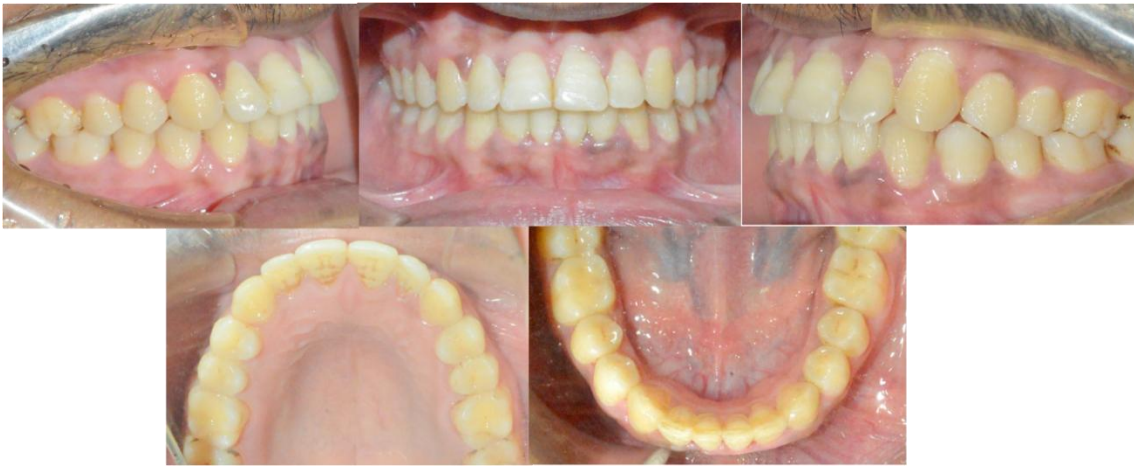

Fig.6 Post Treatment Intra Oral Photographs

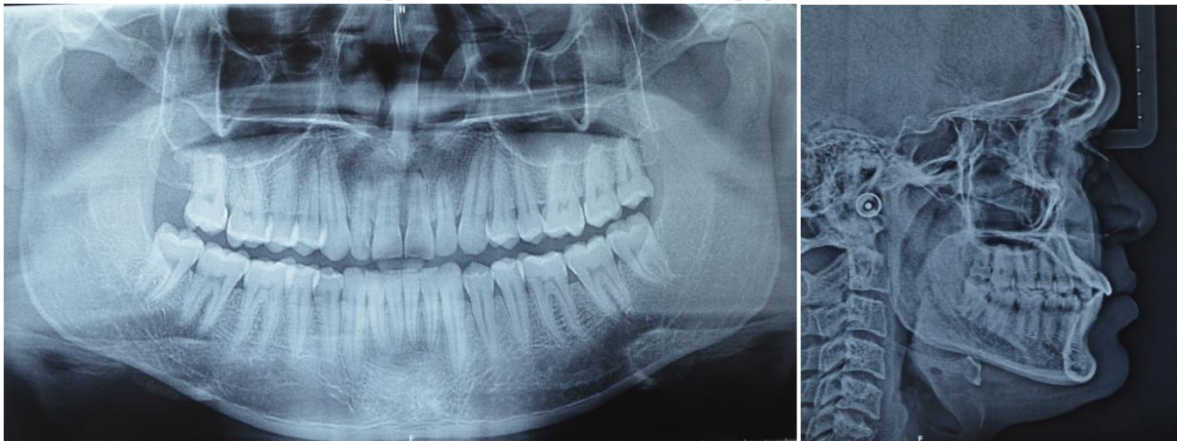


Fig.7 Post Treatment OPG And Lateral Cephalogram

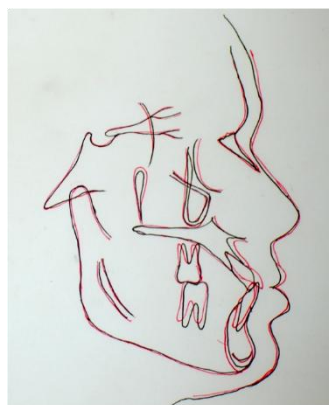


Fig.8 Overall Superimposition




Fig.9 Maxillary Superimposition




Fig. 10 Mandibular Superimposition

RETENTION

Placement of lower bonded lingual retainer and removable Hawleys retainer for the upper arch.

VII. Discussion

The strategy for treating borderline orthodontic cases with camouflage therapy is to create dentoalveolar changes that will compensate for a skeletal base imbalance.¹

The decision as to which type of treatment is indicated is usually based on the degree of the anteroposterior and vertical skeletal discrepancy, the inclination and position of the incisors, and the dentofacial appearance.

In this case, there is mild skeletal and dental disharmony, orthodontic camouflage treatment is a viable alternative for the treatment of mild-to-moderate skeletal discrepancies with the aim of correcting the occlusal relationships in patients who, for different reasons, decide not to be treated surgically.

An ideal candidate for the camouflage treatment should present little residual growth potential, thus allowing for the achievement of the orthodontic camouflage and improving the dentoskeletal relationships. The case described here is a skeletal Class III patient with concave facial profile and crowding of the arches and anterior crossbite. Non extraction treatment in this case is highly favorable because it helps in maintaining the facial profile and also in the correction of mild lower anterior crowding of 1mm. The correction of upper anterior crowding could be achieved by mild proclination of the upper anterior and passive expansion of the arch by archwires, which is an acceptable compromise in the camouflage of skeletal Class III malocclusions.

VIII. Conclusion

This case report demonstrates successful management of Class III malocclusion by camouflage treatment by non extraction treatment approach which in turn depends upon appropriate diagnosis and treatment planning.

REFERENCES

- [1]. Graber TM, Vanarsdall RL, Vig KWL. Orthodontics. Current Principles and Techniques, ed 4. St Louis: Mosby; 2005: 565.
- [2]. Fu M, Zhang D, Wang B, Deng Y, Wang F, Ye X. The prevalence of malocclusion in China--an investigation of 25,392 children. *Zhonghua Kou Qiang Yi Xue Za Zhi* 2002; 37: 371-373.
- [3]. Chan GK. Class 3 malocclusion in Chinese (Cantonese): etiology and treatment. *Am J Ort*
- [4]. Kerr WJ, Miller S, Dawber JE. Class III malocclusion: Surgery or orthodontics? *Br J Orthod* 1992;19:21-4. ↑hod Dentofacial Orthop 1974; 65: 152-157.
- [5]. Treatment in Borderline Class III Malocclusion: Orthodontic Camouflage (Extraction) Versus Orthognathic Surgery A-Bakr M. Rabie1,*, Ricky W.K. Wong2 and G.U. Min3