

The Correlation Between Clinical Findings, Mri, And Arthroscopic Findings In Anterior Cruciate Ligament And Meniscal Injuries Of The Knee

Dr. R.M. Himabindu

Corresponding Author: Dr. R.M. Himabindu

Abstract:

Background :The knee joint is a common site of injury due to trauma, repetitive activities, and sports activities. Clinical diagnosis, encompassing an accurate history, thorough examination and interpretation of investigations, is an art all doctors are expected to master during their career. A number of previous studies have examined the accuracy of clinical diagnosis in traumatic meniscal or ligamentous injuries of the knee. Multiple imaging modalities are currently used to evaluate pathologic conditions of the knee. Magnetic resonance imaging has a better soft tissue contrast and multi planar slice capability which has revolutionized and has become the ideal modality for imaging complex anatomy of the knee joint. Arthroscopy considered to be the 'gold standard' investigative method. Which can be used in its dual mode, either as diagnostic and/or as therapeutic tool. Aim of the study was to correlate clinical, radiological and arthroscopic findings of meniscal and anterior cruciate ligament injuries of knee.

Materials and methods :This is a prospective study involving 30 patients with history of knee injuries who have admitted in Department of Orthopaedics, Narayana medical college was conducted for a period of two year and were scheduled to undergo arthroscopic surgery of the knee for either meniscal or ACL injury based on clinical and Magnetic Resonance Imaging (MRI) findings were included in the study.

Results :: 30 patients were studied comparing clinical examination, MRI with arthroscopy and were analyzed. Clinical examination showed sensitivity, specificity, Positive Predictive value (PPV), Negative Predictive value (NPV), accuracy of 68.1%, 62.5%, 83.3%, 41.6%, 66.6% respectively for medial meniscus tear, 75%, 83.3%, 75.0%, 83.3%, 80% respectively for lateral meniscus tear and 91.3%, 85.7%, 95.4%, 75.0%, 90.0%, respectively for Anterior Cruciate Ligament (ACL) tear. MRI findings showed sensitivity, specificity PPV, NPV, accuracy of 68.1%, 75.0%, 88.2%, 46.1%, 70.0% respectively for medial meniscus, 50.0%, 83.3%, 66.6%, 71.4%, 70.0% respectively for lateral meniscus tear, 78.2%, 85.7%, 94.7%, 54.5%, 80.0% respectively for ACL tear.

Conclusion: Clinical tests to detect ACL and lateral meniscus injuries have a high degree of correlation when compared to arthroscopy and MRI. Clinical tests to detect medial meniscus injuries have a lower degree of correlation compared to MRI and arthroscopy.

Date of Submission: 03-02-2019

Date of acceptance: 18-02-2019

I. Introduction

A meniscus is usually torn by a rotational force incurred while the joint is in a partially flexed position. During vigorous internal rotation of the femur on the tibia with the knee in flexion, the femur tends to force the medial meniscus posteriorly and towards the center of the joint. A strong peripheral attachment posteriorly may prevent the meniscus from being injured, but if this attachment stretches or tears, the posterior part of the meniscus is forced towards the center of the joint and is caught between the femur and the tibia, and is torn longitudinally when the joint is suddenly extended. If this longitudinal tear extends anteriorly beyond the medial collateral ligament, the inner segment of the meniscus is caught in the intercondylar notch and cannot return to its former position; thus a classic bucket-handle tear with locking of the joint is produced. Numerous classifications of tears of the menisci have been proposed on the basis of location or type of tear, etiology, and other factors^[1, 2].

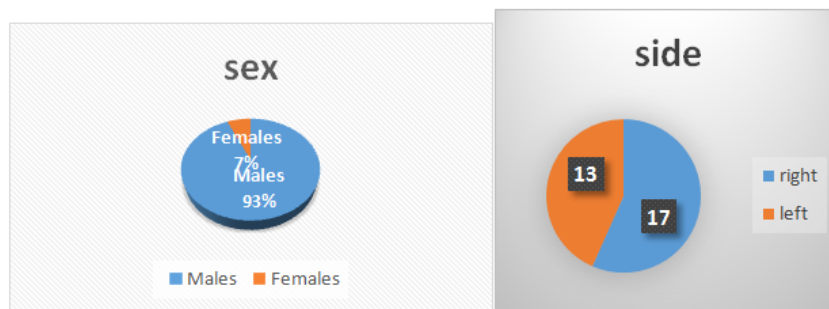
Diagnosis of a meniscal tear is difficult and hence diagnosis is based on collective history which includes complaints, trauma history, mode of injury, findings on physical examination and special modality of imaging which is MRI^[3, 4].

The cruciate ligaments function as stabilizers of the joint and axes around which rotary motion, both normal and abnormal, occurs. They restrict the backward and forward motion of the tibia on the femur and assist in the control of both medial and lateral rotation of the tibia on the femur.

ACL is taut in knee flexion of 70 degrees to 90 degrees and in full extension and is usually injured in this position. Diagnosis depends on history and physical findings and imaging modality is MRI ^[5, 6].

II. Materials And Methods

This is a prospective study involving 30 patients with history of knee injuries who have admitted in Department of Orthopaedics, Narayana Medical College and Hospital between December 2016 to June 2018. Patients with Posterior Cruciate Ligament Injury and other knee injuries were excluded from the study. A detailed history was taken for all these patients followed by clinical examination and MRI evaluation. They patients were subjected to standard pre-operative work up. Arthroscopic surgeries were performed under spinal or general anaesthesia. Operative findings were documented in the operation theatre by operating Orthopedic Surgeon, which included the anatomical structure involved with the presence or absence of tear, its location, additional procedure done .

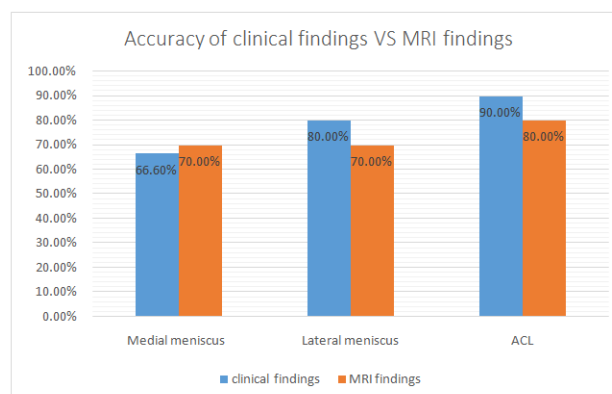


III. Results

The results were presented in number and percentage for dichotomous data in Table and Figure. Statistical analysis was used to calculate sensitivity, specificity, positive predictive value (PPV) and negative predictive value (NPV), accuracy in order to assess the reliability of the Arthroscopy and MRI results. To evaluate the sensitivity, specificity and accuracy of MRI, the findings at arthroscopy were taken to be the true diagnosis.

Diagnostic Value of Clinical Examination			
	Medial Meniscus	Lateral Meniscus	Anterior Cruciate Ligament
Sensitivity	68.1%	75.0%	91.3%
Specificity	62.5%	83.3%	85.7%
PPV	83.3%	75.0%	95.4%
NPV	41.6%	83.3%	75.0%
Accuracy	66.6%	80.0%	90.0%

Diagnostic value of MRI			
	Medial meniscus	Lateral meniscus	Anterior Cruciate Ligament
Sensitivity	68.1%	50.0%	78.2%
Specificity	75.0%	83.3%	85.7%
PPV	88.2%	66.6%	94.7%
NPV	46.1%	71.4%	54.5%
Accuracy	70.0%	70%	80.0%



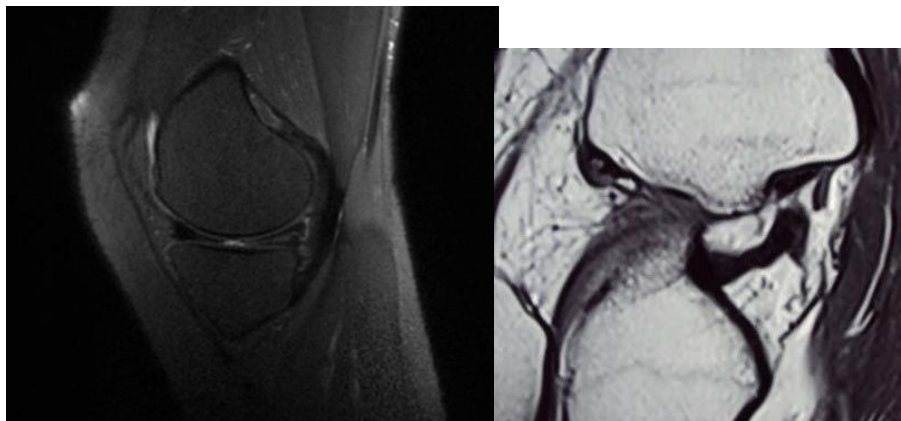
IV. Discussion

The purpose of this study is to compare the accuracy of clinical findings and MRI in diagnosing the most common injuries of the knee i.e. meniscal and ACL injuries, with Arthroscopy as gold standard investigation. In the current study of 30 patients, 28 were males and 02 were females. The age groups ranging from 20 to 40 years. Although meniscal and anterior cruciate ligament injuries are commonly seen and clinically evaluated by Orthopedic Surgeons, the management of these injuries largely depends on MRI findings followed by arthroscopy.

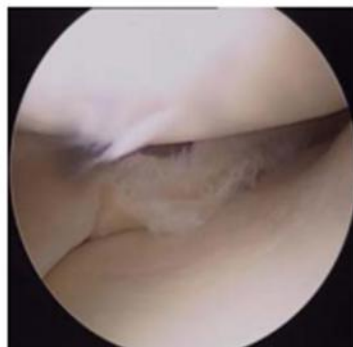
MRI of the knee has become a reliable tool in the detection of knee injuries and is the preferred investigative modality, as it is non-invasive and allows evaluation of all the soft tissue and bony structures, including articular cartilage. However MRI detection of meniscal and ACL injury depends on the observer. Similarly clinical examination is also examiner dependent and subjective.

A review of literature suggests a good correlation for ACL injuries diagnosed clinically and then evaluated by MRI and Arthroscopy^[7-10]. However, when evaluating clinically suspected meniscal injuries, there is a decrease in correlation as compared by MRI and arthroscopy^[8-12]. We decided to compare and correlate the findings found in MRI and clinical examination, keeping arthroscopy as the gold standard. In our study of 30 patients, results are compared to other studies. The results are compared with respect to accuracy, sensitivity, specificity, positive predictive value and negative predictive value. These results are compared to results of similar studies. The results of our study are comparable to other studies in ACL and lateral meniscus injuries, so a patient diagnosed clinically with ACL or lateral meniscus injury can be counseled for definitive management of these injuries with greater degree of confidence, relying solely on clinical examination. However, it has become a standard practice to do preoperative MRI before subjecting the patient to surgery. The accuracy of clinical tests done to detect medial meniscus injuries in our study (66%) is less than that found in similar studies. This can be explained by the fact that many of our cases in which tests for medial meniscus was positive had an osteochondral injury on arthroscopy, which was also missed by the Radiologists on MRI.

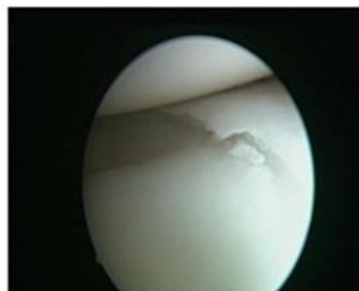Based on our findings, when evaluating medial meniscal injuries and counseling the patient about their management, osteochondral injury should be kept in mind and imaging techniques specific for cartilage should be done prior to arthroscopy. If cartilage imaging modalities are not available then the possibility of finding these injuries at arthroscopy should be explained to the patient and the surgeon should also be prepared to handle these injuries during arthroscopy.



Posterior horn of medial meniscal tear ACL tear



Tear in medial meniscus



Tear in posterior horn of LM

V. Conclusion

Clinical tests to detect ACL and lateral meniscus injuries have a high degree of correlation when compared to arthroscopy and MRI. Clinical tests to detect medial meniscus injuries have a lower degree of correlation compared to MRI and arthroscopy. Clinical tests done to detect medial meniscus injury can be false positive in case of osteochondral defect of medial compartment.

References

- [1]. Maquet PGJ. Biomechanics of the knee, mechanism of injury and diagnosis. New York, Springer, 1976.
- [2]. Walker PE, rkiuan M. The Role of the Menisci in Force Transmission across the Knee. *Clinical Orthopaedics and Related Research*. 1975; 109:184-192.
- [3]. Apley AG. The diagnosis of meniscus injury, some new clinical methods. *J bone Joint Surg*. 1947; 29:78.
- [4]. Chang C, Hondar Wu H, Huang T, Ma H, Hung S. Imaging evaluation of meniscal injury of the knee joint. *Clinical Imaging*. 2004; 28(5):372-376.
- [5]. Kennedy JC, Hawkins RJ, Wilson AS. The anatomy and function of anterior cruciate ligament as determined by clinical and morphological studies. *J Bone Joint Surg*. 1974; 56A:223.
- [6]. Kennedy JC, Flower PJ. Medial and anterior instability of knee and anatomical and clinical study using stress machines. *J Bone Joint Surg*. 1971; 53A:1257.
- [7]. Loo WH, Liu YB, Dave Lee YH, Michael Soon YH. A Comparison of Accuracy between Clinical History, Physical Examination and Magnetic Resonance Imaging and Arthroscopy in the Diagnosis of Meniscal and Anterior Cruciate Ligament Tears. *J Ortho*. 2008; 5(3):8.
- [8]. Rayan F, Bhonsle S, Shukla Clinical DMRI. arthroscopic correlation in meniscal and anterior cruciate ligament injuries. *International Orthopaedics (SICO)*. 2008; 33(1):129-132.
- [9]. Navali AM, Bazavar M, Mohseni MA, Safari B, Tabrizi A. Arthroscopic Evaluation of the Accuracy of Clinical Examination versus MRI in Diagnosing Meniscus Tears and Cruciate Ligament Ruptures. *Archives of Iranian Medicine*. 2013; 16(4):229.
- [10]. Gupta K, Sandhu P, Galhotra R, Guleria M. Correlation of clinical, MRI and arthroscopic findings in diagnosing meniscus and ligament injuries at knee joint: A prospective study. *J Orthop Allied Sci*. 2013; 1(1):2.
- [11]. Crane JL. *The Correlation between Clinical and Arthroscopic Diagnosis of Meniscal Lesions*, 2007.
- [12]. Nikolaou V, Chronopoulos E, Savvidou C, Plessas S, Giannoudis P, Efstathopoulos N *et al*. MRI efficacy in diagnosing internal lesions of the knee: a retrospective analysis. *J Trauma Manage Outcomes*. 2008; 2(1):4.

Dr. R.M. Himabindu. "The Correlation Between Clinical Findings, Mri,And Arthroscopic Findings In Anterior Cruciate Ligament And Meniscal Injuries Of The Knee." *IOSR Journal of Dental and Medical Sciences (IOSR-JDMS)*, vol. 18, no. 2, 2019, pp 46-49.