

## Anatomical and Visual Outcomes in Perforated Corneal Ulcers Undergoing Therapeutic Penetrating Keratoplasty

Dr. (Prof.) Sanjeev K Nainiwal<sup>1</sup>, Dr. Vijaya Sharma<sup>2</sup>, Dr. Hemant Sharma<sup>3</sup>, Dr. Prachi Mathur<sup>4</sup>, Dr. Pooja Jangid<sup>5</sup>, Dr. Brijesh Sanwaliya<sup>6</sup>, Dr. Payal Singh<sup>7</sup>, Dr. Akshay Sarraf<sup>8</sup>

<sup>1</sup>MD, DNB, MNAMS, FIMSA, <sup>2</sup>Resident, <sup>3</sup>Resident, <sup>4</sup>Resident, <sup>5</sup>Resident, <sup>6</sup>Resident, <sup>7</sup>Resident, <sup>8</sup>DNB  
Department of Ophthalmology, JLN Medical College & Hospital Ajmer (Rajasthan), INDIA

Corresponding Author: Dr. Vijaya Sharma

Department of Ophthalmology, J. L. N. Medical College & Hospital Ajmer (Rajasthan), India

**Abstract:** Therapeutic penetrating keratoplasty in perforated corneal ulcers shows varied results in terms of anatomical integrity and visual rehabilitation. The poor visual outcome after ThPK may be associated with because of poor socio-economic condition, lower compliance to drugs, poor hygiene and self care. Though Finger counting final vision was present in only 2 cases but anatomical integrity was maintained in all the patients in our small study.

**Key words:** ThPK, visual outcome, perforated corneal ulcer

Date of Submission: 15-10-2019

Date of Acceptance: 31-10-2019

### I. Introduction

Corneal ulceration is a significant cause of corneal blindness everywhere.<sup>1</sup> With the worldwide decrease in trachoma and other traditional causes of blindness, such as onchocerciasis and leprosy, the World Health Organization has recognized that corneal blindness resulting from microbial keratitis is emerging as an important cause of visual disability.<sup>2</sup> Corneal ulceration has been recognized as a silent epidemic in developing countries, especially the South-east Asia Region.<sup>1</sup> By extrapolation of Indian estimates of the incidence of corneal ulcer, approximately 1.5-2 million people develop corneal ulcer annually in our country.

Infective keratitis is a common vision-threatening entity which occurs in the whole world.<sup>1</sup> A significantly large proportion of eyes with microbial keratitis progress to corneal perforation<sup>3</sup> resulting in severe ocular morbidities and even loss of globe<sup>4</sup>. Such cases often require an emergency surgical intervention, such as therapeutic penetrating keratoplasty (ThPK). ThPK can therefore help in saving many eyes structurally and functionally which otherwise may be lost.<sup>4</sup> ThPK remains the most vital treatment strategy for perforated infectious corneal ulcers.<sup>5</sup> With improved economic development and access to medical care, the developing world is becoming better equipped to treat and cure infectious corneal ulcers.<sup>6</sup> In the developing world, successful outcomes of ThPK for perforated infectious corneal ulcers have been reported in the literature.<sup>7</sup>

Maintenance of anatomical integrity of globe and eradication of the infective organisms are the primary goals of ThPK, whereas visual rehabilitation is of secondary importance.

This study is aimed to evaluate the visual outcome and structural integrity of the eye globe in perforated corneal ulcer undergoing therapeutic penetrating keratoplasty.

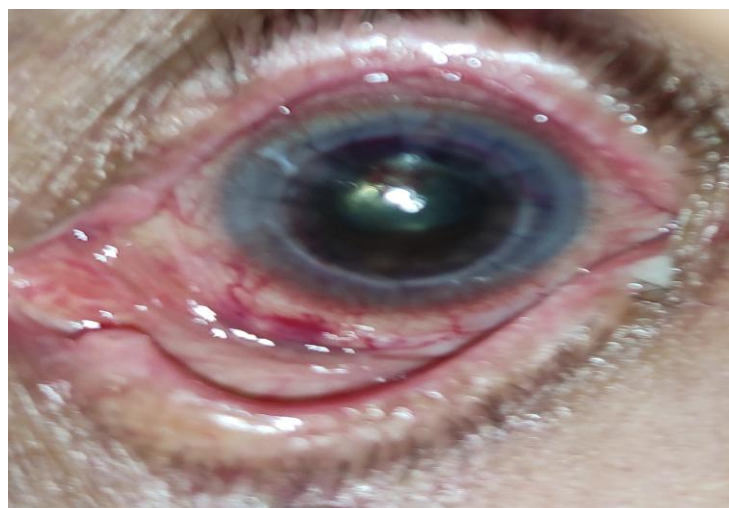
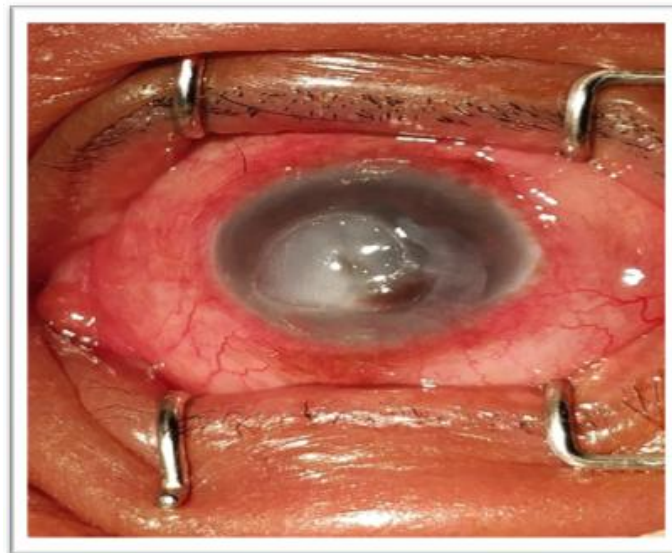
### II. Material & Methods

In this prospective study 13 eyes of 13 patients having corneal ulcer refractory to maximal medical treatment, (infective keratitis with impending perforation and perforated corneal ulcer) were studied from October 2018 to October 2019. All of them underwent therapeutic keratoplasty in our tertiary eye care centre. Baseline characteristics included age, gender, visual acuity, intraocular pressure, corneal sensitivity, staining pattern by fluorescein dye, slit lamp examination, posterior segment examination by B-scan, organisms cultured and antibiotic sensitivity. The ultimate outcome of ThPK was measured in terms of structural integrity of the globe and visual outcome. The patients were followed up at 3 days, 7days, 1 month and 3 months postoperatively.

Therapeutic PK was performed under either a peribulbar block or general anaesthesia. Intraoperatively, care was taken to size the graft 0.5–1 mm more than the area of the infiltrate in its widest dimensions. In a routine ThPK, after removal of the diseased cornea, anterior chamber angle and iris surface were irrigated carefully with saline to remove any exudates and hypopyon and careful inspection was done at the edges of the host to ensure that the area of infiltrate was completely excised.<sup>8</sup> It is recommended that the donor corneal button be cut before the recipient cornea. This helps to ensure that a good quality and optimally prepared donor button is available prior to trephination of the recipient cornea.<sup>9</sup> Graft size is depend upon planned host cornea cut. Donor graft size increase or decrease cause graft- host disparity. Most corneal surgeons use a 0.5 mm oversized graft for their routine cases. The trephine used for the recipient cornea was 0.5mm less than that used for donor cornea. The trephine was carefully placed over the recipient cornea and trephined to half thickness of cornea. Side port blade was used to make an entry in to the anterior chamber. Using Castroviejo's corneal scissors, full thickness of recipient cornea is cut along the already made trephine markings. The recipient cornea was cut in to two equal halves and was send for microbiological and histopathological examination. The donor corneal button is placed carefully on the recipient bed and aligned well. Suturing of the donor cornea to the recipient bed is done with 14 -16 interrupted sutures with 10-0 nylon in all cases. The first suture put at 12'o clock is the most important for the proper alignment of the donor cornea and the second suture put at 6'o clock determines postoperative astigmatism.

Rest of the cardinal sutures were put at 3 o'clock and 9 o'clock making sure that they are not too tight or loose. Rest 12 sutures were put radially around the donor button to the recipient bed. Anterior chamber was maintained with air or balanced salt solution and was checked for any leaks. Sub conjunctival injection of gentamycin and dexamethasone was given.<sup>10</sup>

**Figure 1:** Pre operative perforated corneal ulcer [above] and same eye after 1 month postoperatively (below)

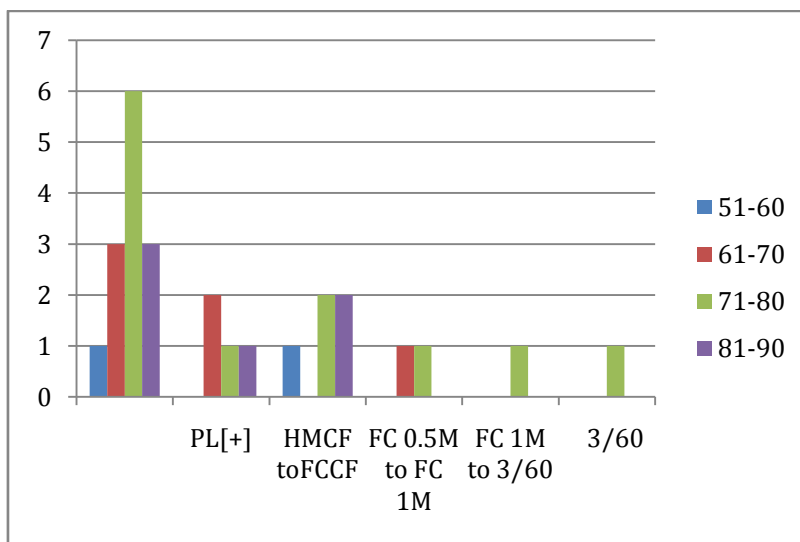


### III. Results

13 eyes of 13 patients of corneal ulcer underwent therapeutic penetrating keratoplasty. Mean age of the subjects was 57.2 years. 9 out of 13 patients(69.2%) were females while 4(30.7%) were males. 4 out of 13(30.7%) corneal ulcers were positive for fungal culture, 6 out of 13(46.1%) were bacterial culture positive while 3 out of 13(23.07%) had no organism growth on culture plate.

Out of 6 bacterial positive culture cases, 3 (50%) showed gram positive cocci, 1(16.6%) showed gram negative cocci , and 2(33.3%) showed pseudomonas on culture plate.

2 out of 13 (15.3%) had graft rejection and underwent regrafting. All 13 (100%) maintained structural integrity of the globe. All 13 pre operative vision was PL[+] to HMCF and after TPK patient vision were PL[-] is [ 30.7%] and HMCF TO FCCF is [38.4%], FC 0.5 meter to FC 1 meter vision is[ 15.3%]and FC 1 meter to 3/60 [7.6%], >3/60



**Figure 2:** Bar charting showing visual outcome after ThPK

### IV. Discussion

The main purpose of therapeutic penetrating keratoplasty surgery is to remove the infection and restoration and maintenance of ocular integrity. Postoperative visual acuity and graft clarity are related to many complex immunological and physiological conditions, so visual rehabilitation is a secondary objective. Corneal ulcer presenting to our tertiary eye care centre are severe , already perforated or impending to perforation . In such ulcers organism isolated in our study is fungal and bacterial .

After restoring of structural integrity of the globe, a subsequent smaller optical penetrating keratoplasty is an option in some of the eyes<sup>10-13</sup>. After ThPK antimicrobial treatment reduces graft re-infection and steroid treatment reduces the frequency of graft rejection. Anatomical integrity of the globe was achieved in all eyes of perforated corneal ulcer and cure all the infective keratitis cases, result are similar to chavdar balabanov study.<sup>14</sup>

Sharma et al reported that anatomical success rate for bacterial corneal ulcer is 90-95% and for fungal corneal is success rate is 84.6% -88.5%.<sup>14</sup> In our study anatomical success rate in ThPK for bacterial and corneal ulcer is same .

Bacterial and fungal organism are isolated in our study are most common organism causing infective keratitis in our country. We had some culture negative cases also. This could be because patients were treated with antimicrobials. In our study bacterial to fungal ratio underwent ThPK was 3:2. the indication of ThPK vary from country to country . In india, people working in agriculture field and therefore more prone to injuries and infections. If injury due to vegetative matter the fungal ulcer frequency is more. There is high prevalence of risk factor for poor visual prognosis after ThPK in patients such as a history of ocular trauma with organic matter during agriculture work, delayed diagnosis, inappropriate management and lack of modern facilities in rural areas and use of traditional or cocktail eye medication<sup>13</sup>. In our study preoperative visual acuity in all patient was low; light perception to HMCF. Only One eye final visual acuity was 1/60 and one eye is 3/60, rest of the eyes have unchanged result compared to preoperative status of visual acuity. Visual outcome depends on various factors such as causative agent, timing of surgery, degree of inflammation, type of donor material use and size of the graft used.

Sharma et al reported ( 14.8% ) patient visual acuity more than 6/60 at 1 year follow up<sup>15</sup>. However, in our study, none of the patient acquired visual acuity more than >3/60. This may be associated with because of poor socio-economic condition, lower compliance to drugs , poor hygiene and self care .

## V. Conclusion

Our results confirm that ThPK for keratitis specifically in perforated corneal ulcer is successful in restoring anatomic integrity but visual rehabilitation in most eyes is not improved up to the mark. However, without ThPK, these eyes would have been lost otherwise.

## References

- [1]. Whitcher JP, Srinivasan M, Upadhyay MP. Corneal blindness: A global perspective. Bull World Health Organ 2001;79:214-21.
- [2]. Resnikoff S, Pascolini D, Etya'ale D, Kocur I, Pararajasegaram R, Pokharel GP, *et al*. Global data on visual impairment in the year 2002. Bull World Health Organ 2004;82:844-51.
- [3]. N. Saeed, M.D. Khan The challenge of microbial keratitis in Pakistan Pak J Ophthalmol, 26 (3) (2010), pp. 112-113
- [4]. J. Titiyal, S. Negi, A. Anand, R. Tandon, N. Sharma, R.B. Vajpayee Risk factors for perforation in microbial corneal ulcers in north India Br J Ophthalmol, 90 (6) (2006), pp. 686-689
- [5]. J.C. Hill Use of penetrating keratoplasty in acute bacterial keratitis Br J Ophthalmol, 70 (7) (1986), pp. 502-506
- [6]. Z.Y. Akkaya, A. Burcu, E. Doğan, M. Onat, F. Ornek Therapeutic penetrating keratoplasty for infectious and noninfectious corneal ulcers Int Ophthalmol, 35 (2) (2015), pp. 193-200
- [7]. Lalitha, N.V. Prajna, G. Manoharan, M. Srinivasan, J. Mascarenhas, M. Das Trends in bacterial and fungal keratitis in South India, 2002–2012 Br J Ophthalmol, 99 (2) (2015), pp. 192-194
- [8]. Leena Bajracharya Reeta Gurung. Outcome of therapeutic penetrating keratoplasty in a tertiary eye care centre in Nepal. Clinical Ophthalmology 2015; 9; 2299-2303.
- [9]. Jyothi Mundra, Rohit Dhakal, Ashik Mohamed, Govinda Jha, Joveeta Joseph, Sunita Chaurasia, Somasheila Murthy. outcome of therapeutic penetrating keratoplasty in 198 eyes with fungal keratitis vol 67 page 1599-1605
- [10]. Rasik B Vajpayee MS, FRCSEd, Namrata Sharma MD, Rajesh Sinha MD, FRCS, Jeewan S Titiyal MD Technique of Penetrating Keratoplasty, March 2005 ,DOS Times Vol 10: 334- 338
- [11]. Dr. Manu Thomas<sup>1</sup>, Dr. Hrishikesh Amin, Dr. Vijay Pai, Dr. Jayaram Shetty Department of Ophthalmology, A clinical study on visual outcome and complications of penetrating keratoplasty. IOSR journal of dental and medical science 2015; Volume 14, Issue 6 Version 1: Pages 49-60.
- [12]. Murillo-Lopez F.: Keratitis, Bacterial. Emedicine, April 18, 2006
- [13]. Bower K. S., Kowalski R. P., Gordon YJ: Fluoroquinolones in the treatment of bacterial keratitis. Am J Ophthalmol 1996; 121(6): 712-54
- [14]. *Treatment of perforated infectious corneal ulcers with penetrating keratoplasty* Chavdar Balabanov, Snezhana Murgova, Boriana Parashkevova Eye Clinic, University Hospital "Dr George Stranski" - Pleven, Bulgaria Journal of IMAB 2007, Vol 13 book 1: Pages 35-39.
- [15]. Sharma N, Jain M, Sehra SV, et al. Outcomes of therapeutic penetrating keratoplasty from a tertiary eye care centre in northern India. Cornea. 2014;33(2):114–118

Dr. Vijaya Sharma. "Anatomical and Visual Outcomes in Perforated Corneal Ulcers Undergoing Therapeutic Penetrating Keratoplasty." IOSR Journal of Dental and Medical Sciences (IOSR-JDMS), vol. 18, no. 10, 2019, pp 55-58.