

Cryptogenic Organising Pneumonia (COP) Causing Frequent Exacerbations in a Case of COPD.

Aamil Rasheed¹, Sourya Acharya², Vidiyala Harika³, Sree Karthik Pratapa⁴

^{1,3,4} Resident, Dept. Of Medicine

² Professor, Dept. Of Medicine

Jawaharlal Nehru Medical College

Datta Meghe Institute of Medical Sciences(Deemed to be University)

Sawangi (M) Wardha-442001 Maharashtra India

Corresponding Author: Dr. Sourya Acharya

Abstract: We present a case of a 70-year-old male, chronic smoker and a known case of chronic obstructive pulmonary disease who presented with frequent exacerbations to various private clinics and was treated for the same. The frequencies increased disproportionately and the patient reported in this hospital. Clinical examination revealed signs of COPD. Chest X-Ray and HRCT of lung revealed features of COPD and Cryptogenic organizing pneumonia (COP). The patient responded to conventional COPD treatment and steroid therapy. His condition improved and he was discharged on oral steroids. In follow up after 2 months patient did not complain of any new exacerbation. The diagnosis of cryptogenic organizing pneumonia (COP) depends on clinical, radiological and histological presentations and COP may be a cause of frequent exacerbations in COPD. The present case suggests that clinicians should be alert to this disease in their clinical practices.

Key Words: COP, COPD, pneumonia, steroids, HRCT

Date of Submission: 18-09-2019

Date of Acceptance: 03-10-2019

I. Introduction

Cryptogenic organizing pneumonia (COP) is an interstitial lung disease of idiopathic interstitial pneumonia variety, characterized by whorls of myofibroblasts and inflammatory cells in a connective tissue matrix within the distal airspace.[1-3] The characteristic clinical features of COP are usually nonspecific and include constitutional symptoms with flu-like illness, followed by progressive cough, dyspnoea, fever, elevation of biological inflammatory markers, patchy infiltrates on chest radiography and chest computed tomography (CT), and a restrictive spirometric pattern with diffusion impairment. As COP can be idiopathic or associated with a known underlying disease, delayed diagnosis or misdiagnosis is likely to occur.[1]

II. Case Report

A 70-year-old male, chronic smoker, and a diagnosed case of Chronic obstructive pulmonary disease, presented to us with breathlessness,

cough and mucoid sputum since 2 months. He a known case of COPD, who was receiving LABA plus ICS through metered dose inhaler twice a day, but was having frequent attacks of exacerbations and was getting admitted in several private nursing homes during the last 2 months. This was his ninth presentation to us in this hospital.

The patient reported no history of exposure to musty or dusty conditions that may have exacerbated the symptoms, nor did he have a history any connective tissue diseases. There was no history of fever, alcohol abuse or any drug history. General physical examination revealed signs of respiratory distress in form of tachypnoea (RR-28/min) and use of accessory muscles of respiration. There was no cyanosis, clubbing or pallor.

Respiratory system examination showed; Barrel shaped chest, Upper border of liver dullness was in the right 7th space in mid clavicular line. Superficial cardiac dullness was obliterated on the left. Vesicular breath sounds of equal intensity with prolonged expiration and polyphonic rhonchi were audible bilaterally. Oxygen saturation at room air was 92%. ABG revealed -

pH-7.49, pCO₂—48.6mm Hg, pO₂—66 mm Hg and HCO₃—25 mEq/L. His ECG, urine analyses, blood sugar levels, hepatic and renal functions were within the normal ranges. His HIV (human immunodeficiency virus), HBV (hepatitis B virus), sputum smear microscopy and cultures for bacilli and mycobacteria were negative, sputum was even negative for CBNAAT for TB bacilli. CHEST X-ray revealed hyperlucent lung fields, tubular heart, flattened diaphragms, widening of intercostals spaces with hetrogenous infiltrations in the right lower zone.(Figure-1)

Cryptogenic Organising Pneumonia (COP) Causing Frequent Exacerbations In A Case Of COPD.

HRCT thorax was done which showed area of patchy consolidation and area of ground glass opacity in both upper lobe and postero-basal lobe, rest of the lung showed hyperinflation with centrilobular emphysema in both upper lobe, suggestive of COPD with COP. (Figure-2)

Patient underwent bronchoscopy with bronchoalveolar lavage (BAL) fluid cytology showed inflammatory bronchial smear, negative for AFB or bacilli, and cultural examinations did not disclose any bacterial, viral agent.

After the diagnosis of COP, 60 mg/day prednisone was administered ,symptoms started improving, with the dosage tapering from 60 mg to 40 mg daily, Consequently, the patient's condition improved, and the patient improved dramatically and was discharged with oral prednisolone 40 mg for 6 months with tapering doses .

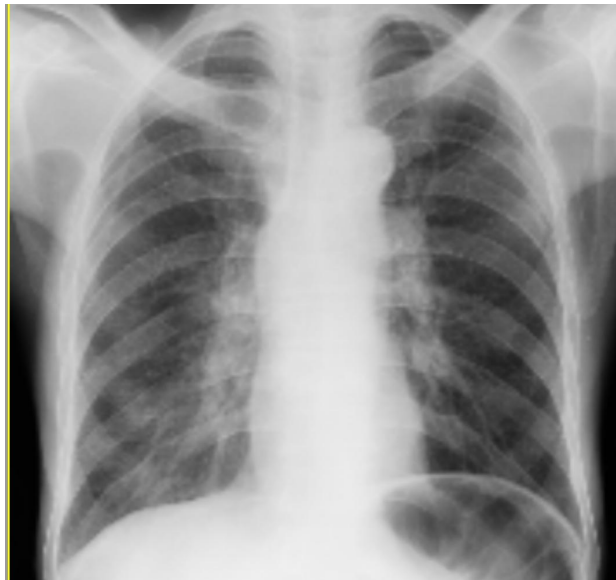

Figure -1: CXR (PA) View showing features of Emphysema and heterogeneous infiltrations in the right lower zone.

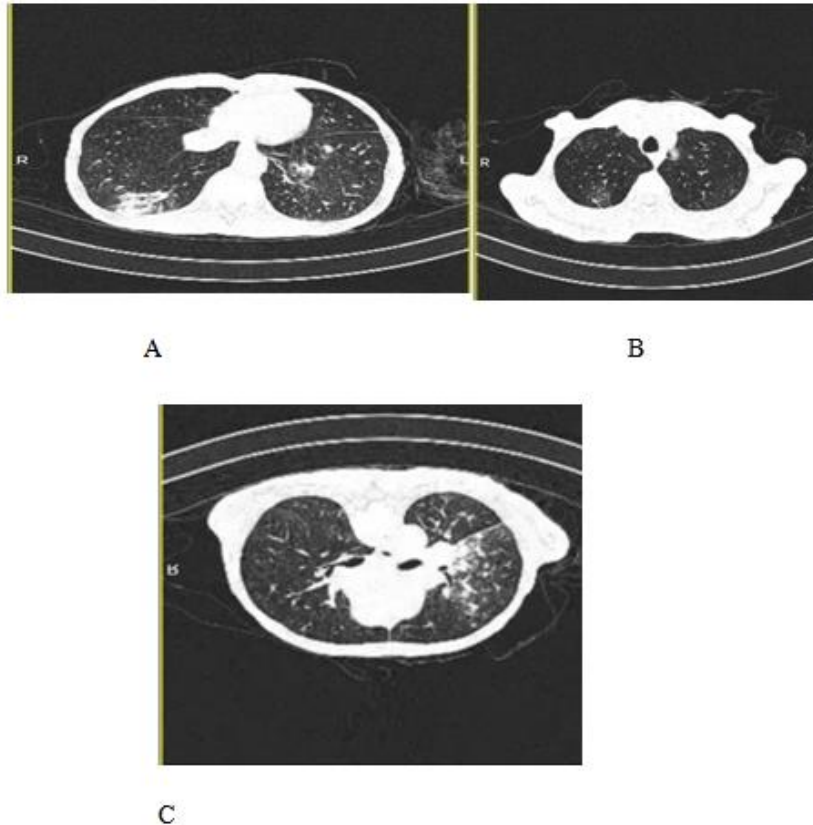


Figure-2: (A)(B) High-resolution CT (HRCT) of the thorax (lung window) on presentation area of patchy consolidation and area of ground glass opacity in both upper lobe and postero-basal lobe. (C) HRCT of the thorax (lung window) on presentation showing hyperinflation with centrilobular emphysema in both upper lobe

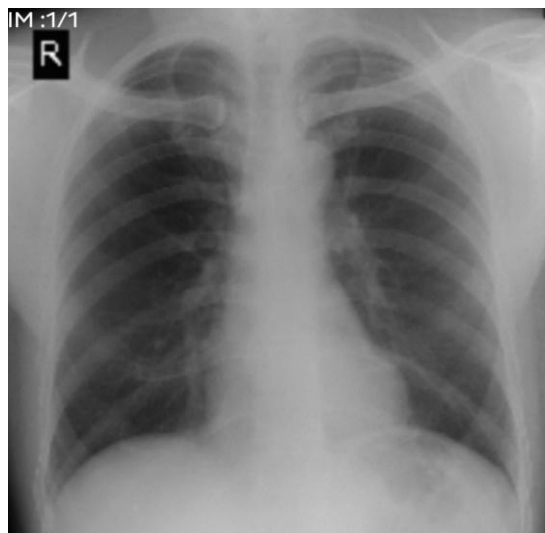

Figure-3: CXR after 2 months follow-up showing clearing of infiltrates.

Outcome and Follow-up:

Within a fortnight, the patient experienced marked clinical improvement with symptoms being largely resolved. Chest imaging performed 2 months later (figures 3) showed remarkable radiological clearance of infiltrates.

III. Discussion

This article reports a 70-year old male patient who was diagnosed with COP as a cause of recurrent exacerbation of COPD. The condition is more commonly observed in never-smokers and ex-smokers, and occurs twice as frequently in this group as compared with that of smokers. Although there is no gender predisposition,

it occurs more frequently in females who are non-smokers. Most series on COP have shown an inverse relationship with smoking. However, an Italian study detected COP in 54% patients who were current smokers as compared with 32% never-smokers and 14% ex-smokers. [4]

To avoid delayed diagnosis and therapeutic pitfalls, clinicians should maintain a high index of suspicion for COP. The disease is usually responsive to corticosteroid treatment. However, relapse can occur when steroids are tapered or discontinued. Long-term use of corticosteroids is often associated with complications in diverse organs and systems, and therefore the importance of limiting corticosteroid prescriptions at the lowest possible dose should be addressed [5]. The strategy should aim at minimizing the adverse effects of corticosteroids and avoiding over-treatment to obtain a well-equilibrated balance between using an efficient treatment protocol and minimization of the adverse effects of corticosteroids by using low doses and short treatment durations.

References:

- [1]. Cordier JF. Bronchiolitis obliterans organizing pneumonia. *Semin Respir Crit Care Med.* 2000;21:135–46.
- [2]. Colby N. Pathologic aspects of bronchiolitis obliterans organizing pneumonia. *Chest* 1992; 102:385-435.
- [3]. American Thoracic Society; European Respiratory Society. American Thoracic Society/European Respiratory Society International Multidisciplinary Consensus Classification of the Idiopathic Interstitial Pneumonias. This joint statement of the American Thoracic Society (ATS), and the European Respiratory Society (ERS) was adopted by the ATS board of directors, June 2001 and by the ERS Executive Committee, June 2001. *Am J Respir Crit Care Med* 2002;165:277–304.
- [4]. Lazor R, Vandevenne A, Pelletier A, et al. Cryptogenic organizing pneumonia. Characteristics of relapses in a series of 48 patients. The Grouped Etudes de Recherche sur les Maladies 'Orphelines' Pulmonaires (GERM'O'P). *Am J Respir Crit Care Med* 2000;162:571–7.
- [5]. Faria IM, Zanetti G, Barreto MM, et al. Organizing pneumonia: chest HRCT findings. *J Bras Pneumol* 2015;41:231–7.

Dr. Sourya Acharya. "Cryptogenic Organising Pneumonia (COP) Causing Frequent Exacerbations in a Case of COPD." *IOSR Journal of Dental and Medical Sciences (IOSR-JDMS)*, vol. 18, no. 10, 2019, pp 78-81.