

## An Unusual Case of Right Iliac Fossa Pain Due to Foreign Body In The Caecum

Dr. C.Arjun<sup>1</sup>, Dr. Celine Foustina Mary<sup>2</sup>

<sup>1</sup>(Postgraduate Student, Department of General Surgery, Tirunelveli Medical College and Hospital, Tirunelveli, Tamil Nadu.)

<sup>2</sup>(Associate Professor, Department of General Surgery, Tirunelveli Medical College and Hospital, Tirunelveli, Tamil Nadu.)

**Abstract:** Foreign bodies are rare causes of right iliac fossa pain and, in most cases, ingested foreign bodies pass through the alimentary tract asymptotically. However, ingested foreign bodies may sometimes remain silent within the caecum or appendix for many years without an inflammatory response. Despite the fact that cases of foreign-body-induced appendicitis/caecitis have been documented, sharp and pointed objects are more likely to cause perforations and abscesses, and present more rapidly after ingestion. Various materials, such as needles and drill bits, as well as organic matter, such as seeds, have been implicated as causes of acute appendicitis. Clinical presentation can vary from hours to years. Blunt foreign bodies are more likely to remain dormant for longer periods and cause right iliac fossa mass or appendicitis. We herein describe a patient presenting with a foreign body(nail) in her caecum which had been swallowed previously.. We suggest that an elective laparotomy should be offered to such patients as a possible management option.

**Keywords:** abdominal pain, appendix, caecum, foreign body ,laparotomy.

Date of Submission: 06-03-2018

Date of acceptance: 26-03-2018

### I. Introduction

Various foreign bodies cause gastrointestinal perforations and inflammation. They are not uncommon in the elderly (denture wearers), alcoholics, children and people with learning difficulties. Most patients do not remember swallowing the foreign body, which is discovered either on imaging or more frequently during surgery. Symptoms vary with the site of the perforation and impaction, and the clinical presentation can mimic different conditions, such as acute appendicitis, diverticulitis, caecal tumors and perforated peptic ulcer. We report a case of, impaction of a metallic sharp pointed foreign body with surrounding inflammation and mass formation around the cecum.

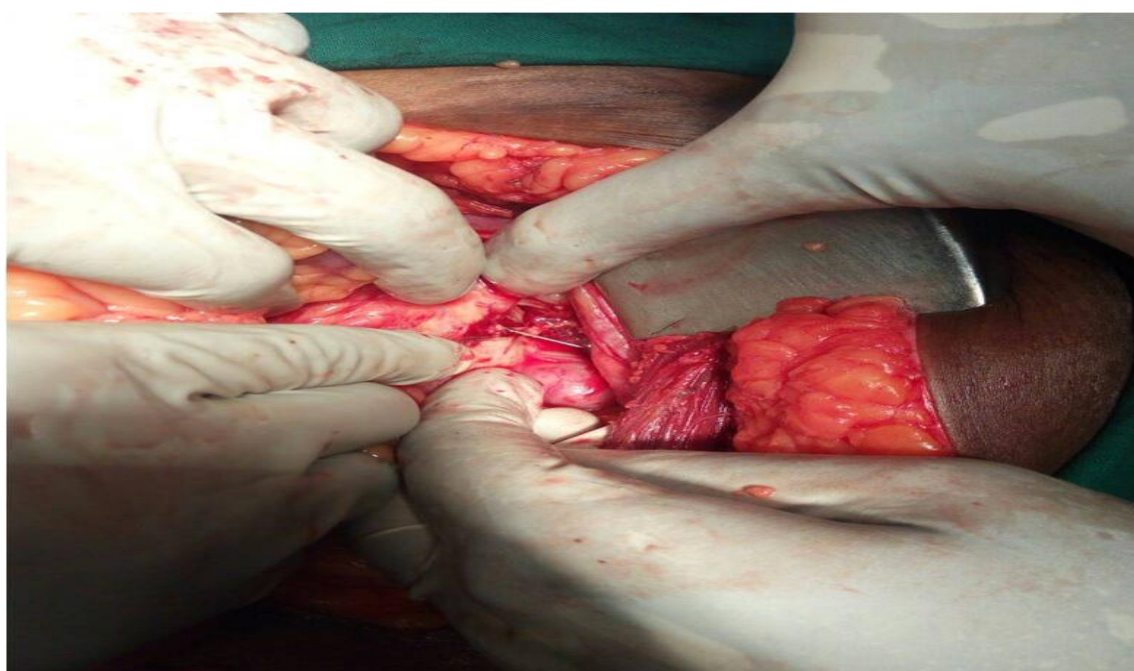
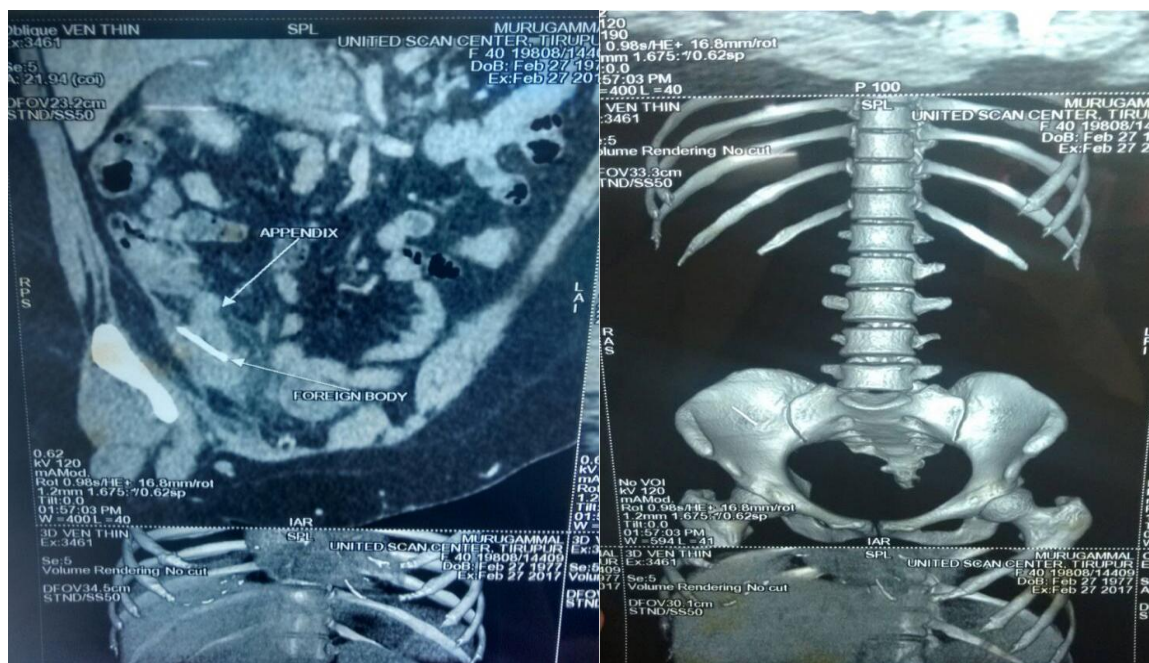
### II. Case Report

A 30 year old female developed pain over the right side of the lower abdomen for 7 days which was sudden in onset, dull aching in character, was more intense during physical work and not relieved by any medications. There was no radiation or conduction of pain and no relation with food intake. There was history of vomiting which was non bilious, not projectile. The vomitus contains digested food particles. She also had history of fever, not relieved by medications. No history of malena/haematamesis.

On examination, Patient was conscious, oriented, febrile, hydration fair, no pallor. Per abdomen examination showed warmth and tenderness over right iliac fossa. There was localised guarding over right iliac fossa. On auscultation, normal bowel sounds heard. No abnormality detected in per rectal examination.

On ultrasonography, there was Minimal free fluid in the right paracolic gutter with Foreign body in RIF.Appendix could not be made out. Diagnosis was further confirmed by CT abdomen and pelvis. CT report showed Linear hyperdense structure located at the base of appendix, within the lumen of caecum, suggestive of metallic foreign body, with significant wall thickening, pericaecal collection and fat stranding.

Once after the diagnosis is confirmed, colonoscopy was contraindicated as there was a possibility of perforating the caecum. So we planned for an exploratory laparotomy. On opening the abdomen the caecum and terminal ileum was found to be inflamed with thickened omentum sealed over the caecal wall, with minimal free fluid in the right iliac fossa. The caecum was opened and a metallic nail was seen inside the caecum,just below the appenicular base. So we proceeded with an ileocaecal resection and end to end anastomosis was done.



### III. Discussion

A variety of foreign bodies may enter the GI tract intentionally or accidentally. Many foreign bodies pass through the GI tract spontaneously, but some become impacted, causing symptoms and sometimes complications. The role of imaging in the management of foreign body ingestion is not standardized. Nearly all impacted objects can be removed endoscopically, but surgery is occasionally necessary. Foreign bodies in the GI tract may be Esophageal, Gastric (including bezoars), Intestinal and Rectal. Foreign bodies may involve the entire upper gastrointestinal (GI) tract. The oropharynx is well innervated, and patients can typically localize oropharyngeal foreign bodies. Scratches or abrasions to the mucosal surface of the oropharynx can create a foreign body sensation. Chronic foreign bodies or perforations can cause infections in surrounding soft tissues of the throat and neck. The esophagus is a tubular structure approximately 20-25 cm in length. Patients can usually localize foreign bodies in the upper esophagus but localize them poorly in the lower two thirds of the structure. Structural abnormalities of the esophagus, including strictures, webs, diverticula, and malignancies, increase the risk of foreign body entrapment, as do motor disturbances such as scleroderma, diffuse esophageal spasm, or achalasia. After reaching the stomach, a foreign body has greater than a 80% chance of

passage.<sup>[1]</sup> Coins reaching the stomach are very likely to pass into the small bowel. Objects larger than 2 cm in diameter are less likely to pass the pylorus, and objects longer than 6 cm may become entrapped at either the pylorus or the duodenal sweep. Objects reaching the small bowel occasionally are impeded by the ileocecal valve. Rarely, a foreign body may become entrapped in a Meckel diverticulum. Occasionally objects such as bones or toothpicks may pass all the way to the rectum, where they become entrapped, causing a foreign body sensation and, potentially, a perforation. The majority of foreign body ingestions occur in children. Deliberate and recurrent foreign body ingestion is described more commonly among prison inmates and psychiatric patients. Denture wearers, the elderly, and inebriated people are prone to accidentally swallowing inadequately masticated food (particularly meat), which may become impacted in the esophagus. Various foreign bodies commonly encountered include bird shot, bullet, fishing lines, screw coins, bristles, pain needle, dog hair, fruit seeds, tooth picks. Foreign bodies are classified as per length > / < 6 cm, radiological characteristic-radiodense / radiopaque, surface consistency-sharp / blunt, content-organic / inorganic.

Nature of the foreign body	According to S. Zhao Li. et al (1)		According to Z. Shenghong et al (5)	
	Number	Percentage	Number	Percentage
Dental prostheses	26	44.8%		
Iron fragments	10	17.2%	1	5.9%
Large foreign bodies (bigger than 10cm)	8	10.3%		
Bones (fish and chicken)	6	6.9%	15	88.2%
Toothpicks	4	6.9%		
Food pieces	2	3.4%	1	5.9%
Gauze	2	3.4%		
Total	58		17	
<b>Anatomical location</b>				
Esophagus	36	62.1%	17	100%
Stomach	12	20.7%		
Duodenum	10	17.2%		
Total	58		17	

\* See corresponding biographic reference.

Investigations required to identify foreign bodies include x ray radiography, barium studies, ultrasonography and CT scan. A preoperative diagnosis of foreign body ingestion is often uncertain; voluntary swallowing of one or more foreign bodies is relatively rare and is normally done by prisoners and attempted suicides, whereas most patients do not realize they have swallowed a foreign body. Gastrointestinal (GI) perforations by a foreign body are rarely diagnosed preoperatively because the clinical symptoms are usually non-specific and mimic other surgical conditions, such as appendicitis, as in our case, or diverticulitis<sup>(5)</sup>. Overeating and rapid eating may be contributing factors to the ingestion of small bones from chicken or other animals. The mean time from ingestion to any perforation is 10.4 days<sup>(6)</sup>; in our case the symptoms were there for last 7 days. The risk of perforation or impaction is related to the length and the sharpness of the object<sup>(7)</sup>. Most perforations occur at the narrowing and angulations of the GI tract<sup>(8)</sup> (i.e., ileocecal valve and rectosigmoid junction).in our case, the foreign body was located at the cecum past the ileocecal valve causing inflammation of the surrounding area with a subsequent mass formation . The definitive diagnosis in this patient was reached by ct scan of the abdomen although the diagnosis of intestinal perforation or inflammation by foreign body was reached during laparotomy in more than 90% of cases<sup>(6)</sup>. All cases involved abdominal contamination and 66.7% had diffuse peritonitis<sup>(3)</sup>. Laparoscopy has been widely accepted among surgeons for the diagnosis and management of acute abdominal condition. Endoscopic retrieval of foreign body is effective and minimally invasive and hence it is widely being practised. The identification of a metallic pin with an associated mass or extraluminal collection of gas in patients with clinical sign of peritonitis strongly suggests the diagnosis<sup>(4)</sup>. Since there was an established mass around the impacted foreign body with signs of inflammation, exploratory laparotomy with resection of ileocecal segment became inevitable. This case is posted for its rarity, since percentage of foreign body at RIF is 0. 0005 %.

#### **IV. Conclusion**

It should be borne in mind that the incidence of acute appendicitis decreases with age. So a non-appendiceal disease should be suspected in an elderly patient presenting with right iliac fossa pain. A foreign body impaction in lower GI tract although difficult to diagnose preoperatively in most of the cases, can be identified however when they are radiopaque. Endoscopic retrieval of a foreign body is not possible once when the inflammation is established as mentioned in our case wherein we must resort to exploratory laparotomy with or without compromising the involved bowel segment.

#### **References**

- [1] Schwartz GF, Polsky HS. Ingested foreign bodies of the gastrointestinal tract. *Am Surg* 1976;42(4):236-8.
- [2] Kumar S, Fitzmaurice GJ, O'Donnell ME, Brown R. Acute right iliac fossa pain: not always appendicitis or a caecal tumour: two case reports. *Cases J* 2009;2(1):88.
- [3] Assa J, Zoireff L, Iuchtman M. Perforation of the sigmoid colon simulating acute appendicitis. *Isr J Med Sci* 1980;16(9-10):646-8.
- [4] Ali W, Khan M. Intestinal perforation due to an ingested foreign body. *J Coll Physicians Surg Pak* 2007;17(4):234-5.
- [5] Yao CC, Yang CC, Liew SC, Lin CS. Small bowel perforation caused by a sharp bone: laparoscopic diagnosis and treatment. *Surg Laparosc Endosc Percutan Tech* 1999;9(3):226-7.
- [6] Hewett PJ, Young JF. Toothpick injuries to the gastrointestinal tract. *Aust N Z J Surg* 1991;61(1):35-37.

Dr. C.Arjun. " An Unusual Case of Right Iliac Fossa Pain Due to Foreign Body In The Caecum." *IOSR Journal of Dental and Medical Sciences (IOSR-JDMS)*, vol. 17, no. 3, 2018, pp 01-04.