

Role of Magnetic Resonance Imaging in the Diagnosis of Adult Onset Movement Disorders

Dr. Ganta Varaprasad¹, Dr. Sandesh Reddy Yaratapalli²

1(Department of Orthopaedics, Guntur Medical College and General Hospital, India)

2(Department of Orthopaedics, Guntur Medical College and General Hospital, India)

Keywords: Parkinsons disease, Parkinson plus syndromes like progressive supranuclear palsy (PSP), multi system atrophy Parkinsons type(MSA-P), cortico basal degeneration (CBD), Huntingtons chorea, Wilsons disease, Halloverden spatz disease & normal pressure hydrocephalus(NPH)

Date of Submission: 06-03-2018

Date of acceptance: 26-03-2018

I. Introduction

Movement disorders are neurological conditions that affect the speed, fluency, quality, and ease of movement.

Most common spectrum of symptoms in movement disorders :

Ataxia (lack of coordination, often producing jerky movements), Tremor (e.g., essential tremor, resting tremor), Dystonia (causes involuntary movement and prolonged muscle contraction), Myoclonus (rapid, brief, irregular movement), tics & Bradykinesia (slowness of movement), hypokinesia.

Most common diseases under spectrum of adult onset movement disorders:

Parkinsons disease, Parkinson plus syndromes like progressive supranuclear palsy (PSP), multi system atrophy Parkinsons type(MSA-P), cortico basal degeneration (CBD), Huntingtons chorea, Wilsons disease, Halloverden spatz disease & normal pressure hydrocephalus(NPH).

MRI is the primary imaging modality of choice in patients with movement disorders. Imaging findings alone are not characteristic themselves but with clinical correlation they are very helpful to achieve a diagnosis. This study is to assess the role of MRI in movement disorders and its help in deciding further course of management and prognosis. Integration of the clinical features and tentative diagnosis with the potential of MRI and SPECT (Single photon emission computed tomography) /PET (positron emission tomography) to provide useful information in the single patient is recommended for optimization of the diagnostic algorithm (1).

conventional MR imaging still lacks sensitivity in distinguishing Parkinsons disease from MSA-P, PSP, and CBD, and also specificity in discriminating between the different Atypical Parkinsons Diseases, but it remains a useful tool for the exclusion of symptomatic causes of parkinsonism(2).

Illustrated how neuroimaging can help in the diagnosis of movement disorders. Radiological findings are never diagnostic, but in the clinical context they can point the way to correct diagnosis. In some rare conditions such as Fragile X Tremor Ataxia syndrome and variant of Creutzfeldt Jacob Disease, the typical neuroimaging findings may be the first diagnostic clue.(3) D.Dormont, D.J Seidenwurm, in their article on dementia and movement disorders listed about movement disorders and their imaging findings (4). Analysis of MRI images of midbrain in patients with parkinsons disease shows narrowing of signal from pars compacta of midbrain(5) Thin section conventional spin echo MRI is sensitive in the better depiction of even mild signs of degeneration in the basal ganglia and useful in the differential diagnosis of parkinsonism(6)

Inversion recovery sequences are helpful in the differentiation of idiopathic parkinsons diseases from other forms of parkinsonism(7) Segmented inversion recovery ratio imaging MRI allows more accurate assessment of abnormalities in PD and PSP(8) Decreased width of pars compacta on MRI (9) may indicate neuronal loss, but substantia nigra appears normal in most PD patients.

II. Aim of The Study

To evaluate the role Of MRI In The Diagnosis Of Adult Onset Movement Disorders

III. Material And Methods

- This study was conducted in patients with suspected central cause for movement disorders
- Study period was from November 2015 to September 2017

- 50 patients with clinically diagnosed central cause for movement disorder were included in my study
- This is a Prospective observational study

Inclusion Criteria: Patients above 18yrs diagnosed clinically having central cause (basal ganglia, cerebellum, brainstem related) for movement disorders except seizures

Exclusion Criteria:

Patients below 18yrs

Patients with absent movement (hemiparesis)

Patients with epilepsy

Patients with peripheral cause (i.e: spinal cord, nerve & muscle related) of movement disorders

Patients with history of trauma

Patients with pacemakers, aneurysmal clips and claustrophobia.

MR imaging was performed with a clinical 1.5 Tesla Signa Excite system (general electrical medical systems, Milwaukee, USA). A dedicated and channelled high resolution head coil was used.

MRI Brain protocol: Routine T1, T2, FLAIR & DW Axials

SPGR Volumetric data with 2mm thick coronals

GRE Axials with long TE-35, TR-650, FLIP angle - 20 Bandwidth - 15

BRIEF PROCEDURE :

Patients clinically suspected with central cause for movement disorder are evaluated with MRI brain examination with desired protocol. Clinical diagnosis and imaging parameters (patterns of regional atrophy, signal changes or micro-structural changes in T2 & FLAIR in basal ganglia, pons, midbrain, middle and superior cerebellar peduncles and cerebral sub-cortical white matter)

are studied. Statistical analysis was done with final conclusion. In this study, I have numbered the patterns of atrophy from 1 to 9 based on the region of brain involved and number 10 with no atrophy. I have numbered the signal patterns on T2 weighted images from 1 to 8 based on the region of brain involved and numbered hyper-intensity as A and hypo-intensity as B.

PATTERNS OF ATROPHY

Frontal – 1

Parietal -2

Temporal-3

Occipital -4

Diffuse cerebral – 5

Cerebellar hemispheres -6

Cerebellar peduncles -7

a- superior b-middle c-inferior

Midbrain -8

a- substantia nigra b -tegmentum

Pons -9

No atrophy -10

SIGNAL CHANGES	
Basal ganglia -1	a- caudate , b-putamen ,c-globus pallidus
Thalamus -2	
Midbrain -3	a- substantia nigra b -tegmentum
Pons -4	
Cerebellar peduncles- 5	a- superior b-middle c-inferior
Cerebellum -6	Cerebral whitematter -7
Periventricular signal changes -8	
A- Hyperintensity	
B- Hypointensity	

IV. Results

4.1: Age Distribution

Out of total 50 cases, most common age group of presentation is in two peaks. First peak is in between 49-58 years(22%) and Second peak is in between 69-78 years(22%). Movement disorders are most common in males. In this study male preponderance is 62%.

4.2: Patterns Of Atrophy

- Pattern 1 atrophy (only frontal) is seen in 1 case of clinically diagnosed atypical parkinsons disease
- Pattern 2 type of atrophy (only parietal) is also seen in 1 case of atypical parkinsons disease
- Pattern 3 and 4 atrophies (only temporal and only occipital) are not seen in any one of my cases but are seen associated with other lobe atrophies in some of the cases(pattern 5 atrophy)
- Pattern 5 (Diffuse cerebral atrophy) is seen in 25 cases of parkinsons disease , 5 cases of chorea , 4 cases of atypical parkinsons disease , 2 cases of ataxia and 1 case of dystonia .Pattern 5 atrophy is not seen in wilsons disease
- Pattern 6 atrophy (only cerebellar hemispheres) is seen in 1 case of ataxia and in 1 case of atypical parkinsons disease
- Pattern 7 atrophy (cerebellar peduncles) is seen in 1 case of atypical parkinsons disease
- Pattern 8 atrophy (midbrain) is seen in 5 cases of parkinsons disease, 1 case of atypical parkinsons disease and 1 case of ataxia
- Pattern 9 atrophy (pons) seen in 1 case of atypical parkinsons disease
- Pattern 10 (No atrophy) is seen in all of my 7 wilson cases, 2 cases of myoclonic jerks and 1 case of dystonia.

4.3: Signal Intensities

Signal intensity observed in my study are almost hyperintense onT2

- Pattern 1: Signal changes in basal ganglia (pattern 1) are seen in all the 7 cases of wilsons disease, 5 cases of chorea, 3 cases of atypical parkinsonism, 2 cases of dystonia and parkinsons disease, 1 case of myoclonic jerks
- Pattern 2: Signal changes in thalamus (pattern 2) are seen in 5 cases of wilsons and 1case of chorea and myoclonic jerks
- Pattern 3: Signal changes in midbrain (pattern 3) are seen in 4 cases of wilsons and 1 case of atypical parkinsons disease
- Pattern 4: Signal changes in pons (pattern 4) is seen in 20 cases of parkinsons disease, 6 cases of wilsons, 5 cases of chorea, 4 cases of atypical parkinsons disease, 1 case of ataxia and dystonia
- Pattern 5: Signal changes in cerebellar peduncles (pattern 5) is seen in 2 cases of wilsons disease, 1 case of ataxia and atypical parkinsons disease

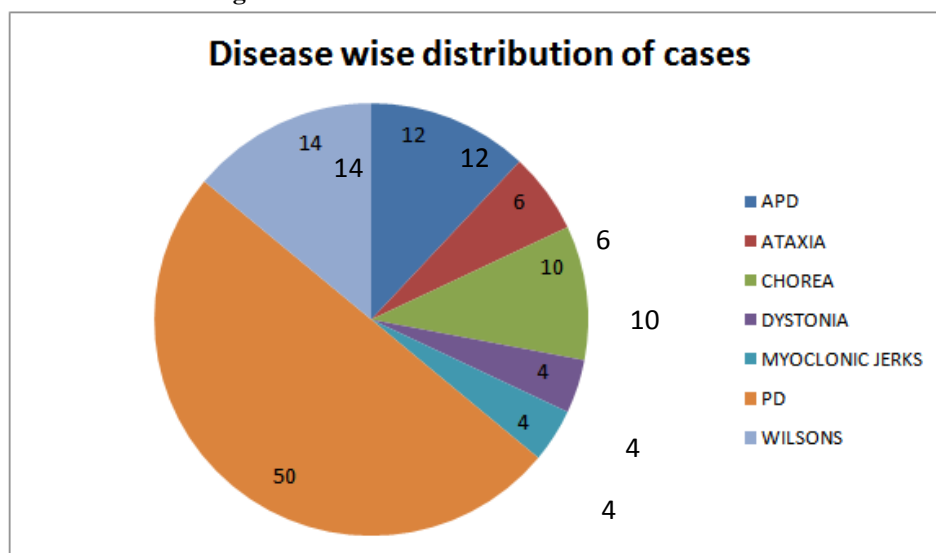
- Pattern 6: Signal changes in cerebellum (pattern 6) is not seen in any one of the case
- Pattern 7: Signal changes in cerebral white matter (pattern 7) is seen in 4 cases of wilsons, 2 cases of ataxia, 1 case of dystonia, myoclonic jerks and atypical parkinsons disease
- Pattern 8: Periventricular signal changes (pattern 8) are seen in all 25 cases of parkinsons disease, 5 cases of chorea, 3 cases of atypical parkinsonism, 1 case of dystonia and myoclonic jerks

V. Tables

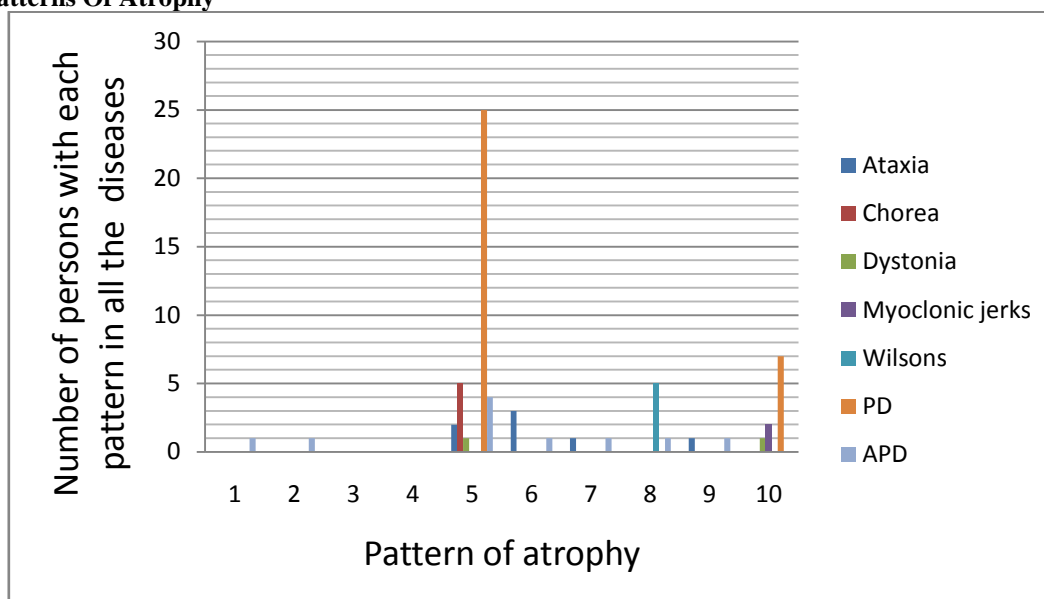
5.1: Age Distribution and Frequency

AGE	FREQUENCY	%
19-28 YEARS	8	16
29-38	3	6
39-48	3	6
49-58	11	22
59-68	10	20
69-78	11	22
79-88	4	8
GRANDTOTAL	50	100

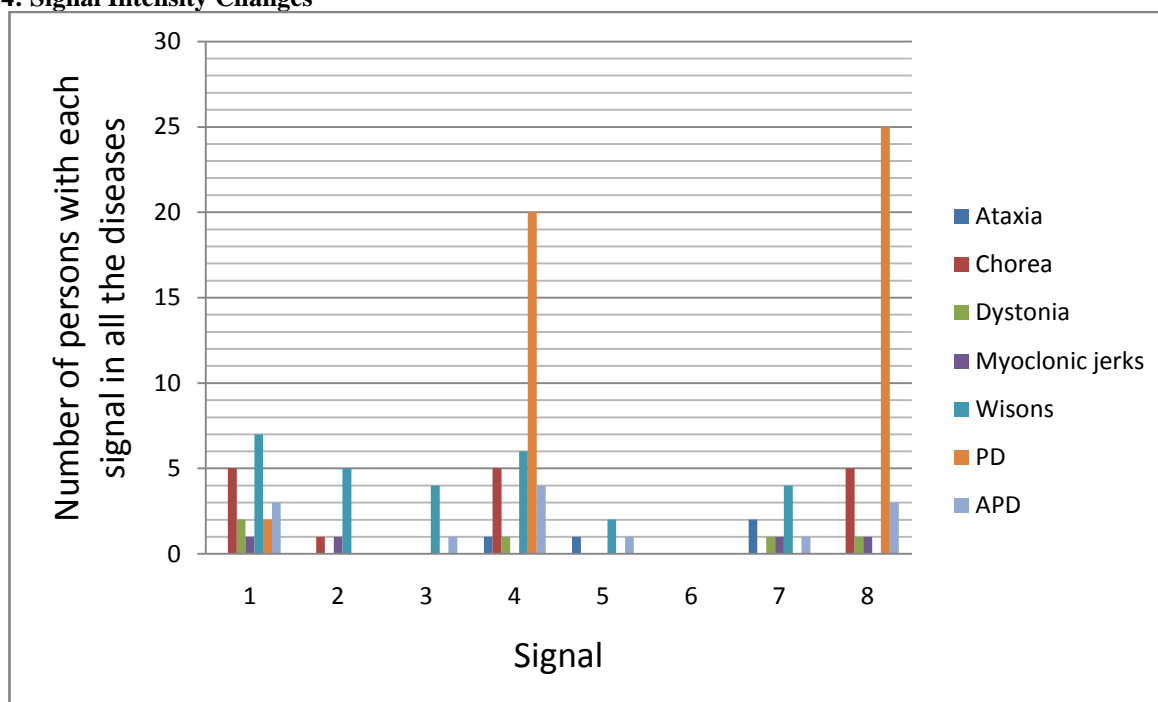
5.2: Disease Distribution Among Cases



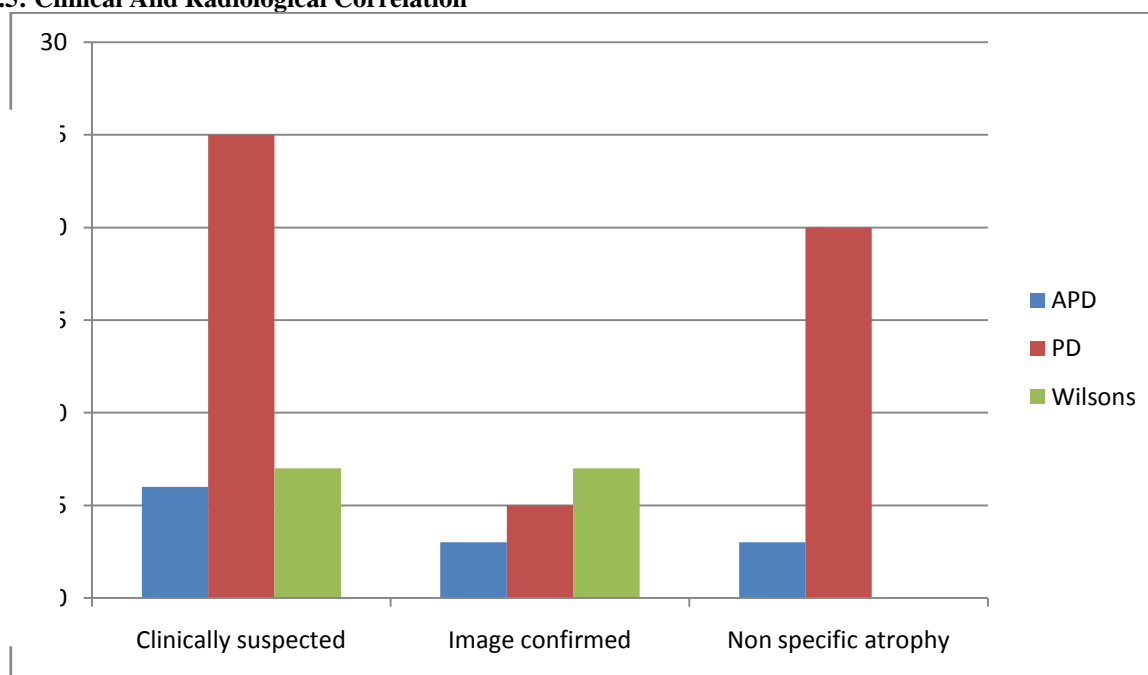
5.3: Patterns Of Atrophy



5.4: Signal Intensity Changes



5.5: Clinical And Radiological Correlation



VI. Discussion

Evaluation of 50 cases of movement disorders in our institution from November 2015 to September 2017 i.e for a period of 22 months show most of the cases are above the age of 50 years and below 80 years

- 62% are males and 38 % are females and the most common type of presentation is tremor (76%). 10% are diagnosed to have chorea, 6% ataxia, 4% dystonia and myoclonic jerks
- 66% of patients with tremor are diagnosed to have parkinsons disease, 18% wilsons and 16% have atypical parkinsons disease
- 50% of clinically diagnosed movement disorder cases are of parkinsons disease, 14% wilsons disease and 12% are atypical parkinsons disease.

Parkinsons Disease:

In this study of 25 cases with parkinsons disease, all cases presented clinically as tremor and are above the age of 40 years. 64% of parkinson cases are males and 36% are females. 80% of clinically diagnosed parkinsons disease cases show nonspecific diffuse atrophy, 20% show mild visual decrease in the width of substantia nigra of midbrain.

Atypical Parkinsons Disease:

All cases diagnosed clinically as atypical parkinsons disease presented clinically with tremors and all of them are above the age of 50 years. 83% of atypical parkinsons disease are females and 17% males. Conventional MRI in 50% of cases diagnosed to have atypical parkinson disease show non specific diffuse cerebral atrophy. In 17% of cases MRI features are in favour of progressive supranuclear palsy and in remaining 17% and 16% features are in favour of multisystem atrophy–cerebellar type(MSA-C) and corticobasal degeneration(CBD).

Wilsons Disease:

In this study 71% of wilsons cases are females, 29% males and below the age of 40 years. All the 7 cases of wilsons presented clinically with tremors and show no atrophy. All the 7 cases of wilsons show signal changes as hyperintensities in basal ganglia. 6 cases show signal changes in pons, 5 cases in thalamus and 4 cases show signal changes in midbrain.

Ataxia:

67% of clinically diagnosed ataxia cases are in between 61- 80years and 33% between 40-60years. All the 3 cases in this study are males and show atrophy in cerebellar hemispheres. 2 cases show diffuse cerebral atrophy without atrophy of cerebellum. Signal changes in ataxia cases are most frequently seen in cerebral whitematter followed by cerebellar peduncles and pons . In this study 67% of clinically diagnosed ataxia cases show features of normal pressure hydrocephalus (NPH) and 33% of multisystem atrophy-cerebellar type(MSA-C).

Chorea:

80% of clinically diagnosed chorea cases are in between 30-70 years of age and 20% between 70-80 years. 60% of chorea cases are females and 40% males. 80% of clinically diagnosed chorea cases show nonspecific diffuse atrophy and 20% show features of hyperosmolar nonketotic hyperglycemia (HONK) .

Dystonia:

In this study, two cases of Dystonia were observed in between 20 – 30 years of age and both were males. Out of two cases of dystonia, 1 case show non specific diffuse atrophy and Other shows features of halloverdan spatiz disease (NBIA- neurodegeneration with brain iron accumulation).

Myoclonic Jerks:

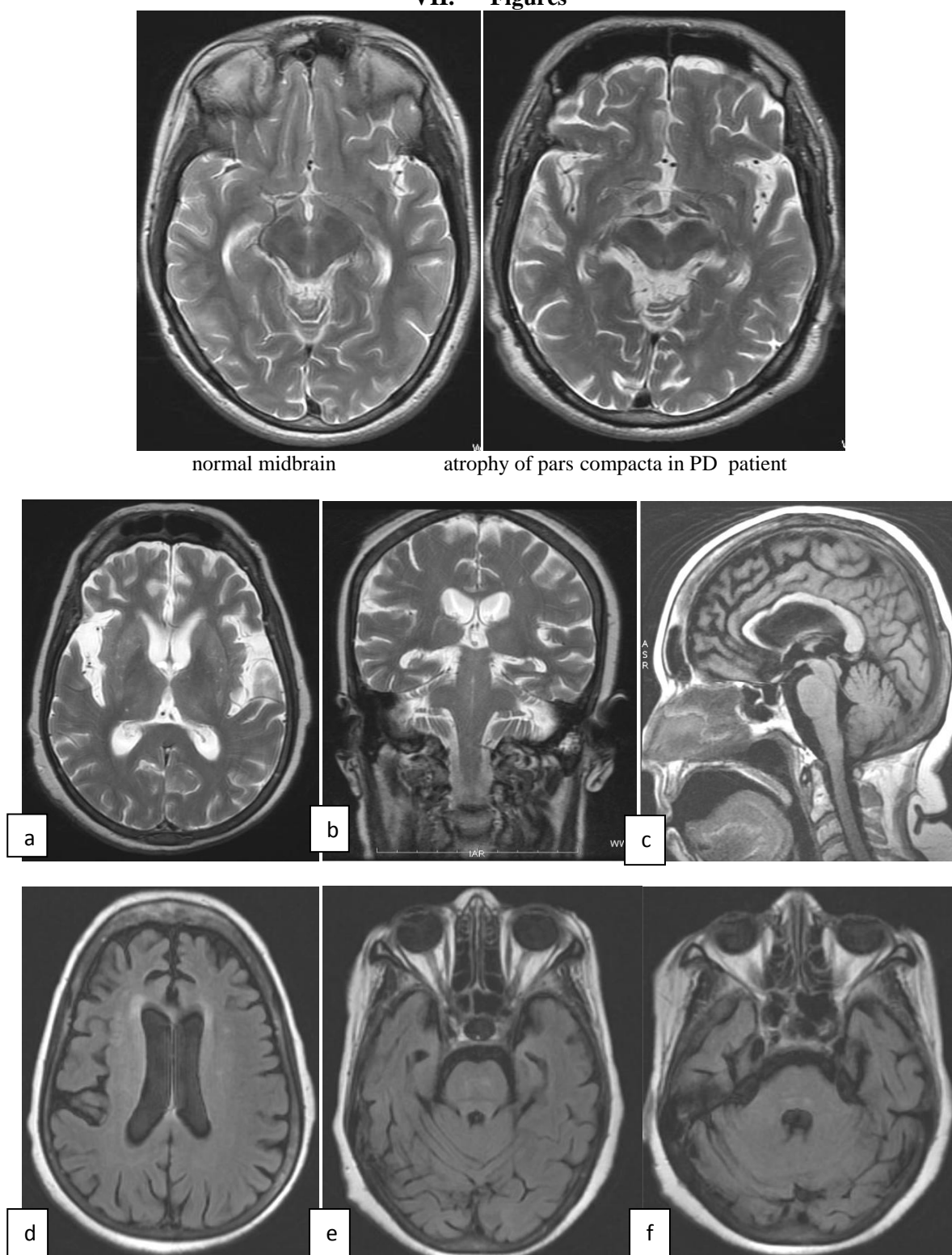
In this study of two cases of myoclonic jerks, one is from younger age i.e 23 years and the other is from old age 65 years. One is a male and the other being female.MR imaging in one of them showed features of Creutzfeldt Jakob disease (CJD) and other showed features of Subacute sclerosing panencephalitis (SSPE).

In this study of 50 cases, 6 cases are clinically diagnosed to have atypical parkinsons disease. Out of 6 cases, imaging is in favour of atypical parkinsons disease in 3 cases. These 3 cases are diagnosed by MRI as Progressive

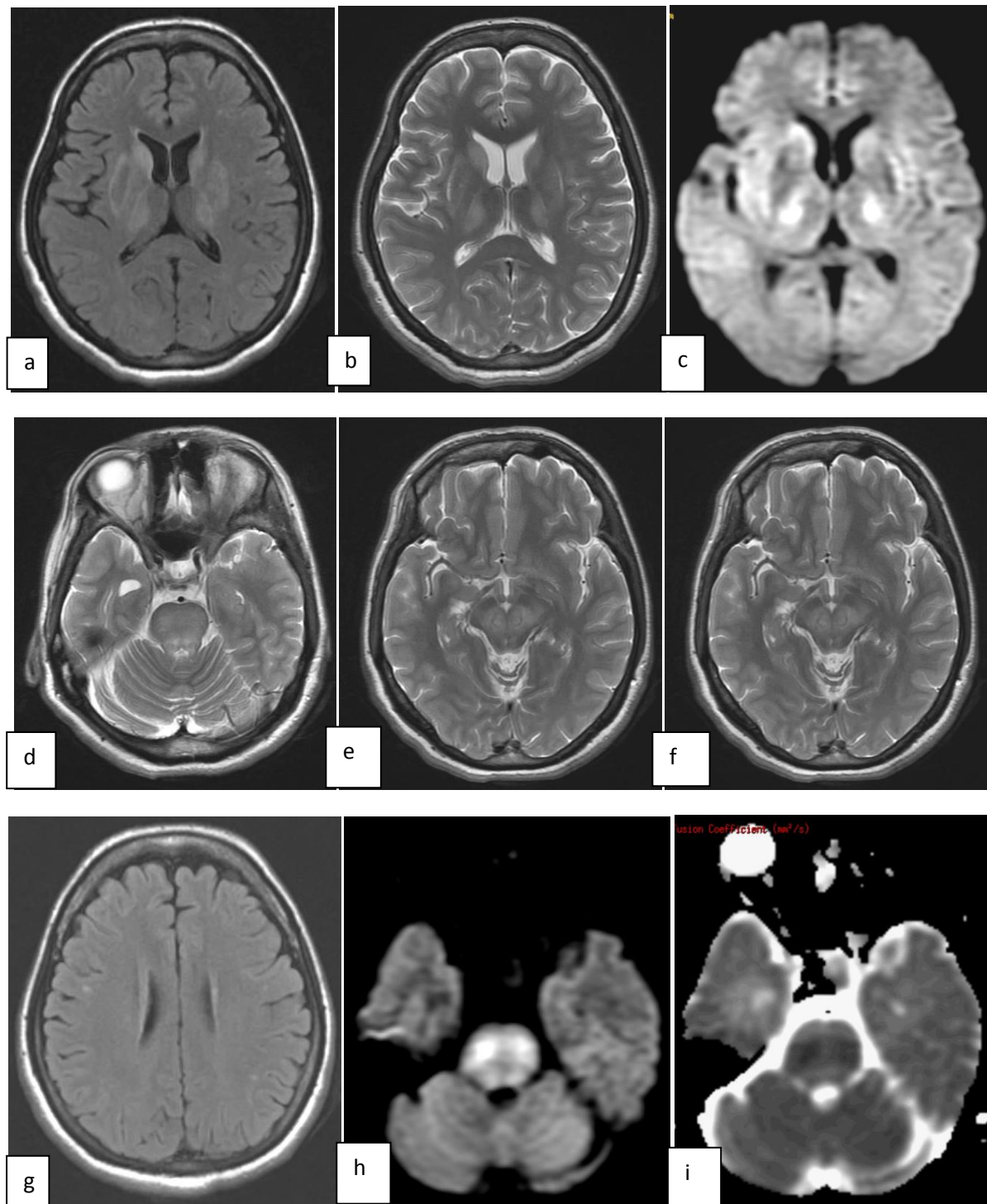
supranuclear palsy (PSP), Cortico basal degeneration (CBD) and Multi system atrophy –cerebellar type (MSA –C). Rest of the 3 cases show nonspecific cerebral atrophy. Out of 7 cases diagnosed clinically and biochemically to have wilsons, MRI showed hyperintensities in brain favouring wilsons in almost all the cases. Out of 25 cases who are diagnosed to have parkinsons disease, MRI showed visual decrease in the width of substantia nigra in only 5 cases. Rest 20 cases showed non specific age related cerebral atrophy.

No single study was done till now based only on conventional MRI evaluation of movement disorders. This study is in accordance with study of **Helen Ling, Andrew J. Lees**, (Neuroimaging Help in the Diagnosis of Movement Disorders) and correlated well with **Klaus Seppi, MD*, Werner Poewe, MD** study on Brain Magnetic Resonance Imaging Techniques in the Diagnosis of Parkinsonian Syndromes, study of **Mario Mascalchi, Alessandra Vella, MD, and Roberto Ceravolo, MD** on Role of Imaging in Diagnosis in movement Disorders and study of **A.Ranjan, J.Kalita, S.K.Kumar, S.K.Bhoi**, study on MRI changes in wilsons disease and its correlation with clinical features and outcome.

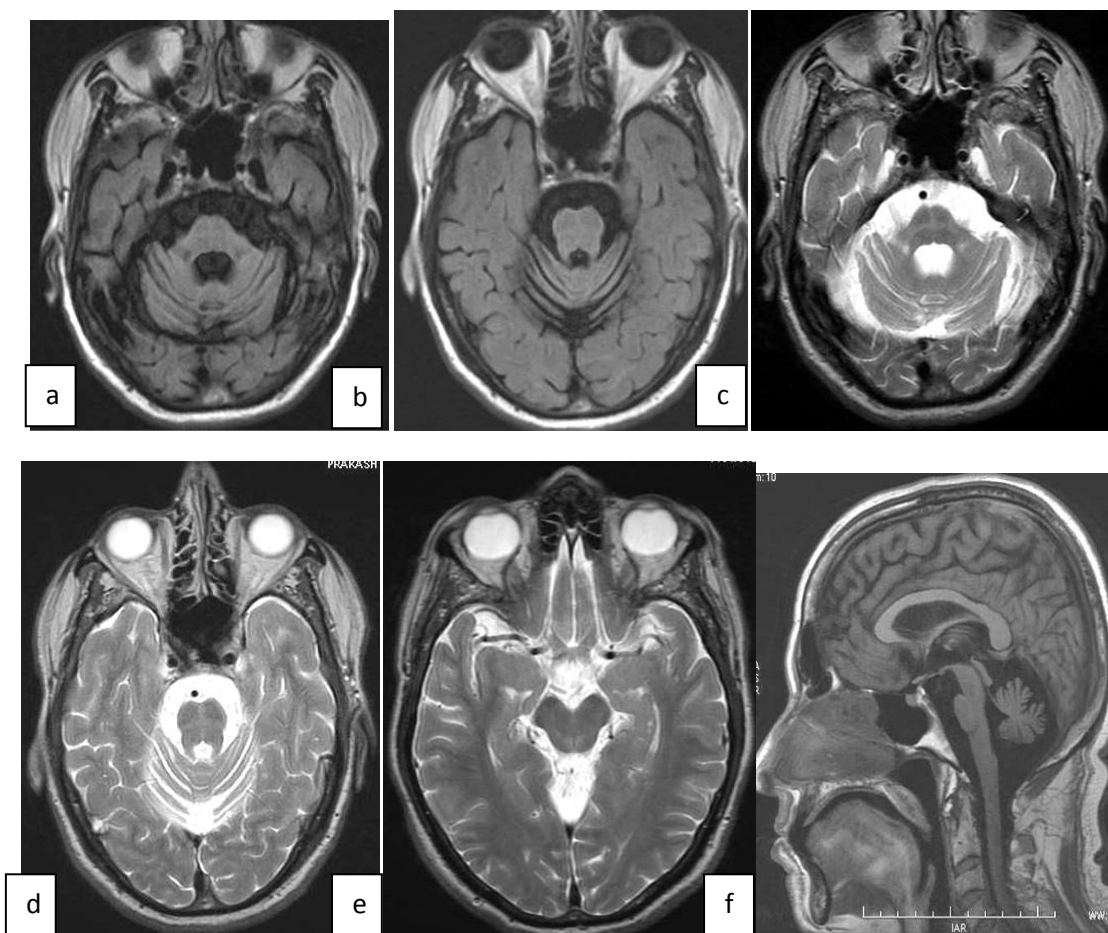
VII. Figures



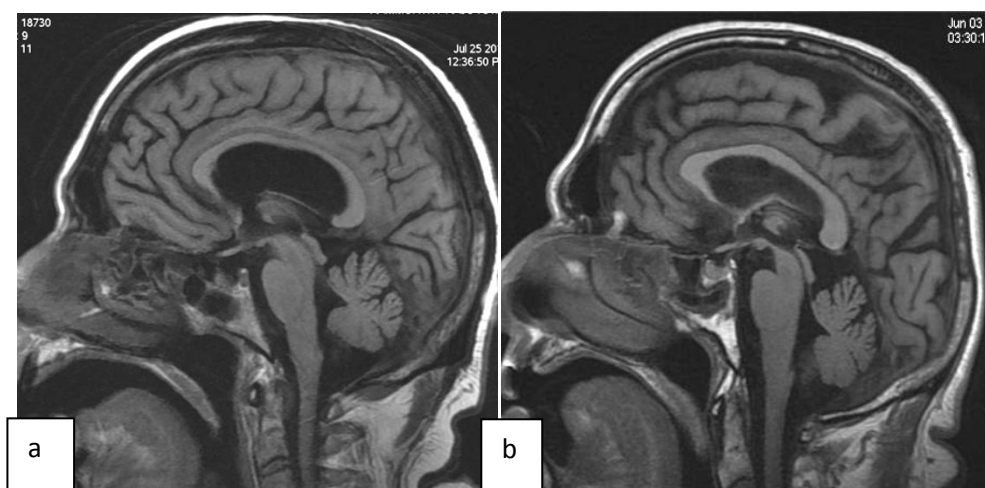
- **Figure 1 (a-f) PARKINSONS DISEASE** - Dilated ventricles with prominent sulcal ,cisternal spaces and cerebellar folia – S/o Age related Cerebral and Cerebellar Atrophy.Bilateral Decreased width of pars compacta in Substantia Nigra of midbrain .T2 and FLAIR hyperintensities noted in bilateral periventricular white matter and pons – Ischemic changes

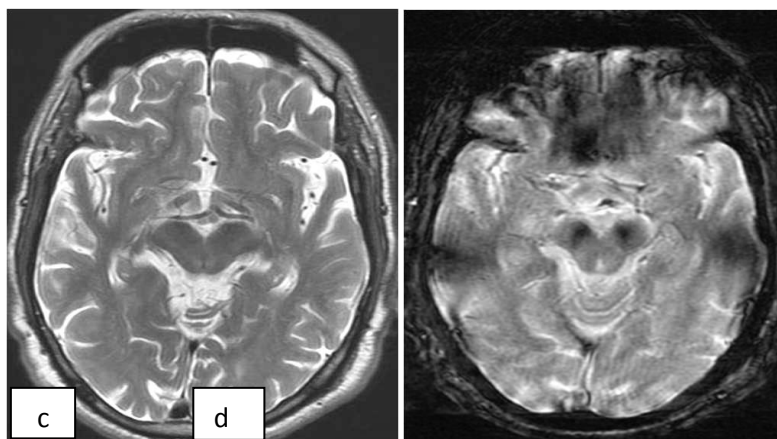


- **Figure2 (a-i)Wilson disease):**T2 and FLAIR hyperintensities with diffusion restriction noted in bilateral caudate nucleus, pons, midbrain, and thalamus.T2 and FLAIR (basal ganglia).Diffuse hyperintense signal changes noted in midbrain sparing the red nucleus and substantia nigra, featuring the “face of the giant panda” sign.

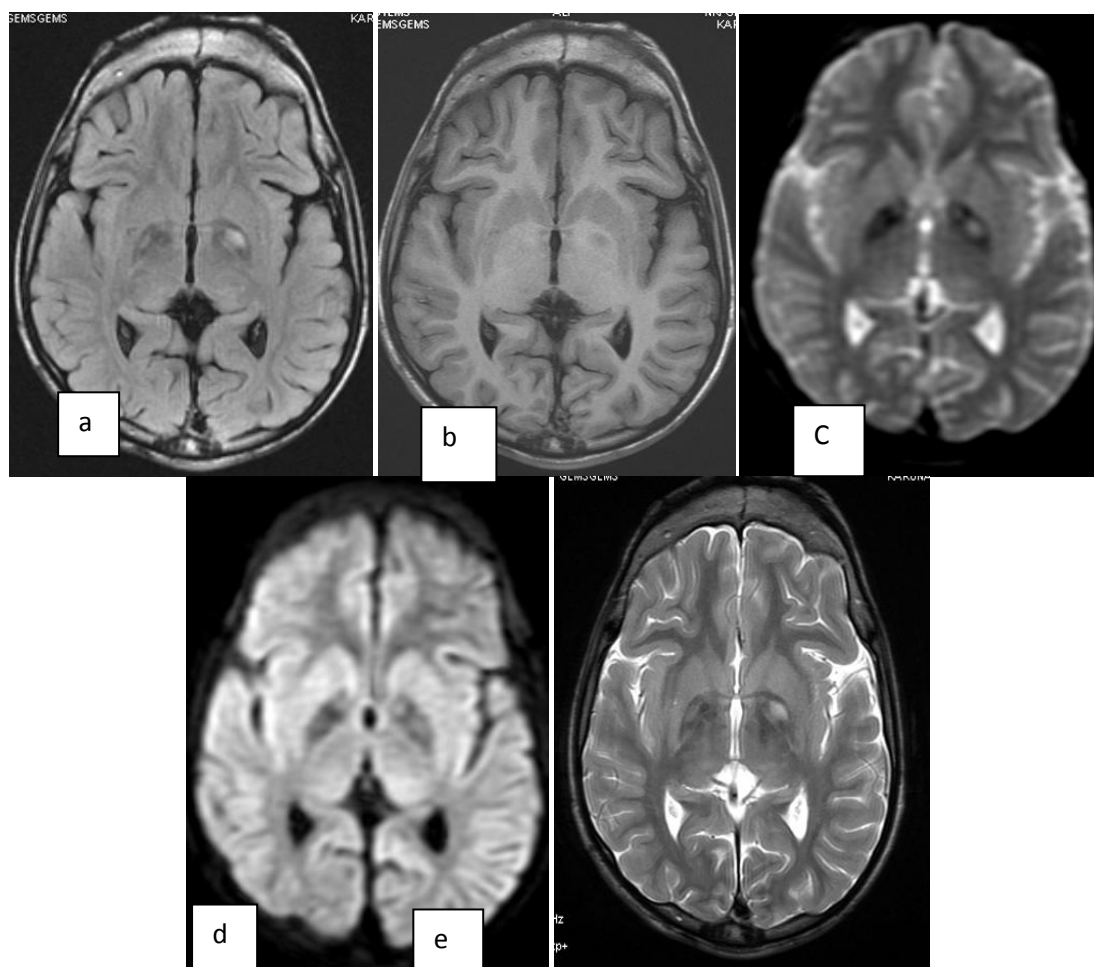


- **Figure3 (a-f) MSA** -Axial T2 W MR images shows a subtle diffuse hyperintensity of the White matter of the pons and middle cerebellar peduncles with sparing of the corticospinal tracts in the basi pontis which creates the “hot cross bun” sign . Marked thinning of the basis pontis and middle cerebellar peduncles also noted. Sagittal T1-weighted MR image demonstrates the diffuse atrophy of the brainstem, which is more pronounced in the basis pontis and prominent cerebellar folia . Cortical sulci and cisternal spaces are normal. Ventricular system is normal - Multisystem Atrophy.

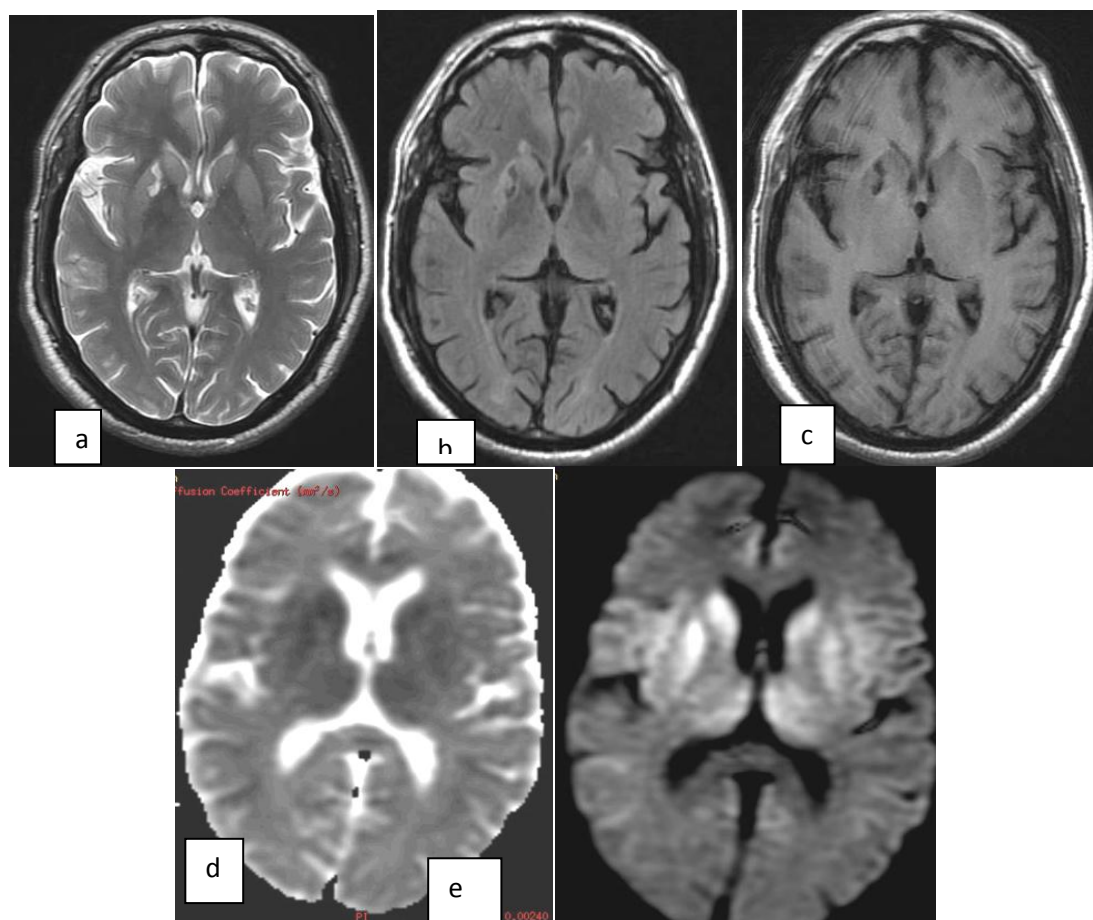




- **Figure 4(a-d) PSP** -Sagittal T1-W MR image shows the characteristic thinning of the antero posterior diameter and the abnormal shape of the rostral midbrain tegmentum exhibiting a concave upper profile and the posterior and central portions of floor of the third ventricle resembling the hummingbird's long, thin, sharp beak.
- Axial T2W and gradient MR images shows thinning of the midbrain and hypointensity of the substantia nigra.
- Prominent cortical sulci ,cisternal spaces and ventricular system – Age related diffuse cerebral atrophy : Imaging features are consistent with progressive supranuclear palsy



- **Figure 5 (a-e) NBIA(10)** -Axial FLAIR & T2 images showing characteristic symmetric hyperintensity of the central portion of the globus pallidus surrounded by a marked hypointense rim resembling the “eye of the tiger”(10) - consistent with Neurodegeneration with brain iron accumulation (NBIA).



- **Figure 6(a-e) CJD-**T2 Hyperintensities with diffusion restriction noted in bilateral basal ganglia and medial thalamus - Hockey stick sign. Cortical sulci and cisternal spaces are prominent. Bilateral periventricular ischemic changes noted - In view of clinical history, Above findings are in favour of Creutzfeldt-Jakob disease (CJD)

VIII. Conclusion And Summary

- 1) Most frequent type of clinical presentation of movement disorder is tremors which are most commonly diagnosed clinically as parkinsons disease followed by wilsons and atypical parkinsons disease.
- 2) Next most common clinical presentation of movement disorders is chorea followed by ataxia , dystonia and myoclonic jerks.
- 3) MRI findings are never diagnostic in themselves, but taken in the context of the clinical picture can point the way to the correct diagnosis.
- 4) Conventional MR Imaging with DW, standard T2-weighted, T1-weighted, FLAIR and GRE sequences on 1.5 T do not show disease-specific changes in most cases of early parkinsons disease, ataxia, chorea, dystonia and myoclonic jerks.
- 5) Conventional MR imaging is usually normal in early Parkinsons disease and in late stages show non specific diffuse cerebral atrophy.
- 6) Overall specificity of conventional MR imaging for discriminating the different Atypical parkinson diseases from PD is high, but specificity of MR imaging between the different APDs is inefficient.
- 7) Conventional MR imaging in addition with other modalities is more sensitive in diagnosing wilsons disease if there is a high clinical suspicion.
- 8) Conventional MR imaging in movement disorders takes a major part in excluding underlying pathologies such as vascular lesions, multiple sclerosis, brain tumors, normal pressure hydrocephalus, and other potential but rare causes of symptomatic parkinsonism such as Wilson disease, manganese-induced parkinsonism or different subtypes of neurodegeneration associated with brain iron accumulation.

References

- [1] Mario Mascalchi, Alessandra Vella, and Roberto Ceravolo, Movement Disorders: Role of Imaging in Diagnosis, *Journal of magnetic resonance imaging* 35:239–256 (2012)
- [2] Klaus Seppi, Werner Poewe, Brain magnetic resonance imaging techniques in diagnosis of parkinsonian syndromes, *Neuroimag Clin N Am* 20 (2010) 29–55
- [3] Helen Ling, AndrewJ. Lees, How can neuroimaging help in the diagnosis of movement disorders *Neuroimag Clin N Am* 20 (2010) 111–123
- [4] D. Dormont D.J. Seidenwurm, for the Expert Panel on Neurologic Imaging, Dementia & movement disorders, *AJNR Am J Neuroradiol* 29:204–06 Jan 2008
- [5] .Duguid JR, De La PR, DeGroot J. Magnetic resonance imaging of the midbrain in Parkinson's disease. *Ann Neurol* 1986;20:744–
- [6] Righini A, Antonini A, Ferrarini M, et al. Thin section MR study of the basal ganglia in the differential diagnosis between striatonigral degeneration and Parkinson disease. *J Comput Assist Tomogr* 2002;26:266–71.
- [7] Hutchinson M, Raff U. Parkinson's disease: a novel MRI method for determining structural changes in the substantia nigra. *J Neurol Neurosurg Psychiatry* 1999;67:815–8.
- [8] Hutchinson M, Raff U, Lebedev S. MRI correlates of pathology in parkinsonism:segmented inversion recovery ratio imaging (SIRRM). *Neuroimage* 2003;20:1899–902.
- [9] Stern MB,Braffman BH,sKOLNICKbe,Hurtig HI,Grossman RIMagnetic resonance imaging in parkinson's disease and parkinson's syndromes.*Neurology* 1989;39:1524-06
- [10] Hayflick SJ, Westaway SK, Levinson B, et al. Genetic, clinical, and radiographic delineation of Hallervorden-Spatz syndrome. *N Engl J Med* 2003;348:33–40.

Dr. Ganta Varaprasad1. " Role of Magnetic Resonance Imaging In The Diagnosis of Adult Onset Movement Disorders." *IOSR Journal of Dental and Medical Sciences (IOSR-JDMS)*, vol. 17, no. 3, 2018, pp 73-84