

Evaluation of association between sella turcica bridging and facial growth pattern.

Priyanka Chaudhari¹, Amit Nehete², Nitin Gulve³, Kunal Shah⁴, Shivpriya Aher⁵

¹(Department of Orthodontics, MGV's KBH Dental College and Hospital, Nashik, India)

²(Department of Orthodontics, MGV's KBH Dental College and Hospital, Nashik, India)

³(Department of Orthodontics, MGV's KBH Dental College and Hospital, Nashik, India)

⁴(Department of Orthodontics, MGV's KBH Dental College and Hospital, Nashik, India)

⁵(Department of Orthodontics, MGV's KBH Dental College and Hospital, Nashik, India)

Corresponding Author: Priyanka Chaudhari

Abstract: The association of Sella turcica bridging calcification & midfacial skeleton has been an area of interest for researchers. Based on evidence of common embryologic origin between sella turcica and mid facial skeleton, the aim was to determine an association between sella turcica bridging and facial growth pattern. 60 pretreatment lateral cephalograms were divided into horizontal & vertical facial growth pattern of 30 each and were traced manually with conventional method. Lateral Cephalograms were evaluated by angular measurements (SN-GoGn) to determine facial growth pattern. Sella turcica was calculated using linear measurements. To evaluate & quantify the level of sella turcica bridging, standard scoring scale by Leonard et al was used. The calculated values of chi square test were insignificant with p value 0.136. No statistical difference was found between the measurements of sella bridging & facial growth pattern. Similarly, for both growth patterns 3 different parameters i.e. Interclinoidal distance (ICD), Depth of Sella (DS), Antero posterior Diameter (APD) were measured separately, for 60 lateral cephalograms. Significant difference was observed with ICD & APD for horizontal & vertical growth, by using unpaired t-test, but DS was insignificant for both growth patterns. It was concluded that there is no significant association between facial growth pattern & sella turcica bridging. There is significant difference between ICD and APD measurements of sella turcica for horizontal & vertical skeletal growth pattern of face. Interclinoid distance & anterioposterior diameter of sella turcica is more for horizontal growth pattern than vertical growth pattern.

Date of Submission: 13-12-2018

Date of acceptance: 28-12-2018

I. Introduction

Balance between the facial features is an important part of orthodontist's responsibility. The facial growth pattern plays a significant role in planning the orthodontic treatment and its success. Early diagnosis and interceptive treatment helps to prevent complexity of treatment. The lateral cephalograms are important diagnostic tools in detecting variation in skeletal pattern with respect to skull including sella turcica bridging.^{1,2} The association of sella turcica bridging calcification & mid-facial skeleton has been an area of interest for researchers.³ In the present study we have evaluated and quantified the level of sella turcica bridging and its association with facial growth pattern. The aim of the study is to find an association between sella turcica bridging and facial growth pattern on lateral cephalograms.

II. Material and Methods

This retrospective study was carried out on digital lateral cephalogram from Department of Orthodontics at MGV's KBH Dental College and Hospital, Nasik, Maharashtra from November 2017 to December 2017. 60 pretreatment lateral cephalogram samples (both male and females) of aged 15-25 years were collected for this study.

Study Design: Retrospective

Study Location: Department of Orthodontics and Dentofacial Orthopaedics at MGV's KBH Dental College and Hospital, Nasik, Maharashtra

Study Duration: November 2017 to December 2017.

Sample size: 60

Subjects & selection method:

The digital pretreatment lateral cephalograms were selected on the basis of facial growth pattern from records of department of Orthodontics and Dentofacial Orthopaedics at MGVS KBH Dental College and Hospital, Nasik, Maharashtra. 60 pretreatment lateral cephalograms were selected, out of which 30 had horizontal growth pattern and 30 had vertical growth pattern. They were traced manually by single observer on a laminator in a dark room.

Inclusion criteria:

1. All permanent teeth were present in patients oral cavity(3rd molars were excluded)
2. Age between 15-25years were included
3. All patients had either horizontal or vertical growth pattern.
4. Clear lateral cephalograms with adequate contrast.

Exclusion criteria:

1. Patients with missing teeth or impacted teeth.
2. History of orthodontic treatment
3. Cleft lip & palate
4. Craniofacial anomalies or syndromes
5. TMJ disorders
6. Trauma to face
7. Patients with average growth pattern.

Procedure methodology

Angular measurements for measuring skeletal growth pattern of face:

A 0.003 inch acetate sheet was placed over the X-ray film and hard tissue landmarks were traced, mandibular plane (Go-Gn) and Sella-Nasion plane (S-N) were located manually using a 0.035mm mechanical black pencil. Landmarks were as shown in (Figure) -Clinoidale (Cl), Floor of Sella (SF), Gonion (Go), Gnathion (Gn) Sella (S), Nasion (N).The following planes and lines were used –

1. Sella- Nasion (SN plane): Line joining sella and nasion (Fig.1)
2. Mandibular Plane: Line joining from Gonion to Gnathion (Fig. 1)

Normal value for Sella-Nasion & Gonion-Gnathion =32 °

Horizontal growth pattern<30°

Vertical growth pattern>34 °

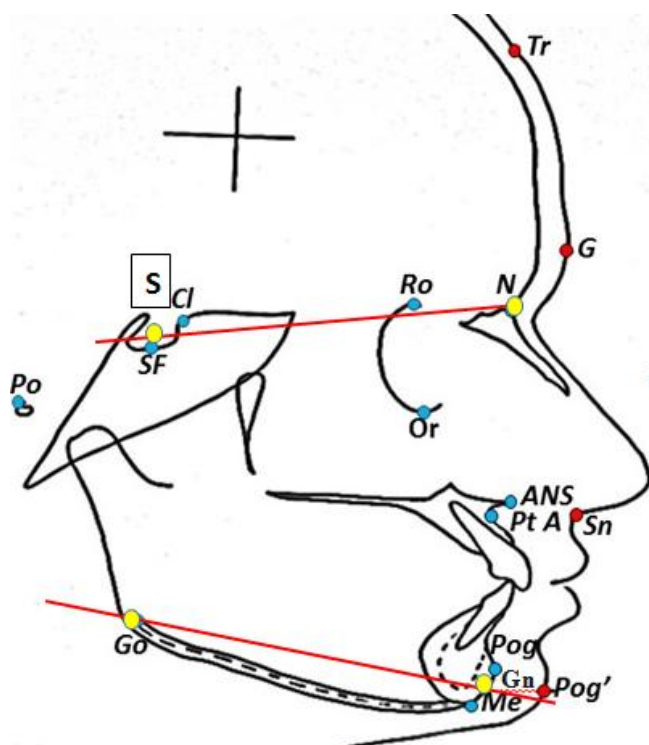


Fig.1 SN plane: Sella-Nasion, GoGn mandibular plane: Gonion Gnathion

Linear measurements for measuring sellaturcia bridging:

1. **Interclinoidal distance (ICD):** It is the distance measured from tip of dorsum sella to tuberculum sella (T.S.)
2. **Depth Of Sella (DS):** It is the distance of a line dropped perpendicular from the interclinoidal line to the deepest point on sella floor, to measure the depth of sella turcica.
3. **Anterioposterior Diameter (APD):** it is the distance from tip of tuberculum sellae to farthest point on inner wall of hypophyseal fossa.

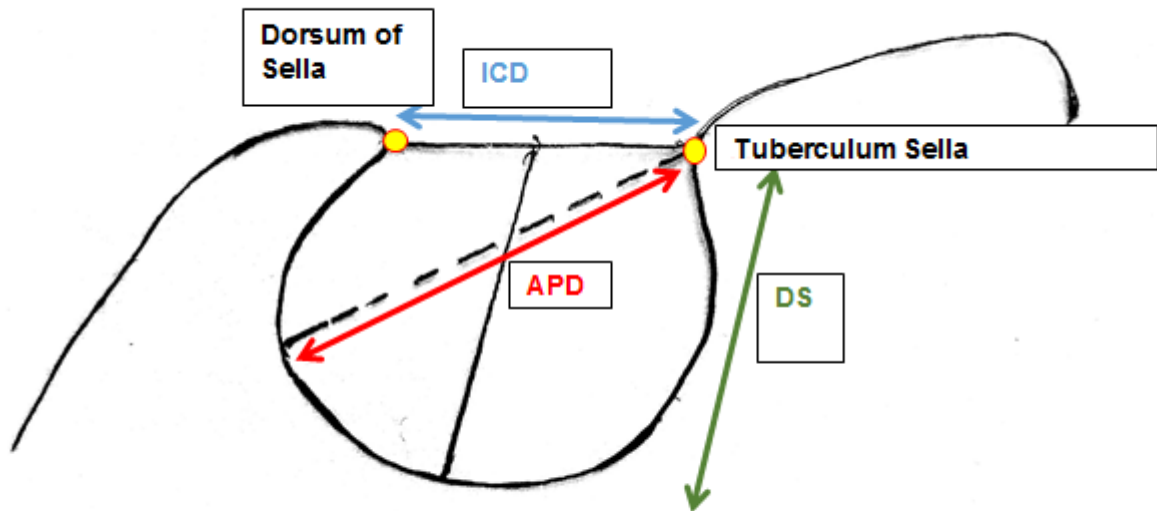


Fig.2 Interclinoidal distance (ICD), Depth of Sella (DS), Anterioposterior diameter (APD)

To evaluate & quantify the level of Sella bridging, standard scoring scale by Leonardi et al was used¹¹.

Leonardi et al standard scoring scale:

- No Calcification (Type1): The length (ICD) \geq than 3/4th sella diameter.
- Partial Calcification (Type2): Length (ICD) \leq than 3/4th sella diameter.
- Complete Calcification (Type3): Only diaphragm of sellae was visible.

III. Statistical analysis

To know if there was any association between the two skeletal growth pattern i.e. horizontal and vertical facial growth pattern and class type of sella turcica, Chi-square test of independence of attributes was applied at 95% confidence level and 1 degree of freedom to the cross tabulated data. For both growth pattern 3 different parameters i.e. Interclinoidal distance (ICD), depth of sella (DS), antero posterior diameter (APD) were measured separately for 60 lateral cephalogram samples. To identify if there was any significant difference in average value of Interclinoidal distance for horizontal and that for vertical growth pattern, unpaired t-test was applied at 95% confidence level and 58 degrees of freedom. Similarly, for remaining 2 parameters i.e. depth of sella turcica and antero posterior diameter unpaired t-test was applied.

IV. Results

The calculated value of Chi-square test statistic used to check if any association exists between two skeletal growth patterns i.e. horizontal and vertical facial growth pattern and class type of sella turcica was 2.222 which is insignificant with p value 0.1360. The obtained results of unpaired t-test used to check if any significant difference in average value of Interclinoidal distance (ICD), depth of sella (DS), antero posterior diameter (APD) for both growth patterns are shown in table1.

Table no 1

Parameters	Pair of comparison	Mean score	Standard Deviaton	Standard Error	t value	P value	Remark
Interclinoidal distance (ICD)	Horizontal	7	2.5393	0.6	2.2642	0.0273	*Significant
	Vertical	5.63	2.0929				
Depth of sella (DS)	Horizontal	7.23	1.4799	0.3873	-0.7796	0.4388	Non-significant
	Vertical	7.53	1.5033				
Anteroposterior diameter (APD)	Horizontal	10.4	2.5	0.5385	3.0435	0.0035	*Significant
	Vertical	8.77	1.5460				

Significant difference (*) was seen for Interclinoidal distance and antero posterior diameter, but depth of sella did not show any significant difference in both skeletal growth pattern.

V. Discussion

This is a retrospective study to evaluate if there is any association between sella turcica bridging and facial growth pattern on lateral cephalograms. The sample included adult pretreatment digital lateral cephalograms therefore the growth was completed in all patients. In this study the linear measurements of sella turcica were measured by method given by Silverman and Kisling.¹⁰

During development of embryo, Sella turcica and pituitary gland are important structures, as migration of neural crest cells to mid facial structures takes place. During formation of sella turcica and teeth, they share common developmental factors.^{4,5,6} Bridging of sella turcica calcification is anatomical abnormality and is associated with skeletal and dental or craniofacial abnormality.^{7,8}

Axelsson et al showed that the length of sella was constant whereas depth and diameter of sella increases with age. Filipovic et al analyzed that the size of sella turcica was smaller in class II and greater in class III malocclusion and had no difference between sexes and age.⁹

As it is common to notice sella turcica bridging with craniofacial abnormality.^{12,13} This study was done to check whether sella turcica bridging calcification helps us to predict facial growth pattern.

However, sella turcica is a three dimensional structure and cephalometry is 2-dimensional representation, this study does not provide complete and accurate information, but the results of this study can be used for an approximate idea of relation between sella turcica and facial growth pattern.

VI. Conclusion

1. There is no significant association between facial growth pattern & sella bridging.
2. There is significant difference between interclinoidal distance (sella length) and antero posterior diameter measurements of sella for horizontal & vertical skeletal growth pattern of face.
3. Interclinoid distance (sella length) & antero posterior diameter of sella is increased for horizontal growth pattern than vertical growth pattern.

References

- [1]. Sandham A. Cervical vertebral anomalies in cleft lip and palate. *Cleft Palate J* 1965;36:273-81.
- [2]. Leonardi R, Barbato E, Vichi M, Caltabiano M. Skeletal anomalies and normal variants in patients with palatally displaced canines. *Angle Orthod* 2009;79:727-32.
- [3]. Ali B, Shaikh A and Fidac M. Association between sellaturcica bridging and palatal canine impaction. *Am J Orthod*. 2014;146:437-41.
- [4]. Kjer I, Fischer BH, Reintoft I, Keeling JW. Pituitary gland and axial skeletal malformations in human fetuses with spinal bifida. *Eur J OediatrSurg* 1999;9354-358
- [5]. Miletich I, Sharp PT. Neural crest contribution to mammalian tooth formation. *Birth Defects Res C Embryo Today* 2004;72:200-212.
- [6]. Morotomi T, et al. In vitro differentiation of dental epithelial progenitor cells through epithelial-mesenchymal interactions. *Arch Oral Biol* 695-;50:695-705
- [7]. Leonardi R, Barbato E, Vichi M, CaltabianoM. Sellaturcica bridge in subjects with dental anomalies. *Eur J Othod* 2006;580-885.
- [8]. Meyer-Marcotty P, Reuther T, Stellzig-Eisenhauer A. Bridging of sellaturcica in skeletal class III subjects. *Eur H Orthod* 2010;32:148-153.
- [9]. Filipovic G, Buric M, Janosevic M, Stosic M. Radiological measurement of sellaturcica `s size in different malocclusion. *ActaStomatologicaNaissi* 2011;27:1035-1042

- [10]. Silverman FN, Roentgen standards for size of pituitary fossal from infancy through adolescence. Am J Roentgenol Radium TherNucl Med 1957;78:451-460
- [11]. Leonardi R, Barbato E, Vichi M, Caltabiano M. A sellaturcica bridge in subjects with dental anomalies. Eur J Orthod 2006;28:580-5
- [12]. Camp JD. Normal and physiological anatomy of sellaturcica as revealed by roentgenograms. Am J Roentgenol 1924;12:143-156
- [13]. Kantor ML, Norton LA. Normal radiographic anatomy and common anomalies seen in cephalometricfilms. Am J OrthodDentofacialOrthop 1987;91:414-426

Priyanka Chaudhari. "Evaluation of association between sella turcica bridging and facial growth pattern." IOSR Journal of Dental and Medical Sciences (IOSR-JDMS), vol. 17, no. 12, 2018, pp 43-47.