

## Berlin's Edema In Bundelkhand Region

Dr. Jitendra Kumar<sup>1</sup>, Dr. Punam Tiwari<sup>2</sup>, Dr. Jyoti Sharma<sup>3</sup>

<sup>1</sup>. Associate Professor & Head, Dept. of ophthalmology, MLB Medical College Jhansi, India.

<sup>2</sup>. Junior Resident, Dept. of ophthalmology, MLB Medical college Jhansi, India.

<sup>3</sup>. Junior Resident, Dept. of ophthalmology, MLB Medical college Jhansi, India.

Corresponding Author: Dr. Jitendra Kumar

**Abstract-:** Berlin's edema following blunt ocular trauma, is a condition resulting from a countercoup mechanism, which can present with varying grades of visual impairment depending on the severity of the inciting injury. It is referred to as Berlin's edema when it involves the macula. A cross sectional study was conducted among 14 patients who were attending OPD, Department of Ophthalmology, Maharani Laxmi Bai Medical College, Jhansi, Uttar Pradesh, India, over a period of 4 months from May 2018 to August 2018 and fulfill inclusion criteria. All patients underwent a complete history taken and ophthalmologic examination. Fundoscopy revealed commotio retinae, observed as an abnormal yellow discoloration in the macula. SD-OCT revealed thickening of outer retinal structures and increased reflectivity in the area of photoreceptor outer segments. The choroidal fluorescence in fluorescent angiography is absent. Acute retinal changes in commotio retinae, not associated with other retinal pathologies, were resolved without histological and functional sequelae and with excellent visual outcome. Regular follow-up is must to rule out long term sequelae of blunt ocular trauma

**Key words:** Berlin's edema, Blunt ocular trauma, Commotio retinae, Spectral domain optical coherence.

Date of Submission: 09-10-2018

Date of acceptance: 24-10-2018

### I. Introduction

Blunt trauma forms a major part of ocular trauma. Ocular trauma is a preventable public health problem throughout the world. It is one of the common causes of ophthalmic morbidity and monocular blindness in all parts of the world [1]. It causes ocular damage by the coup and countercoup mechanism or by ocular compression. Concept of coup and countercoup injury was first introduced by Courville to explain brain damage caused by blunt trauma to the head. [2,3] This was later used by Wolter to explain eye injuries during blunt trauma. [4] Where Coup injuries refer to local trauma at the site of impact (e.g., subconjunctival hemorrhage, corneal abrasions, subretinal and choroidal hemorrhages, etc.) while countercoup refer to injuries at the opposite site of the impact caused by shock waves that traverse the eye (e.g., commotio retinae). The best example of a countercoup injury is commotio retinae. Commotio retinae is typically caused by an anterior segment trauma that produces a contusion injury by a countercoup mechanism. [5] which is caused by blunt injury to the eye. [4] It is characterized by decreased vision in the injured eye a few hours after the injury. On ophthalmoscopic examination, a sheenlike well defined greyish-white opacification present at retina the blood vessels are normally seen along with "cherry red spot" in the foveal region. The opacification may involve large areas of the peripheral retina or may be confined to the macula. When it involves the macula, it is referred to as Berlin's edema. Commotio retinae was first described by Berlin in 1873. [7] The pathogenesis of commotio retinae has been elaborately studied. It was originally postulated that commotio retinae was caused due to extracellular edema [7]. In a study by Hui and associates [8] on a rabbit model, it was concluded that the severe retinal contusion was mainly due to disruption of the photoreceptor and RPE cells and partly due to breakdown of the blood-retinal barrier. Recent reports on the histopathological studies have revealed disruption or fragmentation of the photoreceptor outer segment of the retina as the most common finding in patients with commotio retinae. [9,10] Usually there is no leakage of fluid and therefore it is not considered a true edema. The choroidal fluorescence in fluorescent angiography is absent. Fortunately, the prognosis for visual recovery is good, In some cases, however, visual recovery is limited by associated macular pigment epitheliopathy, choroidal rupture, or macular hole formation. Commotio retinae is usually self limiting and there is no treatment as such. It usually resolves in 3-4 weeks [11] without any complications and sequelae.

### II. Method and Materials

All patients with blunt trauma who were attending OPD were examined and only patients with commotio retinae were included in this retrospective study conducted in the Department of Ophthalmology, Maharani Laxmi Bai Medical College, Jhansi, Uttar Pradesh, India, over a period of 4 months from May 2018 to

August 2018. The procedures followed were in accordance with the ethical standards committee on human experimentation (institutional or regional) and with the Helsinki Declaration of 1975, as revised in 2000. The necessary permission from the Ethical and Research Committee was obtained for the study. In this study, clinical findings from 14 eyes of 14 patients were evaluated 11 patients were male and 3 patients were female. All patients underwent a complete ophthalmic examination, including history, visual acuity was measured with snellen's chart, best corrected visual acuity, amsler grid, slit-lamp biomicroscopy for anterior segment evaluation, gonioscopy, tonometry for intraocular pressure measurement, Automated perimetry was performed with a Humphrey field analyzer using the C30-2 program with the SITA protocol, direct and indirect ophthalmoscopic examination with scleral indentation to rule out a retinal tear under full pupil dilatation (>6mm), fundus photography, fundus fluorescein angiography and SD-OCT of both eyes. All patients provided informed consent after getting a full explanation of the examinations. Patients were first examined on the day of or within 3 days after the trauma and observed only with conservative management for a mean of 27 days (range, 1 to 88 days) All cases exhibited a white opaque zone in the central macula following blunt trauma and did not exhibit other retinal abnormalities such as preretinal, retinal, or subretinal hemorrhages, choroidal rupture, macular detachments, or partial or full-thickness macular holes.

**Inclusion criteria:**

- 1 Patients with a definite history of recent blunt trauma to the eye of all age groups who were willing to participate were included in the study
2. Signed an informed consent taken from patients,
3. There was no history of systematic cardiovascular or nervous diseases.

**Exclusion criteria:**

1. Patients who had other retinal abnormalities such as preretinal, retinal, subretinal hemorrhages, choroidal rupture, macular detachments or partial or full-thickness macular holes,
2. patients who had perforated, penetrating ocular injury,
3. Patients with orbital injuries involving fractures,
4. Old ocular injuries >3 days before consultation at our hospital,
5. Patients who were not willing to participate in the study.

**III. Results**

**Table - clinical finding of 14 cases.**

Case	Age/Sex	Traumatic eye	Cause of trauma	BCVA Initial	BCVA Final
1	16/Male	OD	Cricketball	OD 6/9 OS 6/6	OD 6/6 OS 6/6
2	40/Female	OD	Fall	OD 6/12 OS 6/6	OD 6/6 OS 6/6
3	29/Male	OS	Wooden stick	OD 6/6 OS 6/9	OD 6/6 OS 6/6
4	12/Male	OD	Cricketball	OD 6/12 OS 6/6	OD 6/6 OS 6/6
5	27/Male	OS	Dumbbell	OD 6/6 OS 6/18	OD 6/6 OS 6/6
6	20/Female	OS	Assult	OD 6/6 OS 6/12	OD 6/6 OS 6/6
7	51/Male	OS	Fist	OD 6/6 OS 6/12	OD 6/6 OS 6/6
8	30/Female	OD	Wooden stick	OD 6/24 OS 6/6	OD 6/6 OS 6/6
9	16/Male	OD	Slipper	OD 6/6 OS 6/6	OD 6/6 OS 6/6
10	18/Male	OD	Fall	OD 6/9 OS 6/6	OD 6/6 OS 6/6
11	10/Male	OS	Cricketball	OD 6/6 OS 6/12	OD 6/6 OS 6/6
12	35/Male	OD	Wooden stick	OD 6/18 OS 6/6	OD 6/6 OS 6/6
13	28/Male	OD	Fist	OD 6/6 OS 6/6	OD 6/6 OS 6/6
14	21/Male	OS	Wooden stick	OD 6/6 OS 6/12	OD 6/6 OS 6/6

BCVA-Best Corrected Visual Acuity.

The age of patients ranged from 10 to 5 years old, Best Corrected Visual Acuties ranged from 6 /6 to 6 /24 at the initial visit. No patients had anisometropia ( $>2.0$  diopters [D]), extreme hyperopia ( $>+3.00$  D) or myopia ( $<-6.00$  D). All patients were presented with blurred vision in there affected eyes after blunt injury . On examination, best corrected visual acuity were 6/9,6/12,6/9,6/12,6/18,6/12,6/12,6/24,6/6,6/9,6/12,6/18,6/6, and 6/12 respectively in the affected eye. In all 14 eyes the anterior segments were unremarkable,except for microscopic hyphema observed in the injured eye of case 5.The intraocular pressure in both eyes were in normal range in all cases by Rebound tonometer. Fundus examination were normal in the uneffected eyes of all patients. The fundus of the effected eyes showed a normal optic disc and.were no evidence of significant scarring on ophthalmoscopy. There were no pigment in the vitreous, no retinal tear or detachment, and the posterior vitreous were intact . There were a localised area of Berlin's edema in the macular region.SD-OCT showed increased reflectivity of the line at the junction between the photoreceptor inner and outer segments (IS/OS) in the area of the opacified retina in all cases. A disruption of the inner and outer segments adjacent to the fovea were also observed.Central foveal thickness at time of presentation measured 255-278  $\mu\text{m}$ . Fluorescein angiography revealed blocked fluorescence in the macula. Repeat OCT after 1 to 3weeks showed that in all eyes, the neurosensory retinal edema had resolved and the IS/OS line returned to normal architecture. found restored photoreceptor outer segment in commotio retinae in SD-OCTa surprisingly normal pattern with central foveal thickness of 231-248  $\mu\text{m}$  and, best corrected visual acuity were 6/6 respectively in the affected eyes of all patients

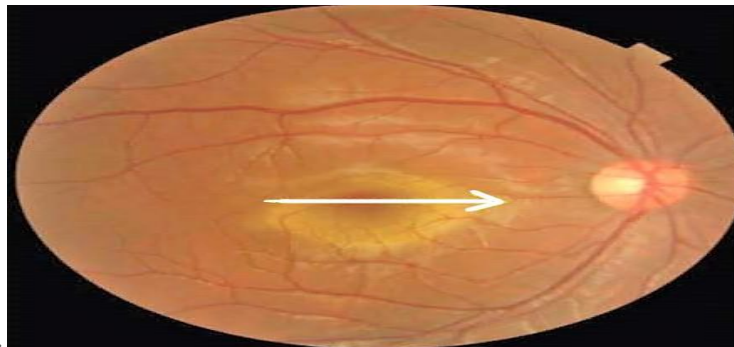

Fig 1.Right eyefundus photograph of 35 years male showing retinal opacity at the macula.

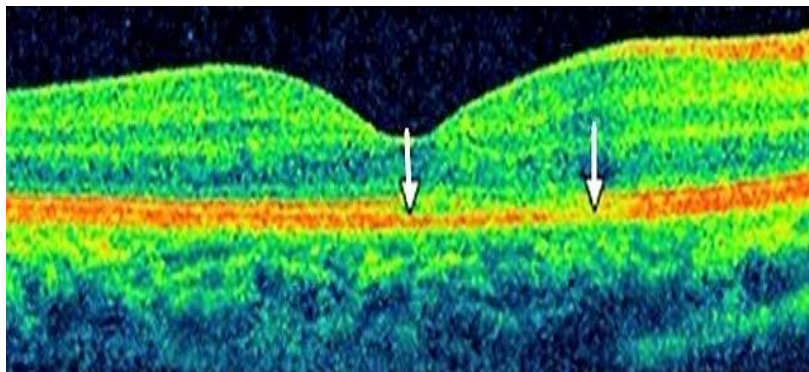


Fig 2.SD-OCT (OD) of 35 years male showing the discontinuity of the inner segment/outer segment (IS/OS) junction at the corresponding area of the commotio retinae.

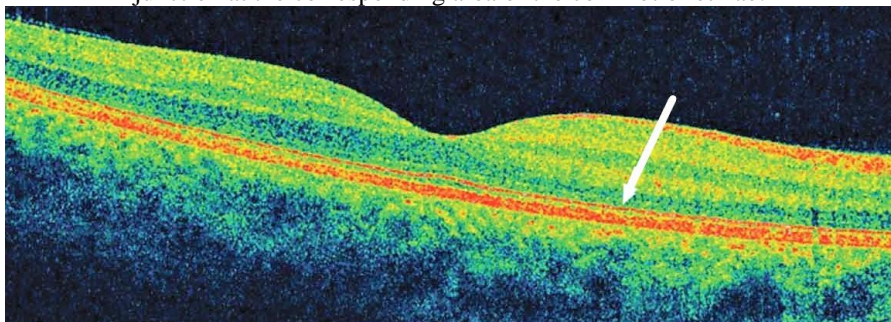


Fig.3 SD-OCT(OD) of 35 years male showing increased reflectivity in the area of the photoreceptor outer segment.

#### IV. Discussion

Berlin's edema due to blunt trauma need a thorough eye examination to detect other serious accompanying ocular injuries like globe rupture, traumatic optic neuropathy and retinal tears which may lead to retinal detachment. As such there is no treatment is recommended for patients who have commotio retinae, which may take about one to six months to resolve with recovery of vision. Treatment is essentially supportive and directed to the associated manifestations of the injury. Patients should be followed monthly initially, then by three to six months follow-up as permanent macular damage, including macular pigment epitheliopathy or macular hole formation . may lead to permanent vision loss. The visual acuity in commotio retinae varies from 6/6 to 6/120 and does not always correlate with the degree of retinal opacification. This visual loss may be transient or permanent. OCT showed involvement of the outer photoreceptor segment zone with preservation of inner retinal architecture. The major site of retinal damage seems to be at the level of the photoreceptor outer segments which correlates with histopathological study of Sipperley et al [12]. Increased reflectivity on OCT in the acute phase probably represents photoreceptor outer segment disruption, which is reversible depending on the extent of the initial trauma. Pham et al [13] revealed neurosensory retinal detachment of the fovea in a patient with acute traumatic maculopathy.

#### V. Conclusion

Any patient with a history of blunt trauma to the eye requires a complete eye examination. Commotio retinae is one of the manifestations of blunt ocular trauma. And assure the patients as it is self-limiting injury to eye if not complicated with other accompanied ocular injuries. And educate the patients about the long term implications of the injuries and the importance of follow-up .

#### Reference

- [1]. Thylefors B. Epidemiological patterns of ocular trauma. *Aust N Z J Ophthalmol* 1992;20:95-8. †
- [2]. Courville CB. Coup-contrecoup mechanism of cranio-cerebral injuries. *Arch Surg.* 1942;45:19
- [3]. Courville CB. Forensic neuropathology. *J Forensic Sci* 1962;7:1
- [4]. Wolter JR. Coup-contrecoup mechanism of ocular injuries. *Am J Ophthalmol.* 1963;56:785
- [5]. Wolter JR. Coup-counter coup mechanism of ocular injuries. *Am J Ophthalmol.* 1963;56:785-796
- [6]. Sheridan, Robert L.; Lhowe, Laurel C. (2004). *The Trauma Handbook of the Massachusetts General Hospital*. LWW Medical Book Collection. Philadelphia: Lippincott Williams & Wilkins. p. 274. ISBN 0-7817-4596-9
- [7]. Berlin R. Zur sogenannten commotio retinae. *Klin Monatsbl Augenheilk.* 1873; 1:42-78.
- [8]. Hui YN, Wu YQ, Xiao QS et al. Repair of outer blood-retinal barrier after severe ocular trauma in rabbits. *Graefes Arch Clin Exp Ophthalmol.* 1993;231:365-369.
- [9]. Blight R, Hart JC. Structural changes in the outer retinal layers following blunt mechanical non-perforating trauma to the globe : an experimental study. *Br J Ophthalmol.* 1977; 61:573-587.
- [10]. Mansour AM, Green WR, Hogge C. Histopathology of commotio retinae. *Retina.* 1992;12:24-28.
- [11]. Ghazanfari-Nasrabad, Mahdi; Amrollahi-Sharifabadi, Mohammad; Kargar-Bideh, Omidreza; Azizi-Sharifabad, Saeed (2016-01-01). "Permanent Ocular Injury Following Paintball Pellet Hit: A Medicolegal Case". *Journal of Forensic Sciences.* **61** (1): 277–279. doi:10.1111/1556-4029.12917. ISSN 1556-4029.
- [12]. Sipperley JO, Quigley HA, Gass DM. Traumatic retinopathy in primates. The explanation of commotio retinae. *Arch Ophthalmol.* 1978;96:2267–2273. [PubMed]
- [13]. Pham TQ, Chua B, Gorbato M, Mitchell P. Optical coherence tomography findings of acute traumatic maculopathy following motor vehicle accident. *Am J Ophthalmol.* 2007;143:348–350. [PubMed]

Dr. Jitendra Kumar. "Berlin's Edema In Bundelkhand Region." IOSR Journal of Dental and Medical Sciences (IOSR-JDMS), vol. 17, no. 10, 2018, pp 19-22.