

Patterns of Articular and Meniscal Lesions in Anterior Cruciate Ligament Injured Knees

Pramod.V.K¹, Joji Krishnan^{2*}

¹(Assistant Professor, Department Of Orthopaedics, Government Medical College, Trivandrum, Kerala, India)

²(Assistant Professor, Department Of Orthopaedics, Government Medical College, Trivandrum, Kerala, India)

*Corresponding author: Dr.Joji Krishnan

Abstract: ACL is the commonest knee ligament to be injured especially in athletes¹. In contrast to other ligaments, ACL rarely heals into its anatomic or physiologic position and its deficiency results in suboptimal knee kinematics ; making it highly susceptible to further injury, chronic instability, and long-term degenerative changes²⁻⁵. This occurs both at the time of index injury and also secondarily over time in the ACL-deficient knee^{4,6}. This Cross sectional study of arthroscopic ACL reconstruction done in 106 patients aged 15-50 yrs at government medical college Trivandrum, presents the spectrum of meniscal & chondral lesions in ACL deficient knees. The spectrum of chondral injuries varied from 4.7% in trochlea to 17.9% in medial femoral condyle , with lateral femoral condyle 5.7%, medial tibial condyle 9.4%, patella 14.2% & lateral tibial condyle 17%. In meniscal injuries, 61.3% had associated lateral meniscal tears as compared to 55.7 % of medial meniscal tears. Longitudinal tears (62.71%) were more common in medial meniscus, whereas complex tears (38.46%) were common in lateral meniscus.

Keywords: ACL injury, Arthroscopic reconstruction, Meniscal lesions, Chondral lesions

Date of Submission: 26-12-2017

Date of acceptance: 13-01-2018

I. Introduction

With the shift of demographic pattern and the rise of hybrid classes with new fitness trends ,India, a country set to become the youngest country in the world, is moving from the “head-injury capital of the world” to the” sports injury capital of the world”. ACL injury, the commonest ligament injured in the knee is on the rise with researchers suggesting increase of 200 to 400% in the past 10 years, is on the verge of being labeled as “ACL injury epidemic”. Despite the 'typical' mechanism of injury leading to ACL rupture⁷⁻⁹, poor rate of initial diagnosis, associated intraarticular knee lesions & its consequences are extremely common¹⁰⁻¹². Concurrent Meniscal and Chondral Injuries in ACL injured knees has been reported by many authors¹³⁻²⁴ and remains a major cause of concern and prognostic factor in long term results^{15,20,25}. Many studies have described associated meniscal and chondral lesions necessitating additional procedures, thereby increasing surgical time and complicating ACL reconstruction surgery. Our study presents the meniscal & chondral lesions and the spectrum of these lesions in ACL deficient knees. It will help in pre operative planning and patient counseling.

II. Materials And Methods

A total of 106 patients of age 15-50 yrs who underwent ACL reconstruction in our institute between July 2015 & June 2016 were included in our study. Patients with prior knee surgery / prior knee pain /Multi ligament injured knee/Intraarticular knee fractures were excluded. History, Pre operative clinical findings & arthroscopic findings were recorded using a structured questionnaire. Diagnostic arthroscopy was done in all patients and the number & degree of severity of chondral & meniscal injuries were noted at the time of reconstructive surgery. Meniscal injuries were classified as longitudinal, degenerative, flap, radial and complex²⁶. Chondral injuries were graded based on ICRS classification²⁷.

2.1 Statistical analysis

Data collected and Parameters of medial meniscal injuries, medial-sided articular injuries, lateral -sided articular injuries, lateral meniscal injuries, chondral lesions of patella, trochlea, lateral femoral condyle were entered to Microsoft excel worksheet and analysed. Percentage of each lesion was calculated to obtain the spectrum of lesions.

III. Results

3.1 Demographic profile

Of the 106 subjects, males (88%) significantly outnumbered females (12%). The average age of subjects was 26 (range 15 -50 yrs) .age distributions and frequency of involved side is given in figure 1 and table 1.

Figure 1.Age distribution

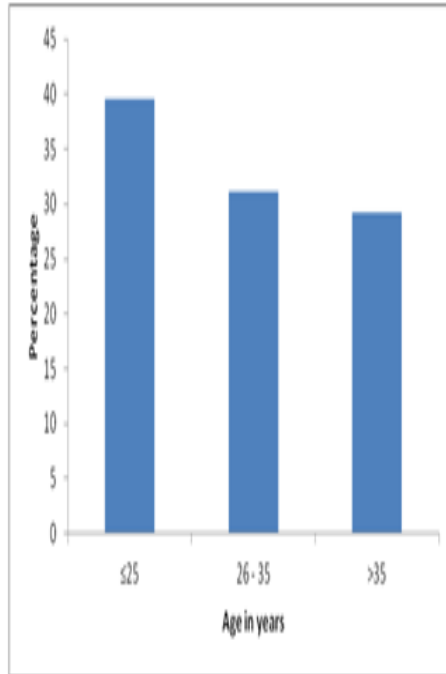
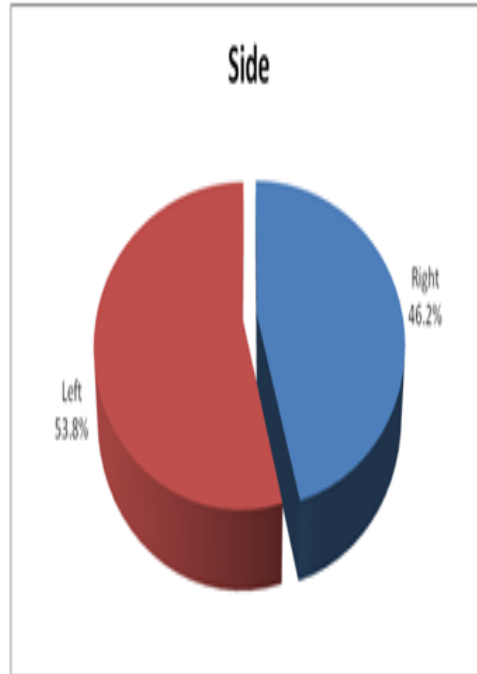


Table 1. Side involved



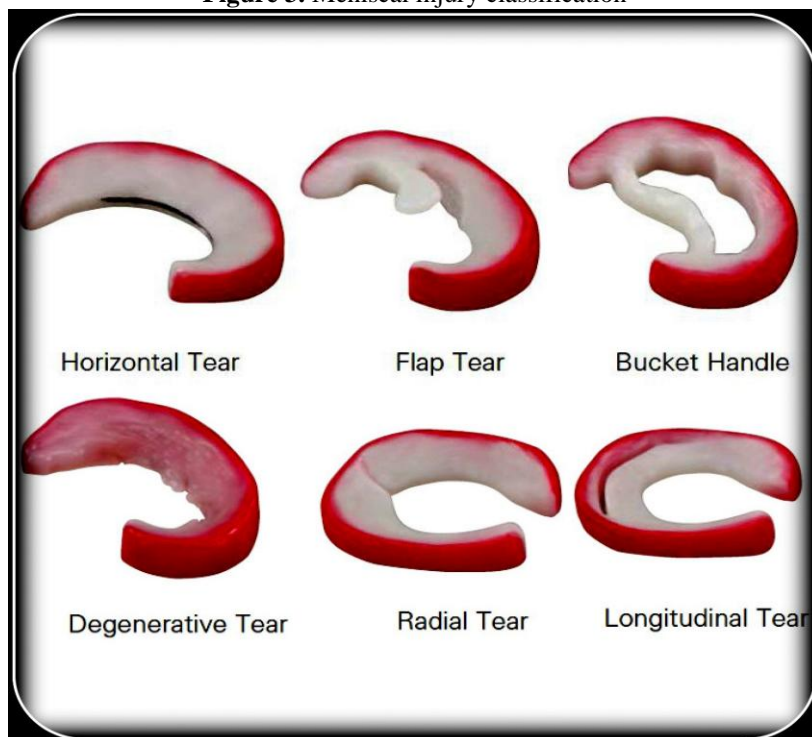
3.2 Chondral and Meniscal lesions

Cartilage injuries were classified according to ICRS classification (figure 2) & meniscal injuries were classified based on morphology & severity (Figure 3).the patterns of medial and lateral meniscal injuries are shown in table 4 &5 respectively.

Figure 2. chondral injury classification(ICRS)

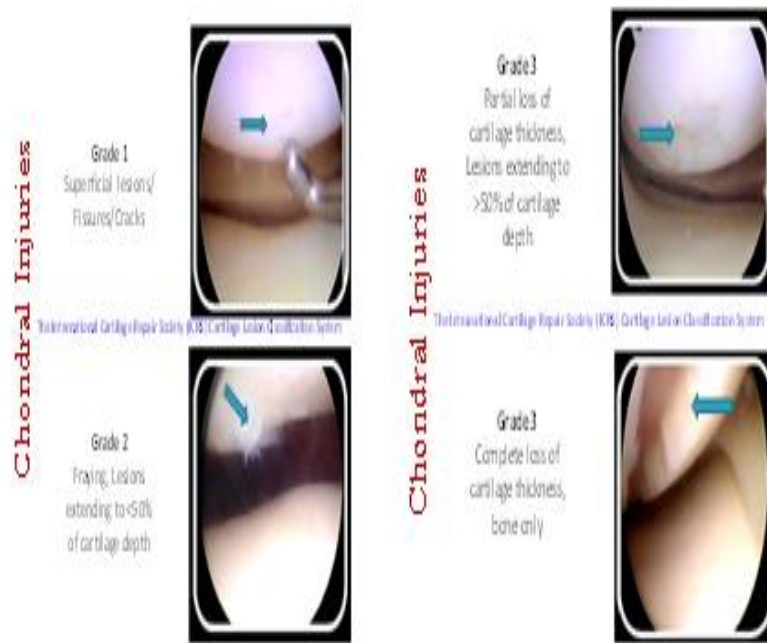

Figure 3. Meniscal injury classification



Out of 106 patients, 65(61.3%) had lateral meniscal injury as compared to 59(55.7%) with medial meniscal injury. The spectrum of chondral injuries varied from 4.7% in trochlea to 17.9% in medial femoral condyle, with lateral femoral condyle 5.7%, medial tibial condyle 9.4%, patella 14.2% & lateral tibial condyle 17%. The patterns of chondral injuries is depicted in table 6.

Table 4

Table 5

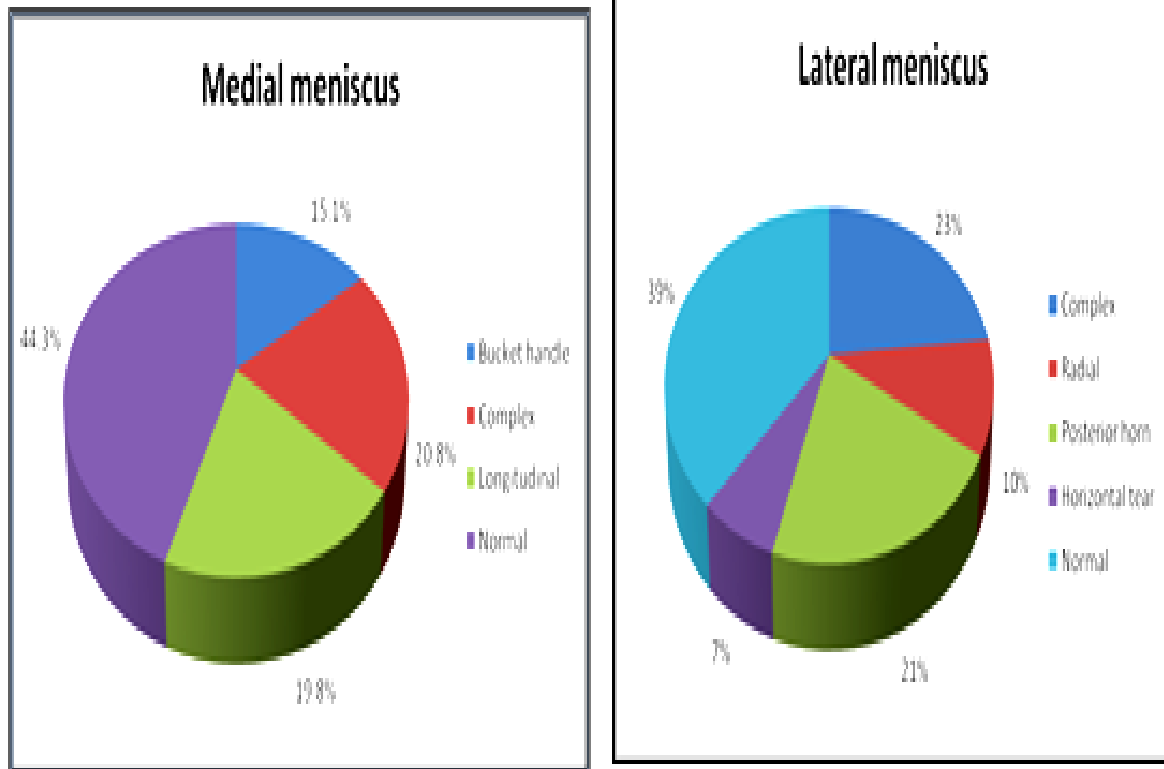
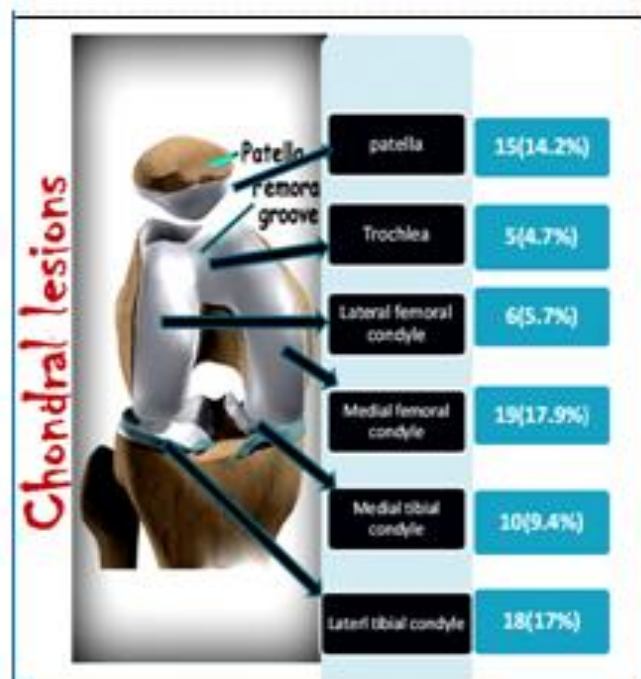


Table 6. Patterns of chondral injuries



IV. Discussion

In this study of 106 subjects, we observed that majority of patients were males (88.7%) and involvement of left knee(53.8%) was more than right. Lateral meniscal tears (61.3%) were common as compared to medial meniscus (55.7%). The mean delay to surgery from time of injury was 17.05months (2weeks to 5 years). The reported incidence of meniscal injury varied from 16% to 82% in acute ACL tears and up to 96% in chronic ACL tears; with lateral meniscal injury more often in acute ACL tears and the medial meniscal injury more in chronic ACL tears^{28,28-30}.Medial sided chondral injuries (27.3%) were common than

lateral side (22.7). Chondral injuries were least in trochlea (4.7%) and highest in medial femoral condyle (17.9%). The spectrum of lesions had lateral femoral condyle 5.7%, medial tibial condyle 9.4%, patella 14.2% & lateral tibial condyle 17%. Longitudinal tears (62.71%) were more common in medial meniscus (of which 27.1% were bucket handle tears), whereas complex tears (38.46%) were common in lateral meniscus. Tears of medial meniscus were common in subjects who were operated late after sustaining ACL injury.

V. Conclusion

ACL injury to knee in isolation without meniscal and chondral injuries are rare³¹. This study highlights the impact of ACL injury to knee joint, leading to spectrum of intraarticular knee lesions. Further studies are recommended to assess the determinants and characteristics of this spectrum of concomitant knee lesions.

References

- [1]. Anterior Cruciate Ligament: Mechanism of Injury. Available at: [https:// healthprofessions. missouri.edu/vhct/case3505/mech_injury.htm](https://healthprofessions.missouri.edu/vhct/case3505/mech_injury.htm). (Accessed: 9th June 2017)
- [2]. Lohmander, L. S., Englund, P. M., Dahl, L. L. & Roos, E. M. The long-term consequence of anterior cruciate ligament and meniscus injuries: osteoarthritis. *Am. J. Sports Med.* **35**, 1756–1769 (2007).
- [3]. Neuman, P. et al. Prevalence of tibiofemoral osteoarthritis 15 years after nonoperative treatment of anterior cruciate ligament injury: a prospective cohort study. *Am. J. Sports Med.* **36**, 1717–1725 (2008).
- [4]. Jones, H. P., Appleyard, R. C., Mahajan, S. & Murrell, G. A. C. Meniscal and chondral loss in the anterior cruciate ligament injured knee. *Sports Med. Auckl. NZ* **33**, 1075–1089 (2003).
- [5]. The Relationship between Anterior Cruciate Ligament Injury and Osteoarthritis of the Knee, Hindawi Publishing Corporation, *Advances in Orthopedics* Volume 2015, Article ID 928301, 11 pages.
- [6]. Anterior Cruciate Ligament Insufficiency: Delay in Surgery and Its Association with Spectrum of Intraarticular Knee Lesions *IOSR Journal of Dental and Medical Sciences (IOSR-JDMS)*
- [7]. e-ISSN: 2279-0853, p-ISSN: 2279-0861. Volume 16, Issue 6 Ver. VI (June. 2017), PP 40-44
- [8]. Anterior Cruciate Ligament (ACL) Injuries - What Are the Symptoms of Anterior Cruciate Ligament (ACL) Injuries: Healthwise Medical Information on eMedicineHealth. eMedicineHealth Available at: http://www.emedicinehealth.com/anterior_cruciate_ligament_acl_injuries-health/article_em.htm. (Accessed: 27th July 2016)
- [9]. Anterior Cruciate Ligament Injury (ACL). Department of Orthopaedic Surgery
- [10]. Waldén, M. et al. Three distinct mechanisms predominate in non-contact anterior cruciate ligament injuries in male professional football players: a systematic video analysis of 39 cases. *Br J Sports Med* *bjssports-2014-094573* (2015). doi:10.1136/bjssports-2014-094573
- [11]. Arastu, M. H., Grange, S. & Twyman, R. Prevalence and consequences of delayed diagnosis of anterior cruciate ligament ruptures. *Knee Surg. Sports Traumatol. Arthrosc. Off. J. ESSKA* **23**, 1201–1205 (2015).
- [12]. Wong, J. M.-L., Khan, T., Jayadev, C. S., Khan, W. & Johnstone, D. Anterior Cruciate Ligament Rupture and Osteoarthritis Progression. *Open Orthop. J.* **6**, 295–300 (2012).
- [13]. Perera, N. S., Joel, J. & Bunola, J. A. Anterior cruciate ligament rupture: Delay to diagnosis. *Injury* **44**, 1862–1865 (2013).
- [14]. Anterior Cruciate Ligament Injury: Practice Essentials, Background, Frequency. (2016).
- [15]. Evans, S., Shaginaw, J. & Bartolozzi, A. ACL RECONSTRUCTION - IT'S ALL ABOUT TIMING. *Int. J. Sports Phys. Ther.* **9**, 268–273 (2014).
- [16]. Moatshe, G., Chahla, J., LaPrade, R. F. & Engebretsen, L. Diagnosis and treatment of multiligament knee injury: state of the art. *J. ISAKOS Jt. Disord. Orthop. Sports Med.* *jisakos-2016-000072* (2017). doi:10.1136/jisakos-2016-000072
- [17]. Frontera, W. R., Silver, J. K. & Jr, T. D. R. *Essentials of Physical Medicine and Rehabilitation.* (Elsevier Health Sciences, 2014).
- [18]. Ercin, E. et al. Importance of Restricting Sportive Activity and Time from Injury to Surgery in Anterior Cruciate Ligament Reconstruction. *Open Orthop. J.* **9**, 427–431 (2015).
- [19]. Waldén, M., Häggglund, M. & Ekstrand, J. Injuries in Swedish elite football--a prospective study on injury definitions, risk for injury and injury pattern during 2001. *Scand. J. Med. Sci. Sports* **15**, 118–125 (2005).
- [20]. Crawford, R., Walley, G., Bridgman, S. & Maffulli, N. Magnetic resonance imaging versus arthroscopy in the diagnosis of knee pathology, concentrating on meniscal lesions and ACL tears: a systematic review. *Br. Med. Bull.* **84**, 5–23 (2007).
- [21]. Meniscal and Chondral Loss in the Anterior Cruciate Ligament Injured Knee (PDF Download Available). ResearchGate Available at: https://www.researchgate.net/publication/9025534_Meniscal_and_Chondral_Loss_in_the_Anterior_Cruciate_Ligament_Injured_Knee. (Accessed: 9th June 2017)
- [22]. Doral, M. N. *Sports Injuries: Prevention, Diagnosis, Treatment and Rehabilitation.* (Springer Science & Business Media, 2011).
- [23]. Rodriguez-Merchan, C. *Traumatic Injuries of the Knee.* (Springer Science & Business Media, 2013).
- [24]. Reinold, M. What has the Biggest Impact on Outcomes Following ACL Reconstruction Surgery? Mike Reinold (2012).
- [25]. Cain, E. L. et al. Variables Associated with Chondral and Meniscal Injuries in Anterior Cruciate Ligament Surgery. *J. Knee Surg.* (2016). doi:10.1055/s-0036-1593875
- [26]. Simon, D. et al. The Relationship between Anterior Cruciate Ligament Injury and Osteoarthritis of the Knee. *Adv. Orthop.* **2015**, e928301 (2015).
- [27]. Nguyen, J. C., De Smet, A. A., Graf, B. K. & Rosas, H. G. MR imaging-based diagnosis and classification of meniscal tears. *Radiogr. Rev. Publ. Radiol. Soc. N. Am. Inc* **34**, 981–999 (2014).
- [28]. Chondral Injury Classification | eORIF. Available at: <https://eorif.com/chondral-injury-classification>. (Accessed: 31st December 2017)
- [29]. Bellabarba, C., Bush-Joseph, C. A. & Bach, B. R. Patterns of meniscal injury in the anterior cruciate-deficient knee: a review of the literature. *Am. J. Orthop. Belle Mead NJ* **26**, 18–23 (1997).
- [30]. Spindler, K. P. et al. Prospective study of osseous, articular, and meniscal lesions in recent anterior cruciate ligament tears by magnetic resonance imaging and arthroscopy. *Am. J. Sports Med.* **21**, 551–557 (1993).
- [31]. Thompson, W. O. & Fu, F. H. The meniscus in the cruciate-deficient knee. *Clin. Sports Med.* **12**, 771–796 (1993).
- [32]. Wang, J. B., Rubin, R. M. & Marshall, J. L. A mechanism of isolated anterior cruciate ligament rupture. Case report. *J. Bone Joint Surg. Am.* **57**, 411–413 (1975).