

## Computed Tomography of Normal Adrenal Glands in Indian Population

\*<sup>1</sup>Sundaa Raja Perumal R, <sup>2</sup>Kanakaraj K, <sup>3</sup>Sunil Kumar

Sree Balaji Medical College Hospital, Chennai

\*Corresponding author: Sundara Raja Perumal R

**Abstract:** The aim of our study was to determine the size of normal adrenal glands in Indian population. Measurements of the adrenal glands were obtained from computed tomographic (CT) images in 70 patients, who were undergoing CT for routine clinical indications. Patients with focal adrenal nodular lesions and mass lesion are excluded from this study. The following dimensions were measured: the maximum width of body of adrenal gland, and maximum width of the medial limb and lateral limbs of both adrenal glands. The mean thickness was measured by using computed tomography images and the mean values are as follows right medial limb measured 2.90 mm (SD:0.61), right lateral limb 3.10 mm (SD:0.69), right body thickness 5.39 mm (SD:1.28), left medial measured 3.34 mm (SD:0.9), left lateral limb measured 3.15 mm (SD:0.78) and left body thickness measured 6.1mm (SD:1.23).

**Keywords:** Multi detector Computed tomography, Medial limb, lateral limb and body of adrenal gland, Size of adrenal glands,

Date of Submission: 23-12-2017

Date of acceptance:13-01-2018

### I. Introduction

The adrenal gland is named for its location adjacent to the kidneys: adrenal. The normal gland has a characteristic inverted Y, V, or T shape. The adrenal glands are small, yellowish organs that placed on the upper poles of the kidneys. Adrenal gland have 3 parts, Body, medial and lateral limb and adrenal gland is enclosed by fascia. (7). The right adrenal gland is pyramidal, and the left one is more crescentic, extending toward the hilum of the kidney. Each Adrenal gland measures approximately 4 to 5 grams in weight. The adrenal gland measures approximately 3.0 cm in width, 5.0 cm in length, and up to 1.0 cm in thickness. The right adrenal gland has a maximum width of 6.1 mm and the left adrenal gland has a maximum width of 7.9 mm (6). Proportionately, the adrenal size is larger in neonates and infants, being almost one-third of the size of the kidney (2-4). The adrenal glands (Fig 1) are routinely visualized on every computed tomographic (CT) scan of the abdomen and on most CT scans of the chest. (1). There are numerous imaging modalities including CT, MR imaging, Ultrasonography (US), and nuclear medicine imaging that can be used to evaluate the adrenal gland. CT is the primary modality for measuring the size of adrenal gland and both detection and characterization of adrenal masses. CT scans of the abdomen were done in 70 patients with no history of adrenal related disorders. Both the glands were clearly determined with respect to their location, size and shape. The length, width and central thickness of the adrenal gland measured.

### II. Materials And Methods/ Experimental Section

The study included 70 patients who were referred to Department of Radiology for CT abdomen for other abdominal and/or pelvic problems unrelated to the adrenal gland from January 2017 to March 2017 at Sree balaji medical college and hospital, Chennai. The relevant information of the patient, like age, sex, and general medical history was noted. Consent of the patient was taken. CT abdominal scans of 70 patients were obtained at 5 mm sections and the adrenal glands were reviewed. The patients had no clinically proven adrenal disorders. Of 70 patients 45 were male and 25 were female (Chart 1), ranging from 15-85 years in age (mean age: 37). An 8 slice CT with matrix size 512 x 512.

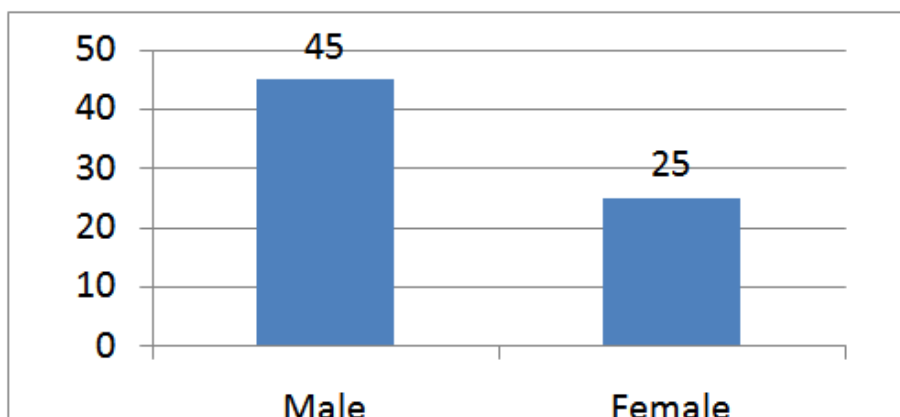


Chart 1 : Male and Female

The size of both adrenal glands were evaluated. The measurements were then recorded on a spreadsheet with 2 decimal places in the range of mm. The width of the limbs was defined as its widest dimension of the limb and thickness of the gland was determined as the thickest part perpendicular to the long axis of the gland in axial plane. (Fig 1,2,3,4).

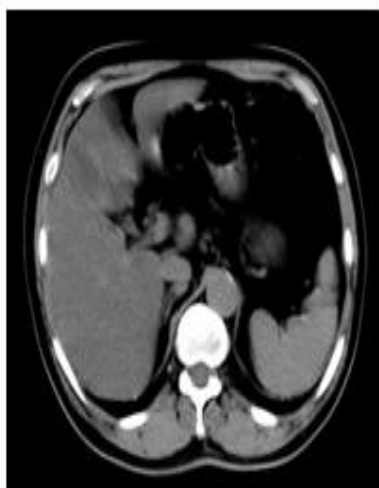

Fig 1: Normal Adrenal Gland

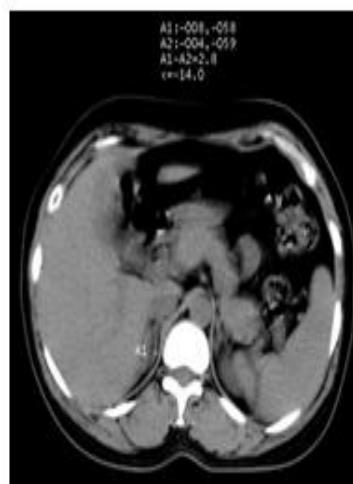

Fig 2: Medial Limb Width

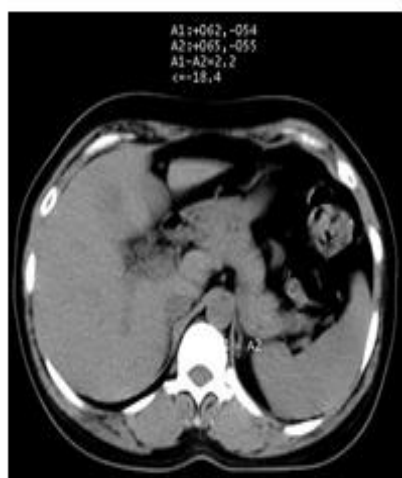

Fig 3: Lateral Limb Width

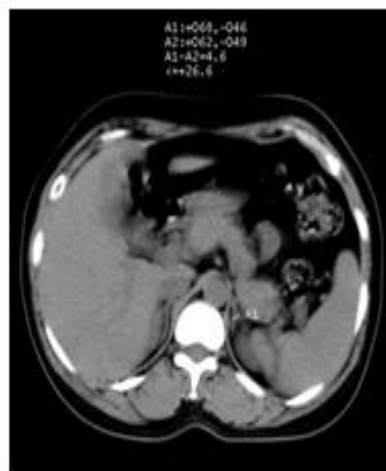

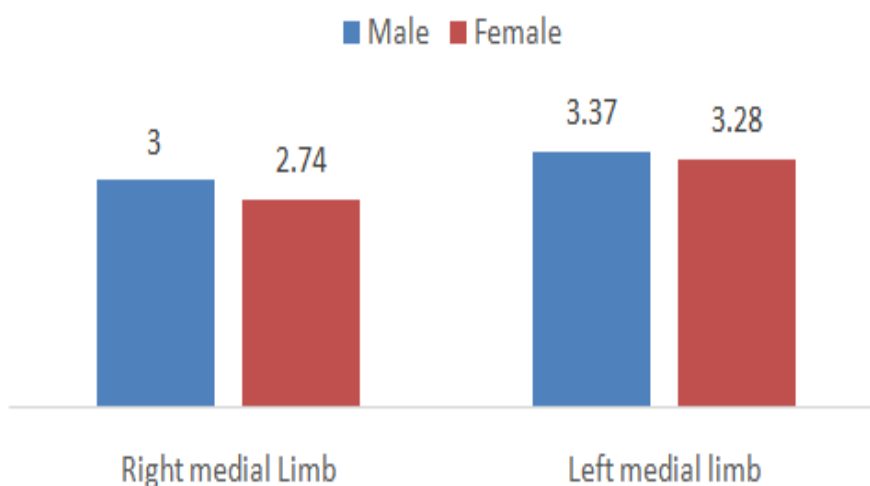
Fig 4: Body Thickness

### III. Results

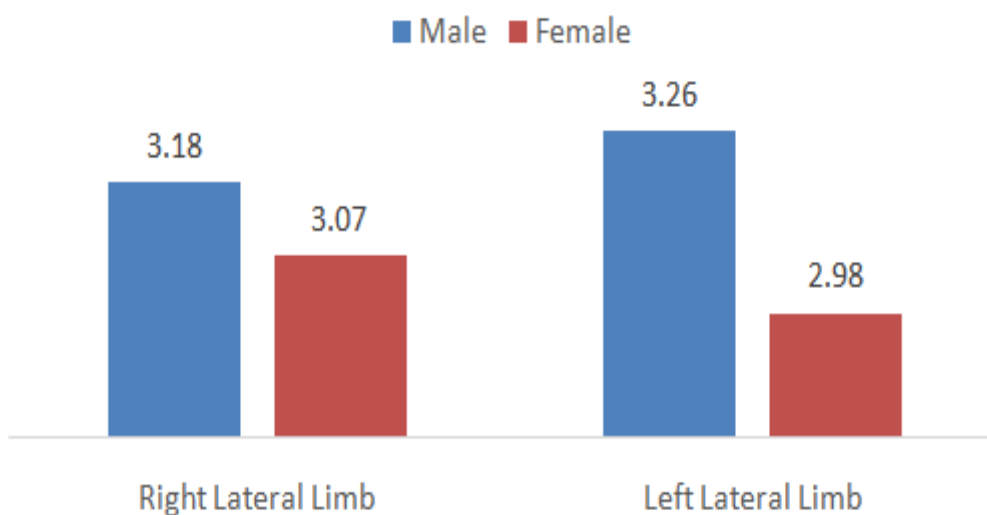
The mean thickness was determined by computed tomography and the mean values are as follows right medial limb measured 2.90 mm (SD:0.61), right lateral limb 3.10 mm (SD:0.69), right body thickness 5.39 mm (SD:1.28), left medial limb measured 3.34 mm (SD:0.9), left lateral limb measured 3.15 mm (SD:0.78) and left body thickness measured 6.1mm (SD:1.23) [Table 1].

Part	Mean (in mm)	SD
right medial limb	2.9	0.61
right lateral limb	3.1	0.69
right body thickness	5.39	1.28
left medial limb	3.34	0.9
left lateral limb	3.15	0.78
left body thickness	6.1	1.23

**Table 1** –adrenal gland measurements - mean and standard deviation



**Chart 2:** Medial Limb measurements – Male vs Female



**Chart 3:** Lateral Limb measurements – Male vs Female

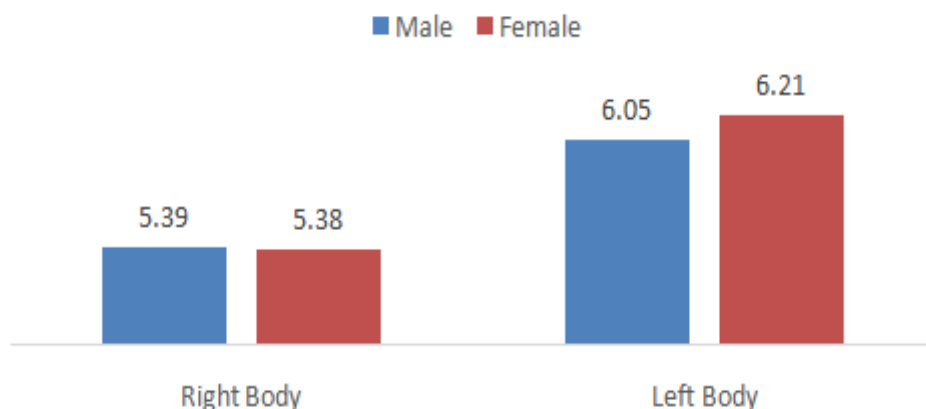


Chart 4: Body thickness measurements – Male vs Female

#### IV. Discussion

Conventional imaging approaches have distinct disadvantages, for evaluation of normal adrenal gland. Imaging modalities like radiography and Ultrasonography have limited scope in determining the normal adrenal gland. Ultrasonography can identify the adrenal gland only if it is enlarged in size considerably. Nuclear imaging methods may be used but they expose the patients to unnecessary radiation when there is no adrenal pathology present. Radioisotope scanning of adrenal gland is non invasive. It also have limited spatial resolution and radio active dose consideration. Thus, CT and MRI are required for accurate delineation of the gland and measurement of its normal dimensions. Though the adrenal gland is small in size, it was clearly delineated due to presence of retroperitoneal fat on CT imaging. Occasionally the gland may be difficult to visualise as adjacent structure like the right crus of diaphragm, posteromedial border of right lobe of liver may be closely present and clear delineation of the right adrenal gland is not possible. Similarly, clear delineation of left adrenal gland may be difficult due to adjacent structures like splenic vessels, and renal vessels. Computed tomography (CT) is the imaging procedure of choice for the evaluation of normal adrenal gland, adrenal lesions, although increasingly, magnetic resonance imaging (MRI) has their advantages. CT most accurately defines the size, location, and appearance of adrenal gland and its lesions. MRI is also an excellent study to define the full extent of an adrenal gland and its lesion, including its relationship to adjacent organs and major vessels. Its main benefit over CT is its improved ability, absence of radiation. However CT is faster than MRI in evaluating normal adrenal gland and MRI is more prone for artifacts. (8)

Positron emission tomography (PET) has been used in the evaluation of recurrent or metastatic adrenal tumors, especially neuroblastoma. <sup>[11, 12]</sup> In the present study, p value is less than 0.001 for all - age with adrenal gland measurement. No similar studies were found in Indian literature. Few international studies have been done in the past, measurement of normal size of adrenal gland. While reviewing the past literature, as we have not come across any such study in Indian population, the present study entitled: “CT measurement of normal adrenal gland size in Indian population”, was aimed to evaluate thickness of body, medial limb and lateral limb of adrenal gland. Both the values i.e. mean and standard deviation are measures of central values. In the present study, the mean is used as a central value and the standard deviation is also calculated.

The mean thickness was determined by computed tomography and the mean values are as follows right medial limb measured 2.90 mm (SD:0.61), right lateral limb 3.10 mm (SD:0.69), right body thickness 5.39 mm (SD:1.28), left medial limb measured 3.34 mm (SD:0.9), left lateral limb measured 3.15 mm (SD:0.78) and left body thickness measured 6.1mm (SD:1.23).

#### V. Conclusion

We would like to emphasize that there is hardly any data in Indian population on this issue. This study was done to assess the thickness of body, medial limb and lateral limb of adrenal gland in Indian population. This is a simple and basic science work that can add to the database of the adrenal gland size in Indian population. Literature in which thickness of body, medial limb and lateral limb of adrenal gland of normal Indian population were recorded for a significant sample size is very scarce. Our data adds to basic anatomic information of the adrenal gland size, specific to the Indian population.

#### References

- [1]. Montagne, J-P, Kressel, HY, Korobkin, M et al, Computed tomography of the normal adrenal glands. American Journal of Roentgenology. 1978;130:963–966.
- [2]. Karstaedt, N, Sagel, SS, Stanley, RJ et al, Computed tomography of the adrenal gland. Radiology. 1978;129:723–730.
- [3]. Brownlie, K, Kreel, L. Computer assisted tomography of normal suprarenal glands. Journal of Computer Assisted Tomography. 1978;2:1–10.
- [4]. Wilms, G, Baert, A, Marchal, G et al, Computed tomography of the normal adrenal glands: correlative study with autopsy specimens. Journal of Computer Assisted Tomography. 1979;3:467–469.
- [5]. Herbut, PA. Adrenals. in: Herbut PA (Ed.) Urological pathology. Vol 2. Lea & Febiger, Philadelphia; 1952:695–755.
- [6]. Meschan, I. Synopsis of radiologic anatomy with computed tomography. in: WB Saunders Co, Philadelphia; 1978:534–538.
- [7]. Soffer, LJ. The anatomy, morphologic structure, and embryology of the adrenal glands. in: Soffer LJ (Ed.) Disease of the endocrine glands. Lea & Febiger, Philadelphia; 1951:189–197.
- [8]. Ling, D, Lee, JKT. The adrenals. in: Lee JKT, Sagel SS, Stanley RJ (Eds.) Computed body tomography with MRI correlation. 2nd ed. Raven Press, New York; 1989:827–849.
- [9]. Abrams HL, Siegelman SS, Adams DF, et al. Computed tomography versus ultrasound of the adrenal gland: a prospective study. Radiology 1982; 143:121-128.
- [10]. Witteles RM, Kaplan EL, Roizen MF. Sensitivity of diagnostic and localization tests for pheochromocytoma in clinical practice. Arch Intern Med 2000; 160:2521-2524
- [11]. Kim JY, Kim SH, Lee HJ, Kim MJ, Kim YH, Cho SH, et al. Utilisation of combined 18F-FDG PET/CT scan for differential diagnosis between benign and malignant adrenal enlargement. Br J Radiol. 2013 Aug. 86(1028):20130190.
- [12]. Bagheri B, Maurer AH, Cone L, et al. Characterization of the normal adrenal gland with 18F-FDG PET/CT. J Nucl Med. 2004;45:1340–1343.
- [13]. Epstein AJ, Patel SK, Petasnick JP (1979) Computerized tomography of the adrenal gland. JAMA 242: 2791

Sundaa Raja Perumal R."Computed Tomography of Normal Adrenal Glands In Indian Population." IOSR Journal of Dental and Medical Sciences (IOSR-JDMS), vol. 17, no. 1, 2018, pp. 26-30.