

Prosthetic Rehabilitation of Resorbed Mandible With Two-Implants Supported Overdenture Using Ball Attachments: A Clinical Report

*Dr. Aprajita,²Dr. Atul Bhatnagar,³Dr. Aratee Gupta,
⁴Dr. Shankar Singh,

¹Junior Resident, ²Professor, ³Phd Scholar, Prosthodontic Unit, ⁴Junior Resident Oral and maxillofacial Unit, Banaras Hindu University Department: Faculty of Dental sciences, City: Varanasi
Uttar Pradesh India

*Corresponding author: Dr. Aprajita

Abstract: Aim: the aim of this study was to describe a technique of fabrication of two implants supported mandibular overdenture. Background: There are several treatment modalities for completely edentulous patients including conventional complete dentures, implants supported overdentures and implant supported fixed prosthesis. Patients with a severely resorbed mandible often experience problems with their conventional complete dentures. Treatment concepts involving implant supported overdentures have proven to be as satisfactory as implant supported fixed prosthesis with added advantage of ease in hygiene maintenance and less cost. Case description: This clinical report summarizes a simplified and accurate method of fabricating a two implant supported mandibular overdenture. In this case two implants were placed in the intercanine region of mandibular ridge and conventional complete denture was installed. Three months later this complete denture was converted into implant supported mandibular overdenture. Clinical significance: Conventional complete dentures have shown less satisfaction rates by patients over a period of time in terms of function. Moreover, there are researches showing increased rate of resorption with these dentures. Thus, if implant supported overdentures are used routinely into they can provide a better quality of life to edentulous patients.

Keywords : Dental Prosthesis, implant supported overdenture, ball attachments, resorbed mandible.

Date of Submission: 21-12-2017

Date of acceptance: 11-01-2018

I. Introduction

Dental implants have a significant effect on the current prosthodontic therapy for edentulous patients. Particularly, a mandibular removable implant-supported overdentures (IOD) supported by 2 or more implants is a treatment option for elderly edentulous patients who are dissatisfied with conventional complete dentures (CD). Van Steenberghe et al in 1987 were among the first authors to propose placement of only 2 implants in the edentulous mandible.¹ This option provides great patient satisfaction, chewing ability, and comfort. This article presents a design and fabrication technique of the implant-retained overdenture that uses two free-standing mandibular implants in inter-foraminal region.

1.1 Case Report

An edentulous 53-year-old male patient presented to the Department of Prosthodontics, Faculty of Dental Sciences IMS BHU Varanasi with a complaint of all missing teeth. The patient did not have any medical conditions and was not taking any medications that were associated with compromised healing. An extensive clinical and radiological examination was done. Clinical examination included an evaluation of size and shape of the edentulous ridge, palpation for undercut areas and an assessment of condition of the mucosa. Clinical examination revealed completely healed maxillary and mandibular edentulous ridges. Mandibular ridge exhibited a moderate degree of alveolar ridge resorption in posterior region. (fig 1) Overlying mucosa was healthy and normal. Temporomandibular joint examination was found to be normal. Orthopantomograph was advised to evaluate bone availability and architecture. The inter-ridge distance was assessed. Routine blood examination revealed no abnormal findings. A treatment plan was prepared after a standard protocol. It included fabrication of a conventional complete denture for the maxillary arch and a 2- free standing implant-supported overdenture for the mandibular arch. Position B and D were selected for implant placement² The patient was given a detailed explanation of the treatment protocol and duration of treatment and then informed consent was obtained from the patient. Maxillary and mandibular complete dentures were fabricated in conventional manner. Bilateral balanced occlusal scheme was done. Semi anatomic tooth form was selected.

Deflecting contacts in both centric and eccentric positions were removed. Patient was given instructions regarding maintenance of denture. The mandibular denture was duplicated and holes were made in bilateral canine positions. These holes were packed with gutta-percha points and patient was advised for dentascans for evaluating the height and width of the planned implant site. This radiographic template was prepared in (DPI self cured Acrylic resin, Clear) and was later on used as surgical template after removing the gutta percha points. Adin (Touareg TM) implants of 10 mm length and 3.5 mm diameter were selected. It was decided to use ball and socket type of attachment system.

1.2 Surgical procedure

Implant surgery was carried out in a 2-stage surgical protocol. Surgery was performed under local anaesthesia. The progressive osteotomy sites were prepared in the B and D region with the help of surgical template. Parallelism was checked by guide pins. The selected implants were placed at the prepared sites. Surgical cover screws were placed. The flaps were approximated with primary closure using 3-0 silk sutures. The patient was told avoid wearing the lower denture for two weeks following surgery. Antibiotics were prescribed for seven days. Patient was advised to use disinfectant mouth rinse (Chlorhexidine) 3-5 times daily. Instructions were given regarding oral hygiene maintenance. Patient was advised to follow semisolid diet for one week. The sutures were removed in 10 days. Post-operative Orthopantomograph was taken. (fig 2). The intaglio surface of the denture was relieved in the bilateral canine region. Soft tissue conditioning material (GC Reline Soft TM) was applied to the intaglio surface of the denture according to the manufacturer's directions and the excess liner material was removed. The denture was finished, polished and installed into the patient's mouth. Thus the patient could wear the denture during the osseointegration period without loading the underlying implants. Regular follow-up visits were done and the denture was relined as needed. Three months later the patient was planned for the second stage surgery. At this stage, the implants were exposed, the surgical cover screws were removed and healing abutments were placed, and the gingival tissues were allowed to heal for 15 days.

1.3 Loading of Implants

The comfort and fit of the dentures was checked before installation of attachments. Ball and socket over-denture abutment of 3 mm diameter was selected according to the soft tissue thickness. The soft tissue thickness was checked by Williams probe. Indirect technique of placing ball abutment was selected to avoid long chair side time. For this purpose an impression of mandibular ridge along with healing abutment was taken with addition silicone light body. A customised tray is fabricated using self cured acrylic resin. Holes were made in the indentation of healing abutments for placement of impression copings. (fig3). Healing abutments were then removed and impression copings were placed, and the fitting of tray was verified in the mouth. (fig4). Tray adhesive was applied and impression was made using addition silicone (GC Flexceed putty and light body) with direct technique. Lab analogues were attached to the impression copings. (fig5). Implants were secured with healing abutments. A cast was prepared using dental stone and ball abutment were attached to lab analogues. The attachments were placed and O rings (White) were blocked-out on the abutments. Acrylic resin from the intaglio surface of the denture was removed to allow passive fit of the denture against the abutment. A round bur was used to vent the pick up space toward the surface of the denture. The vent was situated lingual to the denture teeth. The pick-up space was half filled with self cure acrylic resin (DPI RR cold cure) and the mandibular denture was placed over the abutments. The complete seating of the denture was verified and the denture was kept in position while the resin polymerized. The excess resin was trimmed and polished in the venting area. (fig6). The ball abutments were placed in the implants with a torque of 15Ncm and complete seating was ensured with radiographs. (fig7). Fit and occlusion of the dentures was checked in centric relation position. Dentures were also checked for any deflecting contacts. (fig8). Home care instructions were given to the patient. Training of the patient to place and remove the prosthesis properly was done. Patient was recalled after 24 hours. The regular follow up was advised every three months. Patient was instructed to remove their prosthesis at night. A soft single-tufted brush was indicated to keep attachments free from plaque and food debris.

II. Discussion

The implant-supported overdenture remains in place during mandibular movements which allows the tongue and perioral musculature function properly.^{3,4} Various treatment concepts involving different numbers and types of implants, as well as different retention mechanisms, have been proposed. Bars, magnets, ball attachments, and rigid and nonrigid telescopic copings have been used to retain overdentures.⁷ In this report, ball attachment was applied because of several advantages. Two dental implants with ball attachments are usually sufficient in facilitating proper implant supported overdenture functionally¹⁰. The ball attachment is less sensitive technique, less costly, and makes peri-implant hygiene easier for older patients. In addition, it can be

used with an existing conventional denture. The ball attachments provide greater stability and more even distribution of load.¹¹ The resilient O-ring attachment was chosen as it appears to transfer stress in a more favorable manner, being a shock absorber, pressure and torque reduced.¹² As the prefabricated stock abutments are identical they can be easily replaced in case of abutment failure and does not require denture remaking. This advantage cannot be achieved in castable bar as it needs to be remade in case of failure.¹³ Malposed implants however, can be a problem as stock abutments may not compensate the alignment. In that cases inter connecting bar can overcome this issue.

No of implants : No of implants under a mandibular overdenture is debatable. Van Steenberghe et al¹ were among the first authors to propose placement of only 2 implants in the edentulous mandible. Their 98% success rate, with up to 52 months of observation, was encouraging.¹ Single implant is also quoted in literature in the symphysis region. However, a much detailed study is still required. In this paper two implant were chosen as they provide desirable denture stability without much increasing the cost factor. Another issue related with installation of the abutments in denture. There are two methods in literature. One method dictates that it can be done by indirect method that is in laboratory other one is to be done directly in subjects mouth. In this paper indirect approach was used as it provides better accuracy of the denture and less chair side time. Stoker et al. (2011) presented further data for the 8-year results of an RCT, on over 100 patients, regarding the aftercare and cost analysis with three types of mandibular implant-retained ODs. Patients with two implants showed less marginal bone loss than those with four implants, suggesting that two implants seem to be preferable for mandibular implant-supported OD.¹⁴ Marco Cune et al 2010 found no marked difference in patient satisfaction between subjects with ball-socket and bar-clip-retained two-implant mandibular overdentures at initial evaluation and after 10 years of function. Clinical and radiographic conditions were seen after 10 years of function, with slightly shallower probing depths around implants that were provided with ball-socket attachments.¹⁵ Proper maintenance is very crucial for success of any prosthesis. Regular follow up is very necessary. Adequate no of implants and emergence of abutments is important. Parallelism should be achieved for axial dissipation of forces. Treatment planning should be prosthesis driven.¹⁶ Arie R. Hoeksema et al 2016 performed a study on clinical performance of mandibular two-implant overdentures in different age groups and found them to be equally successful in younger and older patients.¹⁷

III. Conclusion

Restoration of the edentulous mandible is a challenge. A proper treatment planning is necessary regarding no of implants, design of the overdenture, and selection of the appropriate attachment system. Clinicians should plan a case according to patients need. Patients who had received implant overdenture are more satisfied with the comfort of their lower dentures and have experienced less difficulty in their daily life compared to patients with conventional mandibular dentures. Therefore, implant supported mandibular overdentures for the treatment of edentulous patients as a means to improving their quality of life should be considered.

Financial support and sponsorship: Nil

Conflicts of interest: There are no conflicts of interest.

References

- [1]. van Steenberghe, D, Quirynen, M, Calberson, L, Demanet, M. A prospective evaluation of the fate of 697 consecutive intraoral fixtures ad modum Brånemark in the rehabilitation of edentulism. *J Head Neck Pathol.* 1987;6:53–58.
- [2]. Naert I, Alsaadi G, Quirynen M. Prosthetic aspects and patient satisfaction with two-implant-retained mandibular overdentures: a 10-year randomized clinical study. *Int J Prosthodont.* 2004;17:401–10.
- [3]. Timmerman R, Stoker GT, Wismeijer D, et al. An eight-year follow-up to a randomized clinical trial of participant satisfaction with three types of mandibular implant-retained overdentures. *J Dent Res.* 2004;83:630–3.
- [4]. Oetterli M, Kiener P, Mericske-Stern R. A longitudinal study on mandibular implants supporting an overdenture: the influence of retention mechanism and anatomic-prosthetic variables on periimplant parameters. *Int J Prosthodont.* 2001;14:536–42.
- [5]. Lee Cornell K, Agar John R. Surgical and prosthetic planning for a two-implant-retained mandibular overdenture: A clinical report. *J Prosthet Dent.* 2006;95:102–3.
- [6]. Klemetti E, Chehade A, Takanishi Y, et al. Two-implant mandibular overdentures: simple to fabricate and easy to wear. *J Can Dent Assoc.* 2003;69:29–33.
- [7]. Trakas T, Michalakis K, Kang K, Hirayama H. Attachment systems for implant retained overdentures: A literature review. *Implant Dent* 2006;15:24–34.
- [8]. Walton JN. A randomized clinical trial comparing two mandibular implant overdenture designs: 3-year prosthetic outcomes using a six-field protocol. *Int J Prosthodont.* 2003;16:255–60.
- [9]. Boudrias O. P, Chehade A. Implant Overdentures: The Standard of Care for Edentulous Patients. Carol Stream, Ill: Quintessence Publishing Co; 2003. Two-implant overdentures with ball attachments: a step-by-step approach. In: Feine JS, Carlsson GE, eds; pp. 129–43.
- [10]. Staubli P. Attachments and implants. Reference manual. San Mateo, CA: Attachments Int. Inc.; 1996.
- [11]. Desjardins RP. Prosthesis for osseointegrated implants in the edentulous maxilla. *Int J oral Maxillofac Implant* 1992; 7:311–320.
- [12]. Watson GK, Payne AG, Purton DG, et al. Mandibular overdentures: comparative evaluation of prosthodontic maintenance of three different implant systems during the first year of service. *Int J Prosthodont.* 2002;15:259–66.

- [13]. Geert T. Stoker, DDS; Daniel Wismeijer, DDS, PhD Immediate Loading of Two Implants with a Mandibular Implant-Retained Overdenture: A New Treatment Protocol. *Clin Implant Dent Relat Res*, 2011; 13:255-61
- [14]. Marco Cune, Mark Burgers, Frits van Kampen, Cornelis de Putter, Andries van der Bilt ,Mandibular Overdentures Retained by Two Implants: 10-Year Results from a Crossover Clinical Trial Comparing Ball-Socket and Bar-Clip Attachments. *Int J Prosthodont* 2010 ;23:310–317
- [15]. Orientation of retentive matrices on spherical attachments independent of implant parallelism Andrew S. Wiemeyer, DMD,a John R. Agar, DDS, MA,b and Reza B. Kazemi, DMDc School of Dental Medicine, University of Connecticut, Farmington, Conn. *The Journal of Prosthetic Dentistry* volume 86 number 434-437
- [16]. Arie R. Hoeksema Anita Visser,Gerry M. Raghoebar, Arjan Vissink, Henny J.A. Meijer Influence of Age on Clinical Performance of Mandibular Two-Implant Overdentures: A 10-Year Prospective Comparative Study, *Clinical Implant Dentistry*.

Images Along With Their Legends

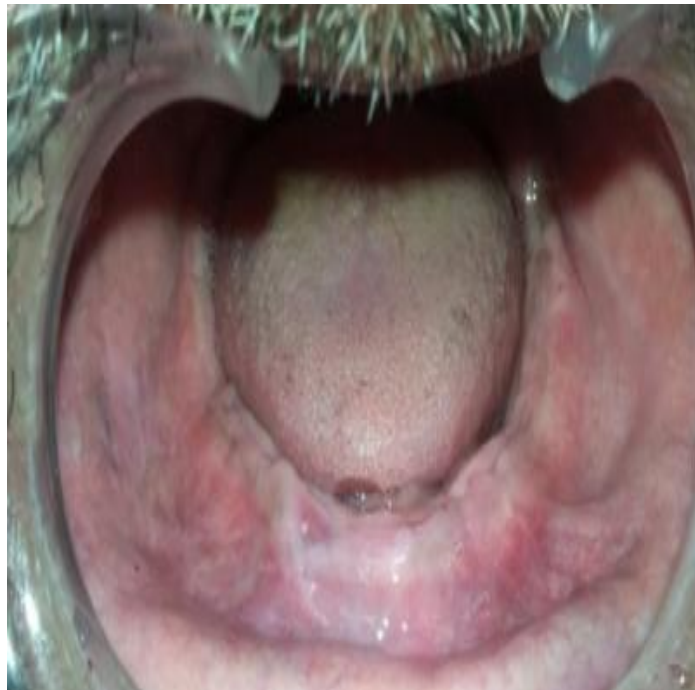

Fig 1: Edentulous mandibular ridge

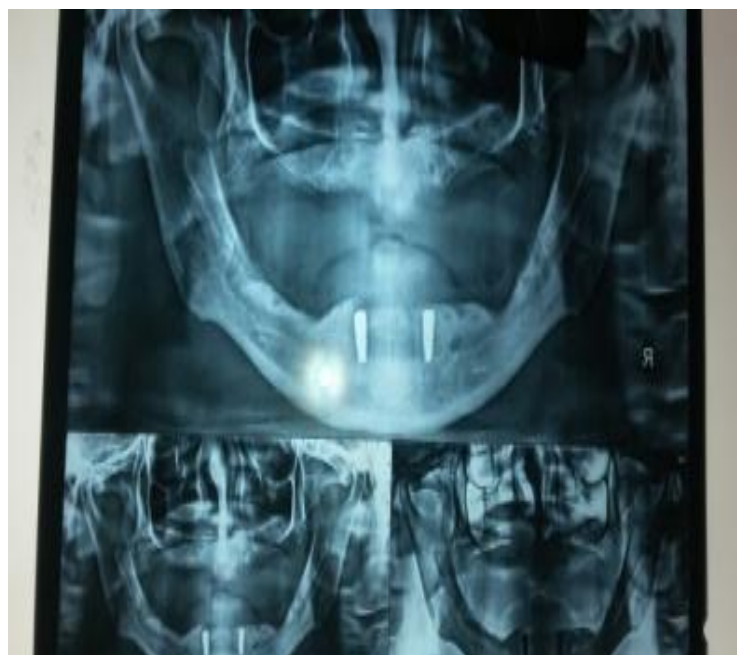


Fig 2: OPG showing implant placement in bilateral canine region.

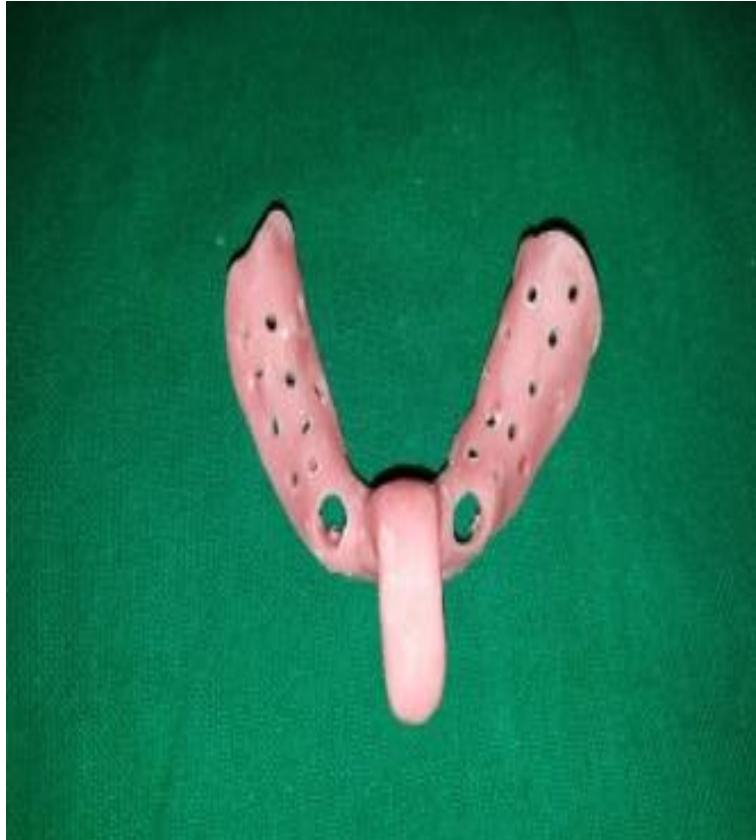

Fig 3: Acrylic tray with holes in bilateral canine region providing space for impression copings for open tray impression

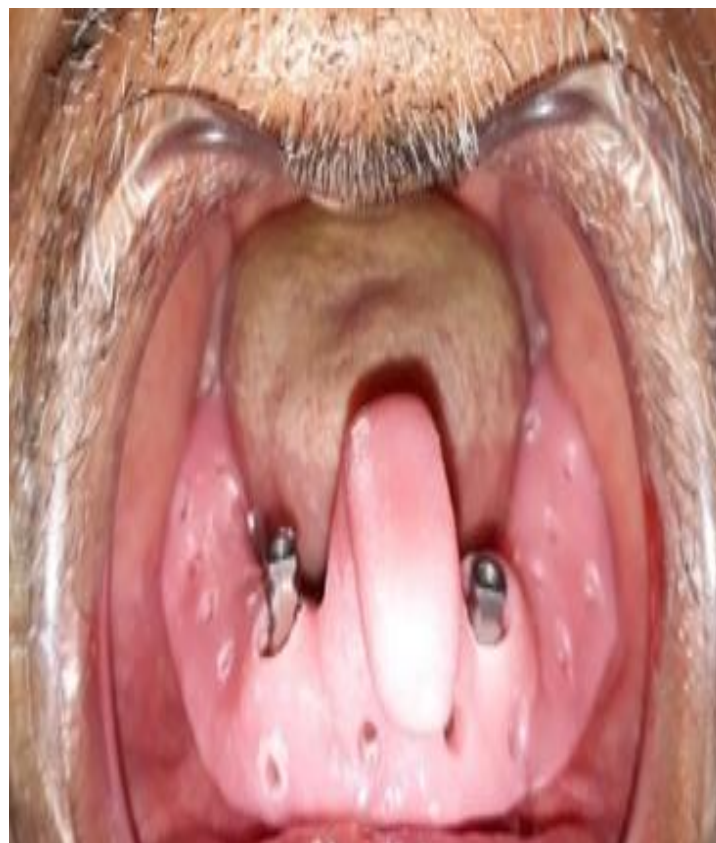

Fig 4 : Impression tray in mouth



Fig 5 : Tray with impression



Fig 6: Intaglio surface of denture with metal housing and O-rings

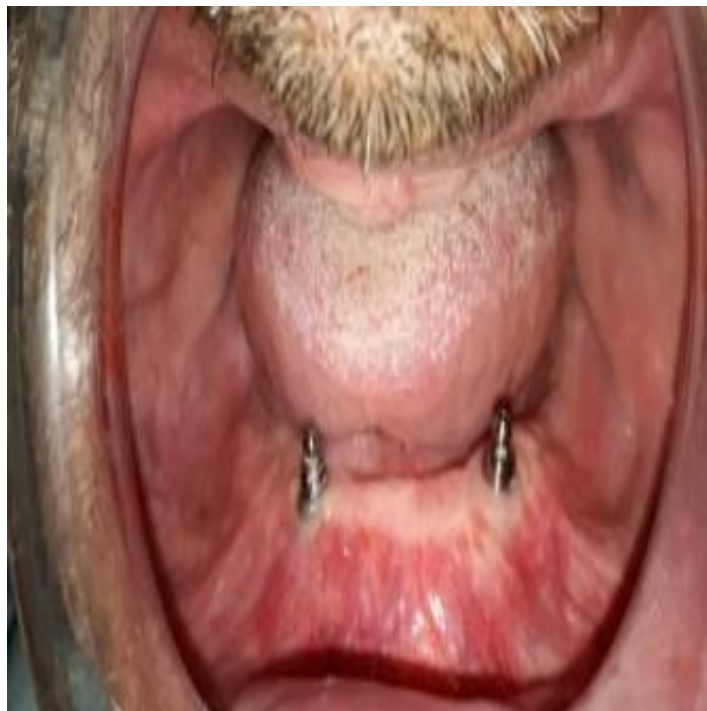

Fig 7: Ball abutments in place

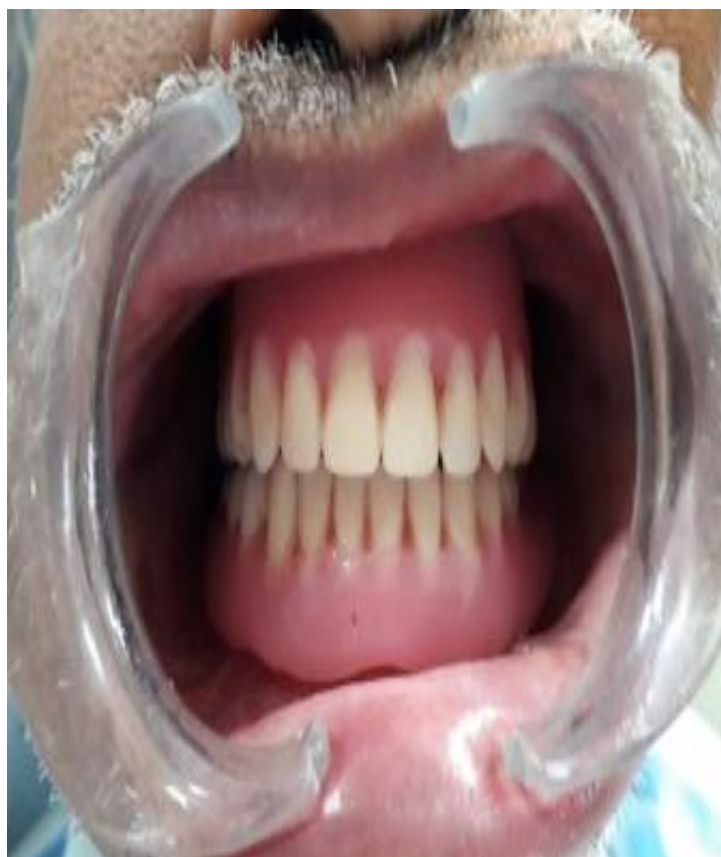

Fig 8: Complete dentures in place

Dr. Aprajita "Prosthetic Rehabilitation of Resorbed Mandible With Two-Implants Supported Overdenture Using Ball Attachments: A Clinical Report." IOSR Journal of Dental and Medical Sciences (IOSR-JDMS) , vol. 17, no. 01, 2018, pp. 21-27.