

A Rare Case of Carcinoma Gallbladder with Port Site Recurrence And Isolated Sternal Metastasis

*Himanshu Mishra¹, Rahat Hadi², Shakeel Masood³, Rohini Khurana⁴,
Ritusha Mishra⁵

¹Dr. Rahat Hadi- Associate Professor, Department Of Radiation Oncology, DR RMLIMS, Lucknow

²Dr. Shakeel Masood- Associate Professor, Department Of Gastrosurgery, DR RMLIMS, Lucknow

³Dr. Rohini Khurana- Professor (Jr.), Department Of Radiation Oncology, DR RMLIMS, Lucknow

⁴Dr. Ritusha Mishra- Senior Resident, Department Of Radiation Oncology, IMS, BHU, Varanasi

⁵Running Head- Carcinoma Gallbladder With Port Site Recurrence And Sternal Metastasis.

S/O- Dr O. P. Mishra, 154-Janki Nagar, P.O.- Bazardeeha, Varanasi, U.P., India

Corresponding Author: Dr Himanshu Mishra,

Abstract: Carcinoma gallbladder ranks sixth among all gastrointestinal malignancies. It might be diagnosed incidentally after laparoscopic cholecystectomy for benign diseases, but incidence is rare and few of such patients are at increased risk of developing port site recurrence. Isolated bone metastasis is also rare in carcinoma gallbladder and only few cases are reported in literature. Here we report a unique case of carcinoma gallbladder with port site recurrence and isolated sternal metastasis.

Keywords: Gallbladder, Recurrence, Metastasis

Date of Submission: 02 -01-2017

Date of acceptance: 23-08-2017

I. Introduction

Carcinoma gallbladder constitutes 2%-4% of all malignant gastrointestinal tumours (1). It is a highly fatal disease. At presentation, about 25% of the gallbladder tumours are localized to gallbladder wall, 35% have loco-regional disease and 40% have distant metastasis (2). For resectable disease, surgery is the treatment of choice. Various available surgical options are simple cholecystectomy, radical or extended cholecystectomy depending on disease extent. Simple laparoscopic cholecystectomy (LC) for benign disease may incidentally reveal gall bladder cancer and about one-sixth of such patients may develop port site recurrence later on. Liver is the most common site of distant metastasis. Bone metastasis is rare in carcinoma gallbladder especially isolated bone metastasis. The present article is first of its kind reporting a case of carcinoma gallbladder with port site recurrence and isolated sternal metastasis with brief literature review.

Case Presentation

A 42- years old female, known post-operative case of carcinoma gallbladder (underwent LC outside the institution for some unknown reason 7 years back and histopathology report came out adenocarcinoma of gall bladder, stage was unknown and she didn't receive any adjuvant treatment) presented 3 years back with complain of a nodule around surgical scar over abdomen on routine follow-up. On complete physical examination a small, about 1.5X 1.5 cm nodule (non-tender with no associated ulceration or discharge) was present around the surgical scar in the epigastric region. Other no abnormality was detected. Contrast enhanced computed tomography (CECT) of abdomen revealed a 1.5X1.7cm necrotic soft tissue density mass lesion in anterior abdominal wall along the surgical scar in epigastrium. No lesion was found at gallbladder fossa region. Fine needle aspiration cytology (FNAC) from the scar nodule came out positive for adenocarcinoma. CECT thorax was normal. Patient was further managed with staging laparoscopy + wedge resection + liver HDL + sampling of HDL node. Post-operative histopathology report revealed metastatic adenocarcinoma. Closest margin was 2 mm away from the tumour and all the dissected lymph nodes were negative for malignancy. Patient was further treated with 6 cycles of Cisplatin and Gemcitabine based chemotherapy (CT). Patient was then kept on follow-up.

Patient remained asymptomatic for next 2 years and after then she again presented with a nodule around the surgical scar at the same site. She was also having a painful swelling over sternum. On physical examination, a 2x2 cm nodule was present around the surgical scar at the previous site of recurrence. It was not associated with any pain/tenderness, ulceration or any discharge. There was also a 4x4 cm fixed, firm, painful swelling present over sternum. There was no associated ulceration or discharge. Skin over the swelling was warm, however there was no skin involvement. FNAC from the scar nodule was positive for adenocarcinoma.

Bone scan revealed isolated sternal metastasis. CECT Thorax revealed destruction of sternum (Figure 1). Positron Emission Tomography (PET) scan showed FDG avid lesion around the surgical scar over anterior abdominal wall and over sternum. No other lesion was detected.

Patient was then managed with palliative radiotherapy (RT) to sternum and scar recurrence site. Sternum was treated with single fraction RT dose of 8 Gy while scar recurrence site received 30 Gy/ 10#, single # / day, 5 days in a week. After palliative RT, scar nodule flattened (Figure 2) and patient also had partial subjective response in pain over sternal swelling. Patient is alive, on follow-up for last 1 year and is symptomatically well.

II. Discussion

The incidence of gall bladder carcinoma increases with age and the threat is maximum in 7th decade of life (3). Females are 3 times more predisposed for the disease as compared to males (4). In the present case also patient is female but she belongs to middle-age group. LC is considered as standard surgical treatment for benign gallbladder diseases such as cholelithiasis (and many others), but it is usually not preferred for advanced gall bladder cancers. However, carcinoma gall bladder might be incidentally found during or after LC and the incidence varies from 0.25-3% (5,6,7,8,9). Patients who underwent LC and diagnosed to have unexpected gall bladder cancer (during or after the procedure) are at increased risk of developing port-site recurrence. Incidence of port site recurrence after LC for preoperatively unsuspected gallbladder carcinoma may vary from 14-29% and it may occur even in early stages of the disease (10,11,12,13). In the present case we don't know the preoperative stage of the disease as the patient was operated outside the institution about 4 years before presenting with port site recurrence. Time gap between LC and port site recurrence may vary from few weeks to 3-4 years (14,15). In our case it is 4 years.

It is suggested that owing to its specific procedures and techniques involved, laparoscopy increases the chances of port- site recurrence. Multiple reasons for port-site recurrence have been explained like cancer cell seeding through laparoscopic instruments or aerosolization, local immunological or metabolic effects of CO₂ gas and peritoneal effects of pneumoperitoneal pressure.

Patients having port site recurrence are at high risk of developing peritoneal dissemination and distant metastasis. Management typically includes PET / CECT scans to exclude distant disease. Wide excision of the port site is recommended if there is no distant metastasis. If there are evidence of peritoneal seeding, cytoreductive surgery along with perioperative intraperitoneal chemotherapy administration should be done. Palliative RT provides good symptomatic relief at scar recurrence and distant metastatic sites like in the present case. CT is also an option for scar recurrence and distant metastasis. In the present case at the time of first port site recurrence there was no metastatic disease (as depicted in PET-CT), so the patient was first treated with wedge resection of the scar lesion . In view of port site recurrence and close margin in resected sample patient was further managed with CT. When the patient had the scar recurrence 2nd time, she was also having painful sternal metastasis; thus managed with palliative RT.

For carcinoma gallbladder, the most common site of metastasis is liver and most common site of extra-abdominal metastasis is lung. Carcinoma gallbladder seldom metastasizes to bone. There are only few case reports of carcinoma gall- bladder metastasizing to bone. Bone metastasis is usually seen in advanced stages of the disease. In the present case it was seen with port site recurrence while the primary post-operative bed was disease free and sternum was the only site of skeletal metastasis as evident on both bone scan and PET scan.

Bone scan must be done in such cases to know the extent of skeletal involvement. Bone metastasis is usually associated with poor prognosis. Palliative RT and/or CT could be offered to such patients for symptomatic relief and to check further disease progression.

Incidental diagnosis of carcinoma gall bladder after LC is unusual. Incidence of port site recurrence in such cases is low and reappearance of port site recurrence is more unusual. Isolated bone metastasis in carcinoma gall bladder is further rare. So this is the first case reporting repeated port-site recurrence along with isolated sternal metastasis in carcinoma gall bladder according to our best knowledge in English literature.

III. Conclusion

So according to the present report we suggest careful skeletal survey should be done in carcinoma gall bladder patients with port site recurrence. Imaging modalities like PET-CT, CECT, Bone scan must be incorporated as part of management to rule out distant metastasis especially to bone.

Acknowledgements

None

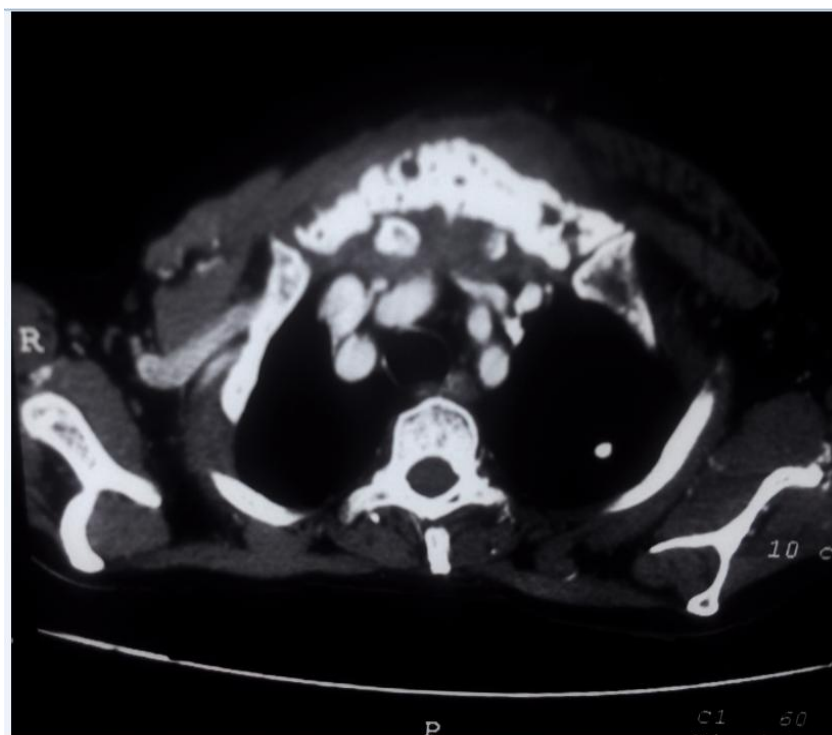
FOOTNOTE

Conflicts of Interest: None

Informed Consent: Written informed consent was obtained from the patient for publication of this case report and any accompanying images.

References

- [1]. Hundal R, Shaffer EA. Gallbladder cancer: epidemiology and outcome. *Clin Epidemiol* 2014;6:99-109.
- [2]. Wagholikar G, Behari A, Krishnani N, et al. Early gallbladder cancer. *J Am Coll Surg* 2002; 194: 137.
- [3]. Nakayama F: Recent progress in the diagnosis and treatment of carcinoma of the gallbladder—introduction. *World J Surg* 1991;15:313-314.
- [4]. Espey DK, Wu XC, Swan J, et al: Annual report to the nation on the status of cancer, 1975-2004, featuring cancer in American Indians and Alaska Natives. *Cancer* 2007; 110:2119-2152.
- [5]. Hamila F, Letaief R, Khnissi M, et al. Port site recurrence after laparoscopic cholecystectomy. *Tunis Med* 2006; 84: 697-700.
- [6]. Z'graggen K, Birrer S, Maurer CA. Incidence of port site recurrence after laparoscopic cholecystectomy for preoperatively unsuspected gallbladder carcinoma. *Surgery* 1998; 124: 831-8.
- [7]. Shirai Y, Ohtani T, Hatakeyama K. Laparoscopic cholecystectomy may disseminate gallbladder carcinoma. *Hepatogastroenterology* 1998; 45: 81-2.
- [8]. Duffy A, Capanu M, Abou-Alfa GK, et al. Gallbladder cancer (GBC): 10-year experience at Memorial Sloan-Kettering Cancer Centre (MSKCC). *J Surg Oncol* 2008; 98: 485-9.
- [9]. Shih SP, Schulick RD, Cameron JL, et al. Gallbladder cancer: the role of laparoscopy and radical resection. *Ann Surg* 2007; 245: 893-901.
- [10]. Kaspaar, Z., Stefan, B., Christoph, A. M., et al. Incidence of port site recurrence after laparoscopic cholecystectomy for preoperatively unsuspected gallbladder carcinoma. *Surgery* 1998; 124:831-838.
- [11]. Yamaguchi, K., Chijiwa, K., Ichimiya, H., et al. Gallbladder carcinoma in the era of laparoscopic cholecystectomy. *Arch.Surg* 1996;131:981-984.
- [12]. Sandor, J., Ihasz, M., Fazekas, T., Unexpected gallbladder cancer and laparoscopic surgery. *Surg. Endosc* 1995; 9: 1207-1210.
- [13]. Suzuki, K., Kimura, T., Ogawa, H. :Is laparoscopic cholecystectomy hazardous for gallbladder cancer ? *Surg* 1998; 123: 311-314.
- [14]. Cavallaro A, Piccolo G, Panebianco V, et al. Incidental gallbladder cancer during laparoscopic cholecystectomy: Managing an unexpected finding. *World J Gastroenterol* 2012; 18: 4019-27.
- [15]. Johnson RC, Fligelstone LJ, Wheeler MH, et al. Laparoscopic cholecystectomy: incidental carcinoma of the gallbladder with abdominal wall and axillary node metastasis. *HPB Surg* 1997; 10: 169-71.



*Himanshu Mishra. "A Rare Case of Carcinoma Gallbladder with Port Site Recurrence And Isolated Sternal Metastasis." *IOSR Journal of Dental and Medical Sciences (IOSR-JDMS)* 16.8 (2017): 25-27