

Spontaneous Rupture of Spleen in P.Vivax: A Rare Case Entity

Dr. Anshul Jain¹, Dr. P.B Gupta²

¹*Resident doctor, Department of Emergency Medicine*

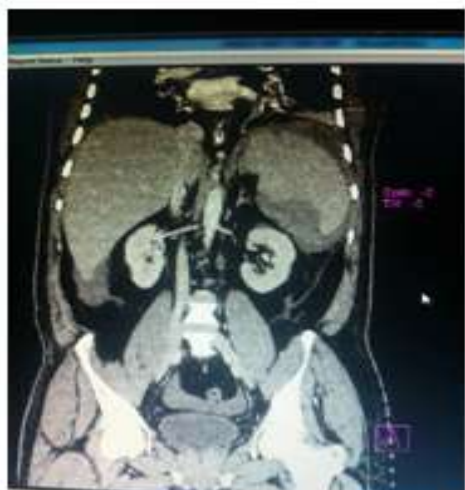²*Professor & Head, Department of Emergency Medicine
Government Medical College, Surat*

I. Introduction

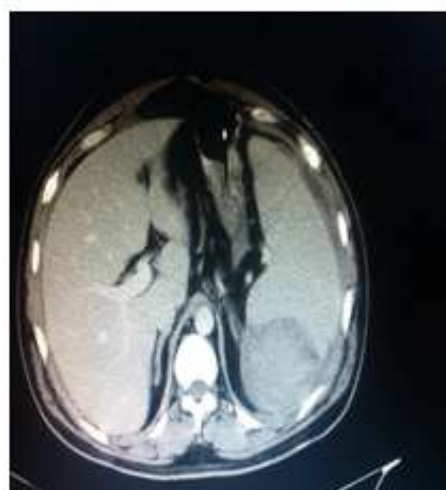
Malaria has been among the most common infectious diseases in India. The causative microorganism belongs to the Plasmodium family. The four common species that are encountered are Plasmodium falciparum, P. vivax, P. malariae and P. ovale. Plasmodium falciparum infection carries more risk of complications such as cerebral malaria, acute renal failure, liver damage, collapse etc. Plasmodium vivax is considered to be benign but splenic complications are more common with P. vivax infections². Spontaneous rupture of malarial spleen is uncommon even in the endemic regions of malaria. This may lead to delayed or missed diagnosis of splenic rupture which may be life threatening³. Very few case reports are available in literature documenting spontaneous rupture of malarial spleen³. We are reporting one such instance of malarial splenic rupture encountered in our department.

II. Case Report

We are reporting a case of a patient with P. vivax malaria who developed a spontaneous splenic rupture in our department. A 40 years old male patient with history of fever with chills since 3 days and abdominal pain since 3 days. There was no history of any associated trauma. On per abdomen examination the only positive finding was of tenderness at the left hypochondrium region. Investigations revealed P. Vivax malaria with Hemoperitoneum on ultrasonography. Patient's CBC report showed HB 5.2 gm%, parasites-rings & schizonts of P. vivax seen, platelet count-90000/cumm. Chest X-ray showing pleural effusion on the left side, so pleural fluid tapping was done, tapped fluid was hemorrhagic. Sonography of abdomen revealed a splenic hematoma and an enlarged spleen and liver with free fluid in abdomen. Pelvic-abdominal CT showed a large peri-splenic hematoma with multiple splenic lacerations. Patient was kept conservatively on fluid therapy as patient was hemodynamically stable and given necessary anti malarials, antibiotics and blood transfusions. Following this treatment repeat USG abdomen was done after 7 days which showed relatively mild amount of haemoperitoneum.



Enhanced CT Scan Of The Abdomen(Longitudinal) Shows Perisplenic Hematoma.



Enhanced CT Scan of the abdomen (transverse) shows perisplenic hematoma

III. Discussion

The causes include infectious, neoplastic, and hematological diseases. Only an estimated 2% of falciparum malaria cases present with spontaneous splenic rupture¹. The first case of spontaneous splenic rupture was reported by Atkinson, an English surgeon in 1874⁵. A peculiar aspect of this complication is that it can occur in patients taking antimalarial prophylaxis and treatment⁶. Although the exact mechanism of splenic rupture in malaria is still not clear, the following mechanisms have been suggested^{7,8} (i) cellular hyperplasia and congestion leading to increase in intrasplenic tension; (ii) splenic compression by increased intra-abdominal pressure during activities like sneezing, coughing and defecation; and (iii) reticuloendothelial hyperplasia resulting in venous congestion, thrombosis, and infarction, which causes sub-capsular hemorrhage and eventual stripping of the splenic capsule. Clinically, left hypochondrial pain occurring during or following treatment of malaria is the commonest presentation of splenic rupture in malaria⁸. Our case presented with left hypochondrial pain without any history of trauma.

IV. Conclusion

Spontaneous splenic rupture in complicated vivax malaria is extremely rare. Splenic rupture with hemoperitoneum should be managed with laparotomy and splenectomy, along with antimalarial drugs. But in this case patient was managed conservatively. A high index of suspicion is needed to detect these complications early.

References

- [1]. Choudhury J, Uttam KG, Mukhopadhyay M: Spontaneous rupture of malarial spleen. *Indian Pediatric*, 2008; 45: 327–28
- [2]. Strickland GT: Malaria. In: Strickland, G.T (Ed.), *Hunter's Tropical Medicine*, seventh ed. Saunders, Philadelphia, PA, 1991; 586–617
- [3]. World Health Organization Action Programme, 1986. Severe and complicated malaria. *Trans R Soc Trop Med Hyg*, 1986; (Suppl): 1–50
- [4]. Wyler DJ: Plasmodium species (malaria). In: Mandell GL, Douglas RG Jr., Bennet JE (eds.), *Principles and Practice of Infectious Diseases*, 3rd ed. Churchill Livingstone, New York, 1990; 2056–66
- [5]. Atkinson E: Death from idiopathic rupture of the spleen. *BMJ*, 1874; 2: 403e–404
- [6]. Vidyashankar C, Basu A, Kulkarni AR, Choudhury RK: Spontaneous rupture of spleen in falciparum malaria. *Indian J Gastroenterol*, 2003; 22: 101e102
- [7]. Patel MI: Spontaneous rupture of a malarial spleen. *Med J Aust*, 1993; 159: 836e837
- [8]. Zingman BS, Viner BL: Splenic complication in malaria: case report and review. *Clin Infect Dis*, 1993; 16: 223e232