

Endoactivator And Diode Laser Assisted Disinfection for Treating C-Shaped Canal in Mandibular Second Molar: Report of 3 Cases.

Gunjan Gautam¹, Surendra K Mishra², Sharique Alam³, Sajid Ali⁴
^{1,2,3,4}(Department of Conservative Dentistry And Endodontics , Aligarh Muslim University, India)

Abstract: C-shaped root canals are most frequently seen in the mandibular second molar. Their complex anatomy makes chemomechanical preparation an arduous and difficult task. The present case series describes the endodontic management of 3 cases of C- shaped canals using sonic irrigation system and laser assisted disinfection.

Keywords: C-shaped, diode laser, endoactivator

I. Introduction

C-shaped root canal is a variant root canal morphology which was first documented by Cooke and Cox in 1979. C-shaped canal is predominately found in mandibular second molar but this canal anatomy has also been reported in maxillary first molars, mandibular first molar, mandibular third molars and mandibular premolar. C-shaped canal has a significant ethnic variation with high prevalence in Asian population (39-44%) while Caucasians have a prevalence rate of only 2.7-9% [1]. Formation of C-shaped canals has been attributed to the failure of Hertwig's epithelial root sheath to fuse either at the buccal or at the lingual root surface [2].

In 1991 Melton et al. first classified the C-shaped canals according to their cross-sectional shape [3]. Later Fan et al. modified it and gave anatomical classification of C-shaped canals [4]. Complete debridement and obturation of C-shaped canals present a problem due to presence of fin or web connecting the individual root canals. Sodium hypochlorite is an ideal irrigating solution but can only dissolve vital and necrotic tissues and eliminate bacteria but is not able to sterilize the canals. Thus there is a need for adjunctive irrigation system and equipment like lasers. Here we present 3 cases of C-shaped canal that were successfully treated using technology like endoactivator and diode laser for irrigation and disinfection of root canal system.

II. Case Reports

2.1 Case 1

30-year-old female with noncontributory medical history reported to Department of Conservative Dentistry and Endodontics with chief complaint of pain in lower left back tooth region since 1 week. On examination tooth #37 was distally carious and non-tender on percussion, tooth gave prolonged response to thermal testing. Intra oral periapical (IOPA) radiograph revealed the presence of single C-shaped canal in relation carious tooth #37 (Fig.1A). Diagnosis of irreversible pulpitis was made. Treatment plan was discussed with the patient and written consent was obtained. Under local anesthesia and rubber dam isolation access opening in tooth #37 was done. Under the dental operating microscope (DOM), Fan et al. Category IV C-shaped canal configuration with single oval root canal was found (Fig. 1B). Working length was determined with apex and confirmed with IOPA x-ray (Fig.1C). Biomechanical preparation was done using Hyflex CM (Coltene-Whaledent, Allstetten, Switzerland) upto 30/.06 in a crown down manner. Circumferential filing with hand K-files (Dentsply/Maillefer; Tulsa, USA) was also done.

Copious irrigation was done with 3% sodium hypochlorite (Septodont, India) and 17% EDTA solution (Smear Clear, Sybronendo, Kerr, Italy) using EndoActivator System (Dentsply Tulsa Dental Specialties, Tulsa, OK) to activate the irrigant. Root canal was dried with the paper points and Diode laser (FONA Diode Laser TM, Sirona Germany) emitting at a wavelength 810nm was used to disinfect the canal. The optical fiber of tip diameter 320µm at 2.5W power is introduced 1mm short of the apex and is recessed in helicoid movements at a speed of approximately 2 mm/s for 5 s, this protocol was repeated 4 times at intervals of 10 s. Calcium hydroxide dressing was given as an intracanal medicament. The patient was recalled after 1 week and root canal was obturated using AH Plus sealer (Dentsply, Germany) and thermoplasticised gutta-percha using Obtura II system (Obtura Spartan, Fenton, Missouri, USA) (Fig. 1D). Post-obturation restoration was done with amalgam.

2.2 Case 2

18-years-old male with noncontributory medical history reported to Department of Conservative Dentistry and Endodontics with chief complaint of spontaneous pain in left lower back tooth region since 2 months. On clinical examination tooth #37 was found carious and slight tender on percussion, patient did not

respond to electric pulp testing. After clinical and radiographical evaluation diagnosis of pulpal necrosis with symptomatic apical periodontitis was made in tooth #37 with C-shaped canal anatomy (Fig. 2A). Under local anesthesia and rubber dam isolation access opening was done using magnification and illumination of DOM. A single root canal was found representing the Fan et al category IV root canal configuration of C-shaped canal (Fig. 2B). Working length was determined radiographically (Fig. 2C). Biomechanical preparation, laser disinfection and obturation were done in a manner described in case 1 (Fig. 2D). Post-obturation restoration was done with amalgam.

2.3 Case 3

32-year-old female with noncontributory medical history reported to Department of Conservative Dentistry and Endodontics with chief complaint of severe pain in right lower back tooth region since 1 month. Clinical examination revealed that tooth #47 had deep occlusal caries, tenderness to percussion with grade 2 mobility. A draining sinus from the distal side of gingival sulcus was present. IOPA x-ray revealed the C-shaped root canal morphology with a periapical radiolucency (Fig. 3A). After clinical and radiographical evaluation diagnosis of primary endo secondary perio lesion with pulpal necrosis and symptomatic apical periodontitis was made. Treatment plan was discussed with the patient and written consent was obtained. Under local anesthesia and rubber dam isolation, access opening was done in tooth #37 using DOM. Pulp chamber floor was found below the CEJ. After a thorough inspection of the pulp chamber Fan et al Category II C-shaped root canal morphology was found. Working length was determined radiographically using #15 K-files (Fig. 3B). Biomechanical preparation was done using Hyflex CM till 25/.06 in a crown down manner. Anti-curvature filing was done and communicating isthmus was prepared till #20 K-file. Copious irrigation was done with 3% sodium hypochlorite and 17% EDTA solution using EndoActivator System to activate the irrigant. Root canal was dried with paper points and disinfected by diode laser as described in case 1. Calcium hydroxide dressing was given and temporary restoration was placed. Rapid improvement was observed (Fig. 3C). After observing the radiographical sign of healing of periapical lesion, root canal was obturated using AH Plus sealer and thermoplasticised gutta-percha (Fig. 3D). Post-obturation restoration was done with amalgam

III. Discussion

It is vital to understand that the laws of Krasner and Rankow for root canal orifice location are not applicable for C-shaped anatomy. In most of the times laws of symmetry 1 and 2 and law of orifice location 2 and 3 are not suitable for location of canal orifices in C-shaped morphology [5]. DOM is an important endodontic aid especially in recognizing and managing complex pulpal anatomy and deviations. In all three cases access opening was done under the magnification and illumination provided by DOM.

In case 3 orifices were found below the level of CEJ. Fan et al. have shown that 83.3% to 98.1% C-shaped mandibular second molars have orifice level 2-3mm below the CEJ. Therefore fundamental knowledge of patterns of pulp chamber anatomy is essential to prevent the perforations [4].

Dentin on the lingual side of C-shaped roots has reported to be relatively thinner as compared to buccal side. Therefore; to avoid strip perforation in C-shaped canals few recommendations have been suggested: use of small sized endodontic files such as #8, #10, #15 K-file for exploration; anticurvature filing technique; apical enlargement not more than size 30(0.06taper); combination of two or more instrumentation systems/techniques; largest permissible file size for preparation of isthmus is #25 [5-8].

Manual instrumentation leaves a large amount of debris and uninstrumented areas fins or isthmus area of a C-shaped canal. These anatomical complexities of teeth prevent the instruments and irrigant solutions from reaching the entire canal surface which might influence the outcome of root canal treatment. Therefore, in all three cases endoactivator irrigation system was used to increase the efficacy of irrigant. Mancini et al. reported that endoactivator also aid in effectively removes the smear layer from root canals [9]. Its design allows for the safe activation of various intracanal reagents and could produce vigorous intracanal fluid agitation.

Additional disinfection by Lasers may be a useful treatment adjunct especially in cases of complex root canal anatomy. In all three cases biochemical root canal disinfection was supplemented with 810nm wavelength diode laser. Diode laser can eliminate microorganisms existing in main canal, lateral canals and dentinal tubules and can increase the success rate of endodontic therapy [10, 11].

All three cases were obturated with thermoplasticized guttapercha filling technique as it is a recommended technique to 3 dimensionally fill the root canal especially in cases of complex configuration of C-shaped canals.

These cases confirm the necessity of careful examination of the floor of the pulp chamber in conjunction with proper radiographic evaluation of the root canal anatomy. Recent irrigation activation system and laser assisted disinfection of root canal may aid in achieving predictable successful outcome in complex root canal configuration of C-shaped morphology.

Figures

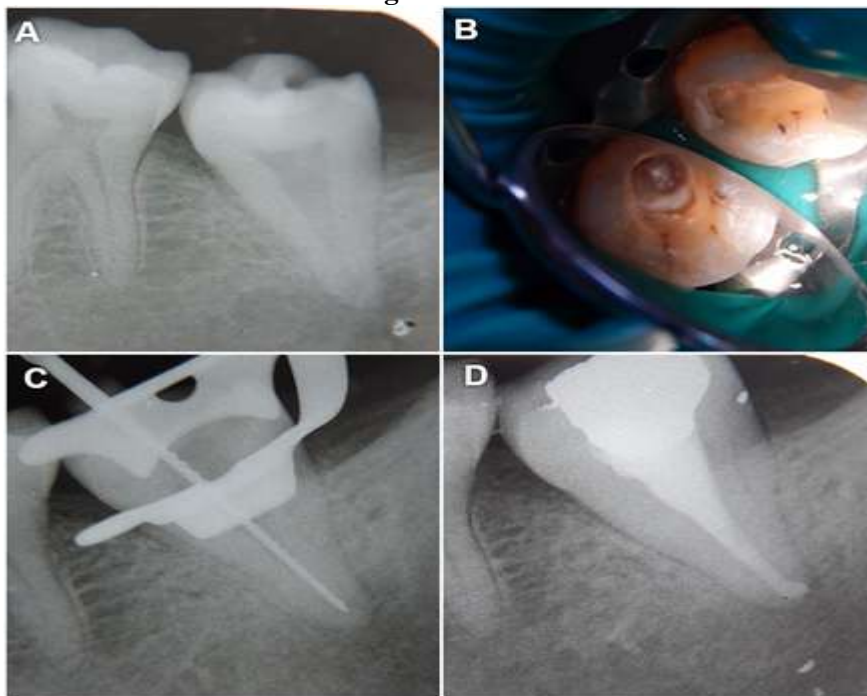


Figure 1 (A) Preoperative radiograph; (B) Clinical photograph; (C) Working length radiograph; (D) Obturation radiograph

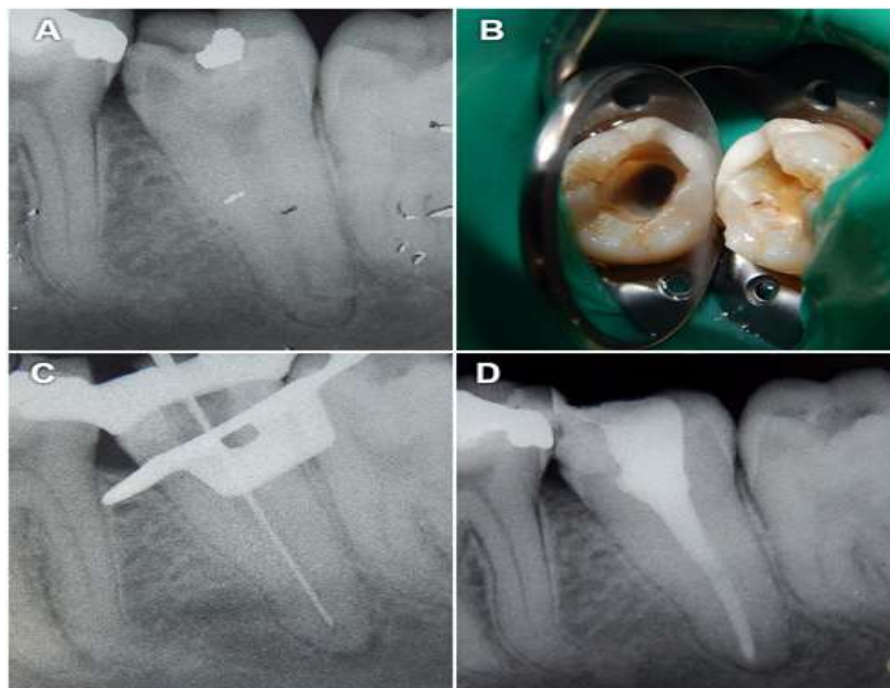


Figure 2 (A) Preoperative radiograph; (B) Clinical photograph; (C) Working length radiograph; (D) Obturation radiograph

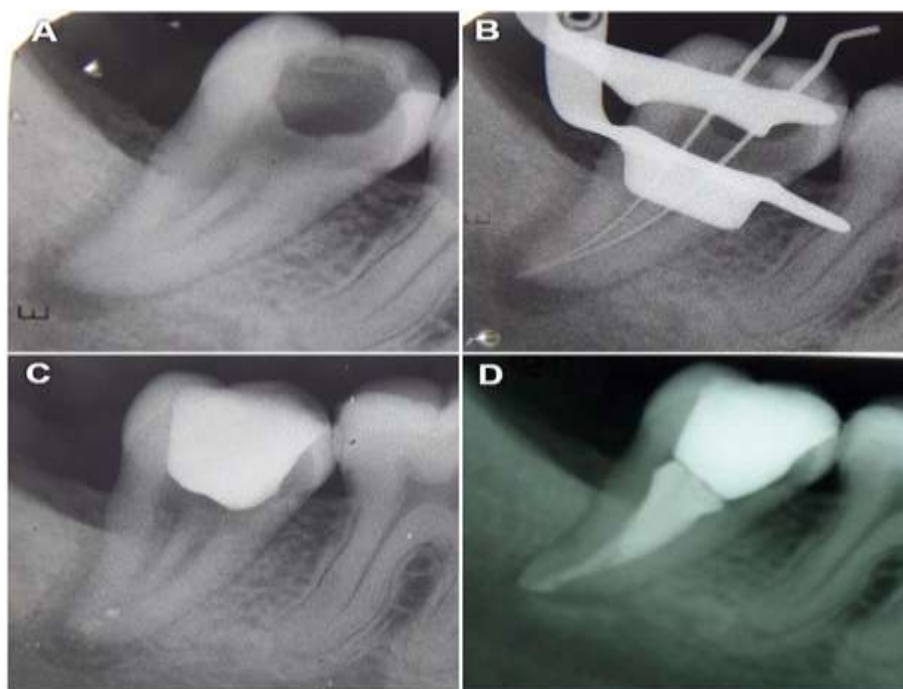


Figure 3 (A) Preoperative radiograph; (B) Working length radiograph; (C) Follow-up radiograph; (D) Obturation radiograph

IV. Conclusion

C-shaped canal system tends to have variable anatomical configuration and thus leads to difficulties in debridement and obturation. The endodontic treatment of these cases may require a careful instrumentation strategy due to the difficulty in disinfecting the canals in the thin root area without compromising the root structure.

References

- [1]. H.G. Cooke and F.L. Cox, C-shaped canal configurations in mandibular molars, *The Journal of The American Dental Association*, 99, 1979, 836– 839.
- [2]. F.J. Vertucci and E.J. Haddix, Tooth morphology and access cavity preparation, in *Cohens (10), Pathways of the Pulp*, (St Louis, Missouri, USA: Mosby-Year Book, 2011) 217.
- [3]. D.C. Melton, K.V. Krell and M.W. Fuller, Anatomical and histological features of C-shaped canals in mandibular second molars, *Journal of Endodontics*, 17, 1991, 384– 388.
- [4]. B. Fan, G.S. Cheung, M. Fan, J.L. Gutmann and Z. Bian, C-shaped canal system in mandibular second molars: Part I—Anatomical features, *Journal of endodontics* 30, 2004, 899-903.
- [5]. Y. Min, B. Fan, G.S. Cheung, J.L. Gutmann and M. Fan, C-shaped canal system in mandibular second molars: part III—the morphology of the pulp chamber floor, *Journal of endodontics*, 32, 2006, 1155– 1159.
- [6]. M.R. Abou, A.L. Frank and D.H. Glick, The anticurvature filing method to prepare the curved root canal, *Journal of the American Dental Association*, 101, 1980, 792– 794.
- [7]. L.H. Cheung and G.S. Cheung, Evaluation of a rotary instrumentation method for C-shaped canals with micro-computered tomography, *Journal of Endodontics*, 34, 2008, 1233– 1238.
- [8]. X. Yin, G.S. Cheung, C. Zhang, Y.M. Masuda, Y. Kimura and K. Matsumoto, Micro-computed tomographic comparison of nickel-titanium rotary versus traditional instruments in C-shaped root canal system, *Journal of Endodontics* 36, 2010, 708-712.
- [9]. M. Mancini, L. Cerroni L, L. Iorio, E. Armellini, G. Conte and L. Cianconi L, Smear Layer Removal and Canal Cleanliness Using Different Irrigation Systems (EndoActivator, EndoVac, and Passive Ultrasonic Irrigation): Field Emission Scanning Electron Microscopic Evaluation in an In Vitro Study, *Journal of Endodontics* 39, 2013, 1456– 1460.
- [10]. A. Kaiwar, H. L. Usha, N. Meena, P. Ashwini and C.S. Murthy, The efficiency of root canal disinfection using a diode laser: In vitro study. *Indian Journal of Dental Research*, 24, 2013, 14-18.
- [11]. M. Asnaashari and N. Safavi. Disinfection of Contaminated Canals by Different Laser Wavelengths, while Performing Root Canal Therapy. *Journal of Lasers in Medical Sciences*, 4(1), 2013, 8-16.