

Morphological Study of Spleen

Kawale Sugat G.¹, Pandit S.V.², Ganorkar Y. S.³, Shaikh S.I.⁴, Meshram M.M.⁵

¹Assistant Professor Anatomy Dept GMC Chandrapur,

²Associate Professor Anatomy Dept GMC Akola

³Assistant Professor Anatomy Dept IGGMC Nagpur

⁴Professor Anatomy Dept SVNGMC Yavatmal

⁵Professor Anatomy Dept GMC Chandrapur.

Abstract:

Background :- The spleen is a haemo-lymph organ and belongs to the reticulo-endothelial system. It consist of a large encapsulated mass of lymphoid and vascular tissue. spleen is highly vascular, friable and elastic, purple in color, moving with respiration. Spleen filter blood by taking out worn-out erythrocytes or may microbial antigens from the circulation, where as lymph nodes filter lymphs.

Materials and methods:- The study included 50 human adult cadaveric spleens. Apparently normal human cadaveric spleens from both sexes were selected. Spleens were removed from abdominal cavity by conventional dissection method. They were washed with tap water to clean debris and fatty tissue. Then they were weighed and their length, breadth, width were measured. Also shape of spleens were observed.

Result :- In present study, we measured length of 50 spleens, the length was in range of <5 cm were 2 (4%), range between 5cm to 7 cm were 8 (16%), range between 7.1 to 9 cm 32 (64%) and length was more than 9 cm were 8 (16%). Their breadth was observed, <4 cm were 4 (82%), range in between 4 cm to 6 cm were 41 (82%) and more than 6 cm were 5 (10%).It was found that width of spleens were, <2 cm was 1 (2%), 2 cm to 4 cm were 40 (80%) and more than 4 cm were 9 (18%). Out of 50 spleens shape were, wedge shaped spleens were 35 (70%), tetrahedral spleens were 9 (18%), oval shaped spleens were 3 (6%), triangular spleens were 2 (4%), and irregular shaped spleen was 1 (2%). Also measured weight of spleens, we noted that, below 80 gms were 7 (14%), range in between 80 gms to 150 gms were 31 (62%), range in between 151 gms to 200 gms 8 (16%) and range in between 201 gms to 300 gms were 4 (8%).

Conclusion :- Knowledge about the morphology of spleen is helpful for the surgeon in doing partial splenectomy. the spleen is an organ which is required for immunological functions and filtration of blood, which is thus preserved by doing partial splenectomy.

Keywords: Spleen, Splenectomy, Lymphatic organ.

I. Introduction

The spleen is a haemo-lymph organ and belongs to the reticulo-endothelial system. It consist of a large encapsulated mass of lymphoid and vascular tissue. spleen is highly vascular, friable and elastic, purple in color, moving with respiration. Spleen filter blood by taking out worn-out erythrocytes or may microbial antigens from the circulation, where as lymph nodes filter lymphs. In foetal life spleen produces erythrocytes and after birth it produces lymphocytes. The spleen is centre where both B and T lymphocytes multiply and play an important role in immune responses. The spleen is situated in upper and left part of abdomen between fundus of stomach and diaphragm, it lies mainly in the left hypochondrium and partly in the epigastrium. The axis of spleen is oblique, and is directed downwards, forwards and laterally coinciding with the left tenth rib. Shape of spleen varies from a slightly curved wedge to a domed tetrahedron. Size of adult spleen is an average 12 cm length, 7 cm breadth and 3 cm thickness. Its average adult weight from 80 to 300 gms. It has two surfaces diaphragmatic and visceral, two borders superior and inferior, two ends medial and lateral, and two angles anterior basal and posterior basal¹.

Spleen is performs important immunological and haematological functions, total splenectomy leads to a decreases in immunity and altered haematological features. To avoid this partial splenectomy can be done . Indications for splenectomy like traumatic rupture, hypersplenism, neoplasia, splenic cyst, etc. the present tendency of surgeon is to try for conservative management and to conserve as much as splenic tissue as possible. Thus, the knowledge of the variational anatomy of the spleen is of fundamental important. So, the aim of this study was to find out morphological structure of spleen².

In mammals, the spleen has three main functions. First, it represent the large mass of organized lymphatic tissue passed by recirculation lymphocytes, which able to promptly elicit specific T or B lymphocytes mediated immune reaction against antigens carried by blood. Due to its open type of circulation, blood borne antigens have a more direct access to the splenic lymphatic tissue than to the tissue of other lymphatic organs. Second, the splenic red pulp has a filtering functions for the blood. The functions comprises the remove of

materials that can be phagocytosed by red pulp macrophages, including aged or abnormal red cells or microorganisms and leucocytes covered with immuno complexes. Third, in some mammalian species, but not in humans, the spleen serves as a reservoir of erythrocytes, which are transfused into the circulation on sympathetic stimulation. In humans, only thrombocytes are normally pooled in the spleen¹.

II. Materials and methods

The present study was conducted in Anatomy department of Government Medical Colleges, Maharashtra. The study included 50 human adult cadaveric spleens. Apparently normal human cadaveric spleens from both sexes were selected. Spleens from both sexes were added together and a statistical analysis was done, without considering the sexual dimorphism.

Spleens were removed from abdominal cavity by conventional dissection method. They were detached from various attachments and the splenic vessels were cut near the hilum after ligation. They were washed with tap water to clean the debris and fatty tissues. Spleens were removed from abdominal cavity carefully. They were washed with tap water to clean debris and fatty tissue. Then they were weighed and their length, breadth, width were measured. Also shape of spleens were observed. The data which obtained, was tabulated, statistically analyzed and compared with that other studies.

III. Result

In present study, we measured length of 50 spleens, the length was in range of <5 cm were 2 (4%), range between 5cm to 7 cm were 8 (16%), range between 7.1 to 9 cm 32 (64%) and length was more than 9 cm were 8 (16%). [Table No. 1/ Fig No. 1]. Their breadth was observed, <4 cm were 4 (8%), range in between 4 cm to 6 cm were 41 (82%) and more than 6 cm were 5 (10%). [Table No. 2]. It was found that width of spleens were, <2 cm was 1 (2%), 2 cm to 4 cm were 40 (80%) and more than 4 cm were 9 (18%). [Table No. 3]. In present study, out of 50 spleens, wedge shaped spleens were 35 (70%) [Table No. 4/ Fig No. 2]. tetrahedral spleens were 9 (18%) [Fig.3], oval shaped spleens were 3 (6%) [Fig no.4], triangular spleens were 2 (4%) [Fig.5], and irregular shaped spleen was 1 (2%) [Fig.6].

We also measured weight of spleens, we noted that, below 80 gms were 7 (14%), range in between 80 gms to 150 gms were 31 (62%), range in between 151 gms to 200 gms 8 (16%) and range in between 201 gms to 300 gms were 4 (8%). [Table No. 5].

IV. Discussion

In the present study, five different shapes of spleen were observed. Amongst those, most common was wedge shape (61.26%) followed by tetrahedral (21.62%) and triangular (12.61%) shapes. This was not in accordance with previous studies, as in studies done in past by Michels² and by Hollinshead³, wedge shape was found in 44%, tetrahedral shape in 42% and triangular shape in remaining 14% specimens. Contrary to previous studies, additional oval (6%) and irregular shapes (2%) were also observed in the present study.

The present study has shown similar observation for size of spleens as in previous studies. Similar to the earlier studies (Bergman et al⁶, Hollinshead³), in our study also, weight varied between 80 to 250 gms in almost all the specimens. As per Gray's Anatomy¹ average adult weight is 150 gms, which varies from 80 to 300 gms. In our study, average weight of spleens was 137.42 gms. Compared to the earlier studies done by Sivanageswara et al⁷, the values for weight of spleen, weight were 80 to 300 gms. In the present study are the values for weight were 80 to 250 gms, slightly lower than his studies.

Chaware et al⁵ found that, out of 111 spleens, 68 (61.26%) were wedge shaped, 24 (21.62%) were tetrahedral, 14 (12.61%) were triangular, 4 (3.60%) were oval and 1 (0.90%) was irregular in shaped. 104 (93.69%) spleen had weights in the range of 80 to 300 gms, with a maximum number i. e. 73 (65.76%) of specimens with weights in the range of 80 to 150 gms. The average weight of the spleens were 145.76 gms. Length of spleen, breadth of spleen and width of spleen were 5 to 13 cms, 3.5 to 9.5 cms, and 1.5 to 3.5 cms respectively. Length of spleen, breadth of spleen and width of spleen were 9.66 cms, 6.22 cms, and 3.06 cms respectively.

The spleen develops from mesoderm. During its development, different lobules are formed, which fuse with each other later on. The indication of lobulation in adult spleen is notched upper border. Sometimes this lobulated appearance may persist in the spleen. That's why, we can get many notches on spleen, which can be seen on superior as well as inferior border of spleen. The number of notches varied from zero to six.

Lizamma Alex et al⁹, found that, out of the 70 spleens, 45 belonged to the males and 25 to females, on plotting the weight changes in a graph. It can be observed that the weight in the males [88.29 ± 36.65] exceeded that in the females [71.60 ± 29.67] in all age groups. The specimens showed a wide range of variations in their shapes i.e., 37 were oval [52.9%], 13 had wedge shape [18.6%], 10 were triangular [14.3%] and nine were tetrahedral [12.9%], as depicted below. A clear dome like appearance was seen in one specimen [1.43%].

Shaik Hussain et al¹⁰ The average length, width and thickness of foetal spleen of gestational age between 12 to 24 weeks were 1.7cm, 1.08 and 0.8cm respectively, gestational age between 25 to 36 weeks were 2.53cm, 1.64 and 1.0cm respectively and gestational age greater than 36 weeks were 2.67cm, 1.67 and 1.0cm respectively . The average foetal weight and spleen weight of gestational age between 12 to 24 weeks were 800gm and 2.84gm respectively and ratio between two was 0.35%, gestational age between 25 to 36 weeks were 1321.42gm and 4.52gm respectively ratio between two was 0.34% and gestational age greater than 36 weeks were 2100gm and 7.07gm respectively ratio between two was 0.33%.

Muktyaz Hussein et al¹¹ found that, out of 32 spleens 19 spleens (59.3%) were found to be normal and variations were observed in 13 spleens (40.6%). In our study 3 spleens (9.3%) found multiple lobes and notches were present on the superior border of spleen, 4 spleens (12.5%), present deep notches on inferior border , 2 spleen (6.2%) showed deep notches on medial border , 2 spleen had shape similar to liver (6.2%) and 1 spleen (3.1%) was pyramidal shaped with presence of notch on inferior border and one of the spleen (3.1%) was small sized 2.7 inches in length.

Satheesha Nayak et al¹² found that, 50 spleens observed, 25 spleens (50%) were normal and had all the features explained in the textbooks. Twenty five spleens (50%) did not have any notches . 2 spleens (4%) did not have a hilum and 4 spleens (8%) were small sized i.e. about 3 inches long . One of the 50 spleens (2%) was liver shaped with 2 lobes. In the spleens without hilum, the splenic vessels entered the spleen by piercing the visceral surface at different places.

In present studies we were found that different shapes, sizes and weight of spleens. This may be due to the different genetic factors, different geographical conditions, feeding habits, socioeconomic status and body constitution.

V. Conclusion

The spleen is an important lymphatic organ in the human body. Its immunological and haematological functions are well realized now a days. The knowledge of morphology of spleen is of fundamental importance for various surgical procedures. Various studies have been conducted on spleen and its segmental vasculature. Knowledge about the morphology of spleen is helpful for the surgeon in doing partial splenectomy where, only affected segment of spleen is removed by ligating the particular segmental branch of splenic artery. Though spleen being a non vital organ, its preservation is done by doing partial splenectomy which is preferred to total splenectomy, as was done earlier as indicate for traumatic splenic rupture, hypersplenism, neoplasia, or splenic cysts. This is because the spleen is an organ which is required for immunological functions and filtration of blood, which is thus preserved by doing partial splenectomy.

Acknowledgements

I would like to thanks Dr. S. S. More Dean GMC Chandrapur, Dr. Prashant Chawre Assistant Professor AIIMS Bhopal, Dr. Gajanan Maske Assistant Professor SVNGMC Yavatmal, Dr. Surekha Meshram Associate Professor GMC Gondia, Dr. Archana Maske Associate Professor SVNGMC Yavatmal , Dr. Jaideo Ughade Associate Professor Raigarh, Dr. Yashwant Kulkarni Associate Professor IGGMC Nagpur , Dr. Shruti Mamidwar Associate Professor GMC Chandrapur , Dr. Prashil jumade Assistant Professor GMC Chandrapur , Dr. Yogesh Gupta Assistant Professor GMC Chandrapur for all help in research.

References

- [1]. Standring S. Harald, healy JC, Johnson D., William A., Gray's Anatomy. [2008],The Anatomical basis of clinical practice. 40th ed., Elsevier Churchill Livingstone, Philadelphia.p:560-564.
- [2]. Cooper M.J. and Williamson R.C.N. [1984] Splenectomy; Indications, Hazards and Alternative Br. Jr. Surg.; vol 71, p 173-180.
- [3]. Hollinshead W.H. [1982]The spleen; Anatomy for surgeons, vol-2, Third edition, p 436-445Medical Department, Harper and Row Publishers.
- [4]. Michels N.A. [1942]The variational anatomy of spleen and splenic artery, American journal of Anatomy; vol 70., p 21-72.
- [5]. Chaware P.N., Belsare S.W., Kulkarni Y.R., Pandit S.V., Ughade J.M.[2012],Morphological Variations Of The Human Spleen. Journal Of Clinical And Diagnostic Research. 2012 April. Vol-6(2), p 159-162.
- [6]. Bergman Ronald A., Adel k. [1996] Spleen - Anatomical variations., Illustrated Encyclopedia of human anatomic variations; opus-4; organ system; digestive system and spleen.
- [7]. Sivanageswara Rao Sundara Setty., Raja Sekhar Katikireddi [2013] Morphometric study of human spleen., International journal of boil medical research;2013;vol 4(3); p 3464-3468.
- [8]. Sant S.[2002] Embryology for medical student, New Delhi., Jaypee brothers medical publicationers (p) ltd, p; 70; 21-72
- [9]. Dr Lizamma Alex, Dr Anju George, Mrs Bency Xavier, Sr Princy Jacob, Mrs Kumari Deepa Rani, Dr Gaddam Vijaya Lakshmi; Morphological Variations of Human Spleen in Different Age Groups, international journal of healthcare,Vol. 3, Issue 1, pp: (122-129).
- [10]. Shaik Hussain Saheb , Subhadra Devi Velichety , Haseena S [2014],morphological and morphometric study of human foetal spleen, International Journal of Anatomy and Research, Int J Anat Res 2014, Vol 2(1):234-38.

- [11]. Dr. Muktyaz Hussein, Dr. Khalid Hassan, Dr. Birendra Yadav, Dr. Nema Usman[2013], anatomical variations of spleen in north indian population and its clinical significance Innovative Journal of Medical and Health Science 3 : 4 July – August. (2013) 190 - 192.
- [12]. Satheesha Nayak B.,S. N. Somayaji, Soumya K[2011].: V.A Study on the Variations of Size, Shape and External Features of the Spleen in South Indian Population; Estudio sobre la variación del tamaño, forma y características externas del bazo en la población del Sur de la India. Int. J. Morphol., 29(3):675-677.

Table No. 1 – Length of Spleen

Length of Spleen	Percentage
<5cm	4%
5cm to 7cm	16%
7.1cm to 9cm	64%
>9cm	16%
Total	100%

Mean =7.96cm, Maximum =10.2cm, Minimum =4.68cm , SD =1.364 , Mode =8.2cm

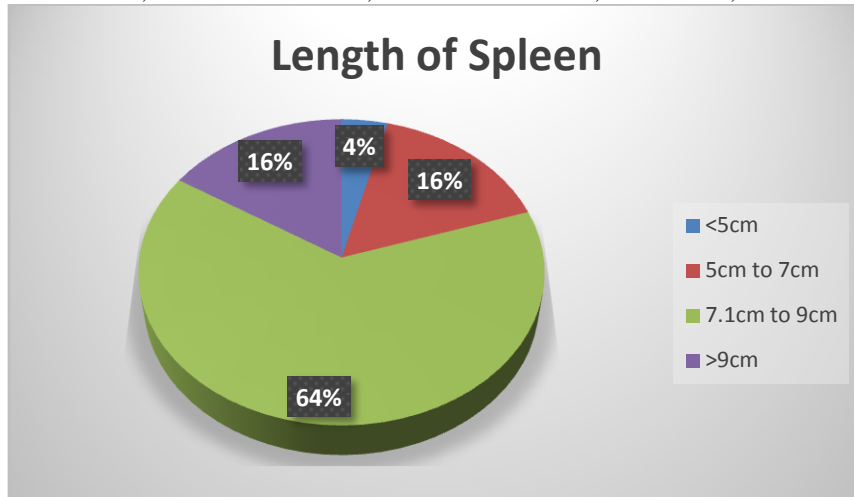


Table No. 2 – Breadth of Spleen

Breadth of Spleen	Percentage
<4cm	8%
4cm to 6cm	82%
>6cm	10%
Total	100%

Mean =4.6cm , Maximum =6.6cm ,Minimum =2.9cm , SD =0.7604 , Mode =4.1

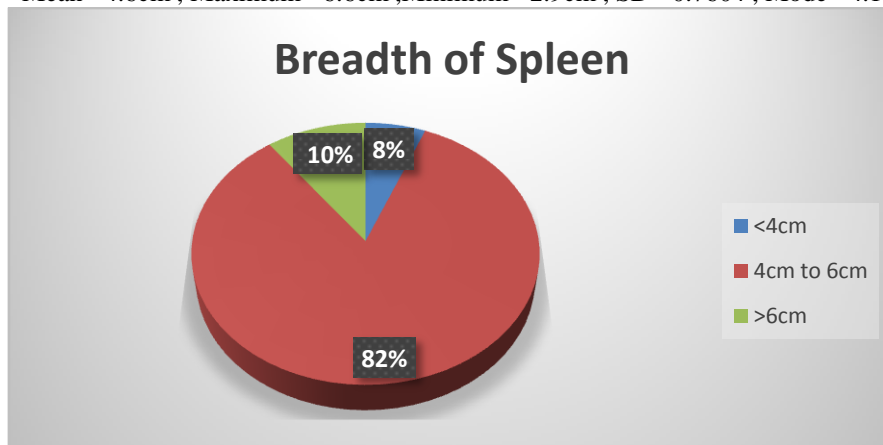


Table No. 3 – Width of Spleen

Width of Spleen	Percentage
<2cm	2%
2cm to 4cm	80%
>4cm	18%
Total	100%

Mean =3.26cm , Maximum =5cm ,Minimum =1.2cm , SD =0.8914 , Mode =2.6cm

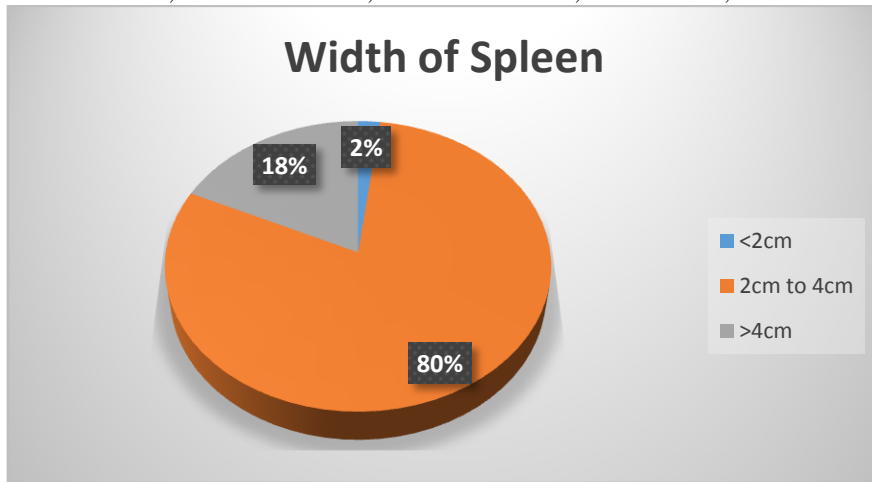


Table No. 4 – Shape of Spleen

Shape of Spleen	Percentage
Wedge	70%
Tetrahedral	18%
Oval	6%
Triangular	4%
Irregular	2%
Total	100%


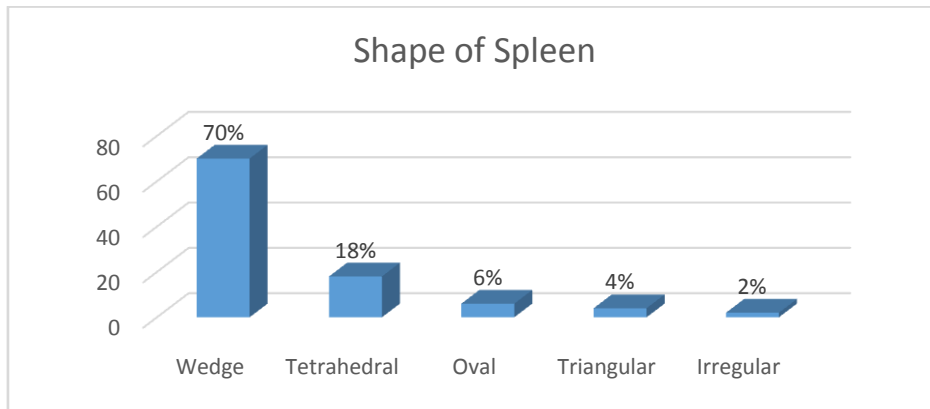


Fig.1



Fig-2

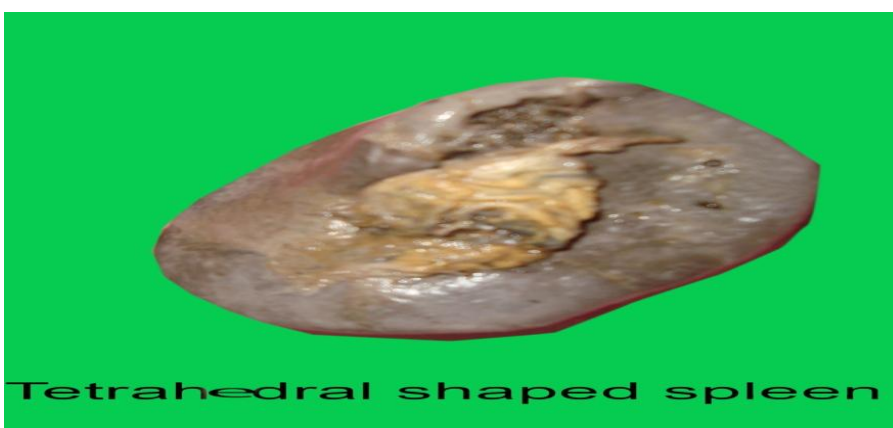

Fig.3



Fig.4



Fig.5

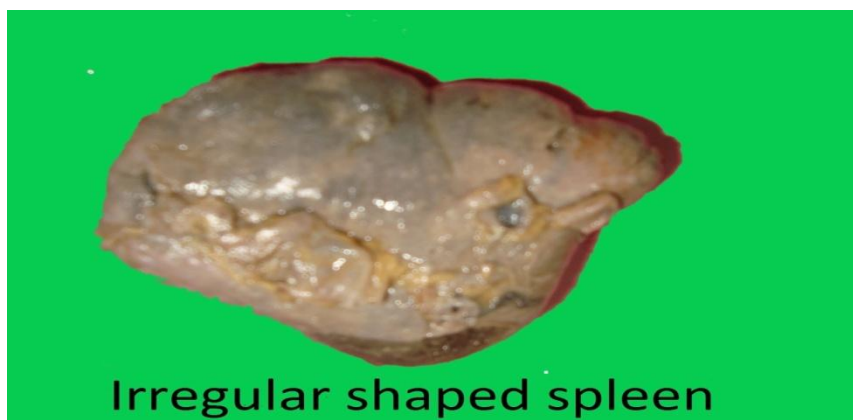

Fig.6

Table No. 5 – Weight of Spleen

Weight of Spleen	percentage
below 80gm	14%
80gm to 150gm	62%
151gm to 200gm	16%
201gm to 300gm	8%
Total	100%

Mean =137.42gm , Maximum =250gm ,Minimum =70gm , SD =40.574 , Mode =146gm

