

Relative Position of Umbilicus in Developing Foetuses.

Nirmalya Saha¹, Chirom Pritam Kumar Singh², Moirangthem Matum Singh³.

¹Department Of Anatomy, Tripura Medical College & Dr. B. R. A. M. Teaching Hospital, Hapania, Tripura.

²Department Of Obstetrics & Gynaecology

³Department Of Anatomy; Regional Institute Of Medical Sciences, Imphal, Manipur.

Abstract: The umbilicus is a round dermal projection of the centre of the anterior abdominal wall. The position of the umbilicus is a significant factor in surgical procedures like abdominoplasty. So the study is aimed to determine the relative position of umbilicus in developing foetuses. During routine dissection of the foetuses of different gestational ages, in the Department of Anatomy, the position of the umbilicus was measured in 34 numbers of foetuses. The foetuses were included into 3 gestational age groups. The distance from inferior border of xiphisternum to the upper border of pubic symphysis [xiphi-pubic (XP)], and the distance of xiphisternum to the midpoint of umbilicus [xiphi-umbilical (XU)] were measured in the midline in supine position. The percentage ratio between XU and XP were calculated and the data were analysed. XP was 8.47+/-2.42 cm and XU was 5.49+/-1.92 cm. The umbilical position was 64.19+/-9.75 percent off the away from the inferior border of xiphisternum to the superior border of pubis in the midline. XU/XP percentage ratio was not significantly different in all the age groups. This study will contribute in selecting the most appropriate site for abdominal reconstruction surgery during foetal period.

Keywords: Abdominoplasty, Pubic Symphysis, Umbilicus, Xiphisternum.

I. Introduction

The umbilicus is a round dermal projection of the centre of the anterior abdominal wall.¹ It lies over the umbilical ring, which is the last part of the abdomen closed in foetus or after birth.² The normal umbilical position is 60% of the way from the inferior border of the xiphisternum, to the superior border of the pubis in the midline.³

The malformations related to ventral body wall defects in thorax, abdomen and pelvis are due to failure of the non-fusion of lateral body wall folds or physiological umbilical herniation. The most common defects are found with fetal omphalocele (2.5/10,000 births) and Gastrochisis (1/10,000 births) with increasing frequency due to various factors related to congenital anomalies.⁴ The overall survival rate for neonates born with an abdominal wall defect is reported to be 70-96%.⁵ Advances in medical imaging have led to an improvement in early prenatal diagnosis of congenital anomalies⁶ which can be corrected by postnatal therapies. The post natal therapy is not the answer to all foetuses, leading to the emergence of foetal surgery over the last 30 years and reduces the untreated causes of stillbirths and reverses foetal damage that is not amenable to postnatal correction.⁷

Although the umbilicus is not essential for life, its presence and position has the greatest importance in abdominal cosmetic appearance.⁸ So, the position of the umbilicus is a significant factor in surgical procedures. Because of advances in ultrasound and surgical procedures, successful operations in centres with well trained teams are possible with early prenatal diagnosis. Repairs of hernias due to ventral body wall defects have good outcomes and without surgery foetal demise is almost certain with large defects.⁴ So, it is necessary to know the position of the umbilicus in developing foetuses for intrauterine closure of abdominal defects and to create neoumbilicus. Hence, the study was aimed to determine the relative position of umbilicus in developing fetuses.

II. Materials & Method

The foetuses of different gestational ages were collected from the Department of Obstetrics & Gynaecology in RIMS Hospital for routine dissection of the foetuses, in the Department of Anatomy, RIMS, Imphal. Due permission from concerned authorities and persons and formal Institutional Ethics Committee Clearance were taken to conduct the study. Immediately after

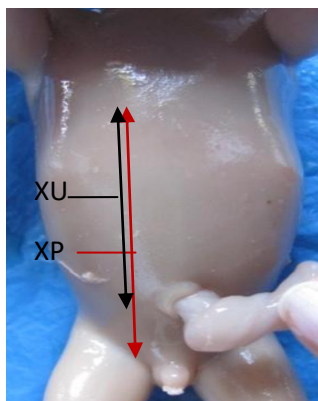


Fig: 1- Showing measurement of Xiphi-umbilicus (XU) and Xiphi-pubic (XP). collection, gestational age (GA) was determined by

Crown-Rump length (CRL) and maternal history. The position of the umbilicus was measured in 34 numbers of foetuses. The foetuses were included into 3 gestational age groups: Group I – 15 to 22 weeks, Group II – 22 to 30 weeks and Group III – 31 to 40 weeks. The distance from inferior border of xiphisternum to the upper border of pubic symphysis [xiphi-pubic (XP)] and the distance of xiphisternum to the midpoint of umbilicus [xiphi-umbilical (XU)] were measured in the midline in supine position. The percentage ratio between XU and XP were calculated and the data were analysed in one group and among the groups.

III. Result

The 34 foetuses were distributed into three groups according to their gestational ages (in weeks) and were distributed as follows:

Table 1: Showing age group wise distribution

Group	Weeks	Numbers	Percentage (%)
I	15-22	7	20.6
II	22-30	16	47.1
III	31-40	11	32.4
Total (n)		34	100.00

Table 2: Showing age group wise mean distance (in centimetre) ± standard deviation (SD)

Group in (Weeks)	Xiphi-Umbilicus (XU) in cm	Xiphi-Pubic (XP) in cm	XU/XP (%)
I (15-22)	3.90±1.04	5.87±1.35	66.32±7.02
II (22-30)	5.41±1.91	8.16±1.80	64.52±1.14
III (31-40)	6.64±1.69	10.59±1.90	62.36±8.97
Total (n=34)	5.49±1.92	8.48±2.42	64.19±9.75

(Cm = Centimetre)

Table 3: Showing ANOVA Test

Ratio	df	F	Significant Value
Between the groups	2	0.354	0.705
Within the groups	31		

The ratios of xiphi-umbilical and xiphi-pubic all the foetuses was found to be 64.19±9.75% irrespective of age groups. The ratios in all the groups were found to be more than 60% from the lower border of xiphisternum to the upper border of pubis. The ANOVA test in between two groups and among the groups suggested that there is no significant differences in the xiphi-umbilical and xiphi-pubic ratio.

IV. Discussion

Abdominal wall defects require complete reduction of herniated viscera as soon as technically feasible after birth.⁹ Creation of a cosmetically appearing umbilicus in patients who can undergo primary closure of an omphalocele remains a challenging problem.¹⁰ as the defect might extend from a few centimetres below the xiphisternum to a few centimeters above the pubis causing it difficult to select the most appropriate normal position of neoumbilicus during surgery.⁹ The normal neonatal umbilicus was positioned two thirds of the distance from the xiphoid to the pubis (mean XU:XP = 0.67±0.07).¹¹

The scar in abdominoplasty and umbilical hernia repair might be associated with poor self images in later life¹ which can be reconstructed as a normal-looking, well shaped and sufficiently deep umbilicus in neonates.^{9, 12} The failure to return of intestinal loops into the abdominal cavity after physiological herniation during 6th to 10th weeks may cause the ventral body wall defects which can be reparable during intrauterine life by foetal surgical procedures with a good outcome.⁴

The umbilicus was located below the abdominal midpoint, between the xiphoid process and symphysis pubis and over the disc between the third and fourth vertebrae, approximately 2 to 4 cm above the line joining the crest of iliac crest. Its position varied considerably with the type of individual habitus.¹³

In the present study, the position of the umbilicus during foetal life was $64.19 \pm 9.75\%$ of the way from the lower border of the xiphisternum to the upper border of the pubis. In Group – I (15-22 weeks of GA) the ratio was found $66.32 \pm 7.02\%$ which can be comparable with the neonatal umbilical position.¹¹ The position of umbilicus in newborns was 59.3 ± 5.5 (54.1- 64.5) percent of the way from the lower border of the xiphisternum to the upper border of pubis and was independent of the measured variables (boys and girls).² All the divided three foetal age groups of the present study, the position of the umbilicus (mean XU: XP) was found to be more than two thirds from the lower border of xiphi-sternum to the upper border of pubis. Similar result was found in a neonatal study where the normal position of the umbilicus were about 60% of the way from xiphisternum to pubis.³

V. Conclusion

There were very few reports of neonatal studies on normal umbilical position³ and literature suggest rarely the relative position of umbilicus during intrauterine life. We hope that, our study will contribute in selecting the most appropriate site for abdominal reconstruction surgery irrespective of all the gestational age of foetuses while undergoing foetal surgery for ventral body wall defects.

References

- [1]. Park S, Hata Y, Ito O, Tokioka K, Kagawa K. Umbilical reconstruction after repair of omphalocele and gastrochisis. *Plast Reconstr Surg* 1999;104(1):204-7.
- [2]. H Davari, M Nazem. The normal position of umbilicus in the newborn: an aid to improve cosmetic result in exomphalos major. *Journal of Research in Medical Sciences* 2004;1:34-8.
- [3]. Williams AM, Brain JL. The normal position of the umbilicus in the newborn: an aid to improving the cosmetic result in omphalocele major. *J Pediatric Surg* 2001;36:1045-6.
- [4]. Sadler TW. *Langman's medical embryology*. 11th ed. New Delhi: Wolters Kluwer / Lippincott Williams & Wilkins; 2010.
- [5]. Kirk EP, Wah RM. Obstetrics management of the fetus with omphalocele or gastrochisis: a review and report of one hundred twelve cases. *Am J Obstet Gynecol* 1983;146:512-8.
- [6]. Frates MC, Kumar AJ, Benson CB. Fetal anomalies: a comparison of MR imaging and US for diagnosis. *Radiology* 2004;232:398-404.
- [7]. Lambretti S, Lambretti S. Fetal surgery. *Radiol technol* 2009;81(2):194-8.
- [8]. Ravitch MM. The chest wall. In: Welch KJ, Randolph JG, Ravitch MM, O, Neill Jr. JA, Rowe MI, editors. *Pediatric Surgery*. 3rd ed. Year Book Medical Publishers, Inc., Chicago 1986; pp.563-89.
- [9]. Lee SL, Du Bois JJ, Greenholz SK, Huffman SG. Advancement flap umbilicoplasty after abdominal wall closure: prospective results compared with normal umbilical anatomy. *J Pediatric Surg* 2001;36:1168-70.
- [10]. Ricketts RR, Luck SR. Simultaneous umbilicoplasty and closure of small omphaloceles. *Surg. Gynaecol. Obstet.* 1983;157:572-3.
- [11]. El-Afifi MA. Simultaneous advancement flap umbilicoplasty and omphalocele repair. *EJS* 2003;22(4):403-6.
- [12]. Friogo E, Rettinger-Schimmerl S, Rokitansky AM. Umbilicoplasty in neonates with primary omphalocele closure. *Pediatr Surg Int* 1999;15(7):523-4.
- [13]. Gaines BA, Holcomb GW, Neblett WW. Gastrochisis and omphalocele. In: Ashcraft KW, editor. *Pediatric Surgery*, 3rd ed. W. B. Saunders 2000;pp.639-49.