

Assessment of Accuracy of Sentinel Node Biopsy in Deciding Axillary Node Dissection After Neo-Adjuvant Chemotherapy in Carcinoma Breast Using Methylene Blue Injection Technique.

Prof. N.Tamilselvan¹ M.S., Dr.M.Arulkumaran² M.S., M.R.C.S. Ed.,D.A.,
¹(Associate Professor, Department of General Surgery, Government Mohan Kumaramangalam Medical College, Salem, Tamilnadu, India.)

²(Assistant Professor, Department of General Surgery, Government Mohan Kumaramangalam Medical College, Salem, Tamilnadu, India.)

Abstract:

Background: Axillary lymph node status is a vital prognostic indicator in the prognosis of the patients with carcinoma breast. The role of Sentinel lymph node biopsy in deciding the axillary node dissection in clinically node negative axilla is obvious. However there exists a debate regarding the role of sentinel lymph node biopsy after Neoadjuvant chemotherapy. This study assesses the efficacy & accuracy of SLNB by using peritumoral injection of a dye after NAC in carcinoma breast.

Methods: Thirty biopsy proven cases of LABC (Stage IIB, IIIA & IIIB) that had received three cycles of neo-adjuvant chemotherapy (FAC regime) were subjected to SLNB followed by complete axillary node dissection (levels I-II) The sentinel node(s) was/were and other axillary nodes were individually assessed histologically. The SLN accuracy parameters calculated using standard definitions. The SLN identification rate in the present study was 93%. The sensitivity of SLNB was 85.7%. None of the patients in our study developed any complications.

Summary: This study confirms methylene blue as a mapping agent in detecting SLNB after Neoadjuvant chemotherapy in locally advanced breast cancers. SLNB may be used as therapeutic option in LABC patients after NAC for avoiding unnecessary axillary lymph node dissection and its complications.

Keywords: Locally advanced breast cancer, Neo-adjuvant chemotherapy, Sentinel lymph node biopsy, Methylene blue dye

I. Introduction

Long term survival and quality of life after MRM for Breast malignancies depends on the axillary lymph node status, size of the Primary tumor, and the Histopathological grading^[1,2]. Among these, the Lymph node status of the axilla plays a vital role in staging the cancer and the selection of treatment in individual patients^[1,2].

Complete lymph node dissection of the axilla (ALND) is associated with a number of morbidities including Paresthesias (which are self-limiting) and pain in the operated limb (chronic painful syndrome), weakness, edema of the limbs, and frozen shoulder which causes hindrance to the day to day activities^[1,2]. The risk of developing lymphedema ranges from 8% to 37% and mainly depends on the extent of the axillary clearance. Undue handling of the axilla may produce major vessel thrombosis (esp. Axillary Vein). Though it is extremely rare, the chance of damage to the Brachial plexus exists. In clinically node-negative patients, sentinel lymph node mapping (SLNB), can give an idea about the axillary nodal status with a rate of identification (IR) >90% and a false negative rate (FNR) <10%^[1,2]. For early breast cancers, SLNB has replaced ALND. In a patient with negative SLNB the possibility of the other nodes in the axilla being negative is about 90-95%^[1]. In the current scenario, Preoperative chemotherapy (NAC) plays a vital role in the treatment of locally advanced breast cancers^[1,2] which achieves 40% node negativity (Complete Pathological Response).

Various factors have significant influence over the efficacy and accuracy of Sentinel node mapping after NAC,^(13, 15). Hence It is important to know whether sentinel lymph node biopsy after NAC is useful in deciding whether to proceed with ALND or not so as to avoid unnecessary morbidity associated with ALND.

II. Source of Data

All patients who are FNAC proven cases of LABC (Stage IIB, IIIA & IIIB) attending the General Surgical OPD of all Surgical units of Government Mohan Kumaramangalam Medical College, Salem evaluated clinically and by investigations over a period of one year (April 2015 to march 2016) after obtaining the clearance from the ethical committee of Government Mohan Kumaramangalam Medical College, Salem.

II.1. Patients:

Thirty FNAC confirmed cases of LABC who met with the Inclusion and Exclusion criteria were evaluated and informed consent was obtained before enrolling in the study. All the patients were informed about the nature of the disease. FNAC of the nodal metastases was not done in this study.

II.2. Inclusion Criteria:

- Patients aged between 30 to 70 yrs.
- Include Females only.
- All patients with breast lumps and FNAC positive reports.
- Patients who belong to clinical Stage II B (Tumor >2cm with nodal involvement), III A & III B disease

II.3. Exclusion Criteria:

- Pregnant women
- Patients with benign breast diseases
- Excludes all inoperable advanced breast malignancies
- Patients with inflammatory breast carcinomas
- Recurrent breast lump in a previously operated case of carcinoma breast
- Patient with the History of coronary artery heart disease

II.4. Methodology:

Detailed history elicited from the patient and clinical examination findings were recorded. Then patients were subjected for blood and radiological investigations. Echocardiogram was done for all patients before initiating the neo-adjuvant chemotherapy. Neo-adjuvant Chemotherapy (NAC) was administered as per standard regimen FAC (5 – FU – 500mg/m²; ADRIAMYCIN – 50 mg/m²; CYCLOPHOSPHAMIDE – 500 mg/m²). Three cycles of NAC were given to the patients at an interval of 3 weeks (21 days).

Three weeks after the last cycle of NAC was completed patients were taken up for surgical procedure, i.e. MRM. Intraoperatively 10 ml Methylene blue will be injected in the peritumoural tissue after the induction of anaesthesia. Breast massaging was done for 5 minutes. The sentinel node mapping was done after raising the upper flap. (Average time taken for dissection of SLN dissection was 15-30 minutes). The nodes with blue staining were considered as Sentinel nodes and the other nodes that did not take up the dye were considered as non-sentinel nodes. Both the sentinel nodes and non-sentinel nodes were sent in a separate container for histopathological study while the surgical procedure was being completed.

II.5. Statistical Analysis:

Data analysis was done using **Prism graph pad version 5** Statistical software 30 patients were studied using the descriptive statistics; values related to SLNB technique in terms of sensitivity; specificity; false negative-rate and accuracy (Fisher's exact test) were recorded. P value is < 0.001 with confidence limit of 2.43 to 33.25 with 'f' value of 0.889.

III. Results

A total of 30 subjects were enrolled in the study and have completed the study as per protocol. The baseline characteristics of the patients in this study are summarized in table no 1. The mean age of the patients involved in the study was 52.1 years (with standard deviation of 12.5 years and median of 50.5 years). No male patients were included in this study.

Table 1: Baseline characteristics of the patients:

S.No	Parameters	Observed value(s)
1	Age (in years)	52.1 ± 12.5
2	Pre-menopausal women	
	N	9
	Percentage	30
3	Post-menopausal women	
	N	21
	Percentage	70
4	Sidedness of Breast cancer	
	Left sided (%)	50
	Right sided (%)	50

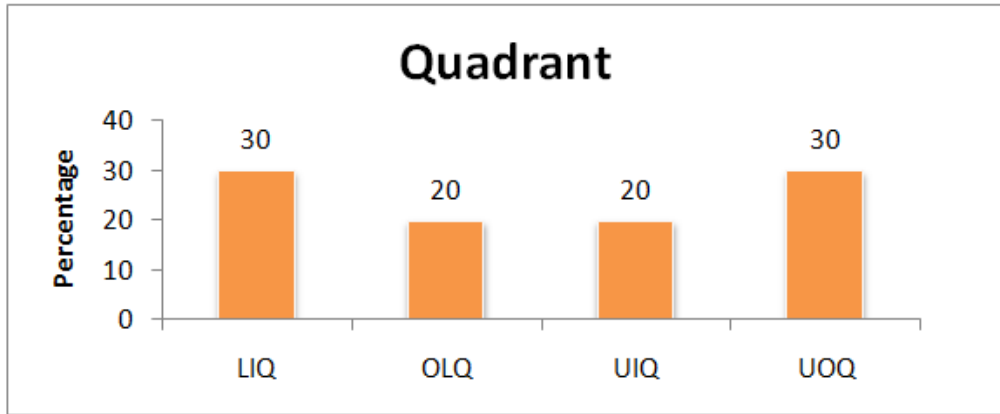


Fig 1: Baseline Characteristics – Quadrant Distribution

Out of 30 patients, 70 % of the subjects were premenopausal women (n = 21) and 30 % were postmenopausal women (n = 9).

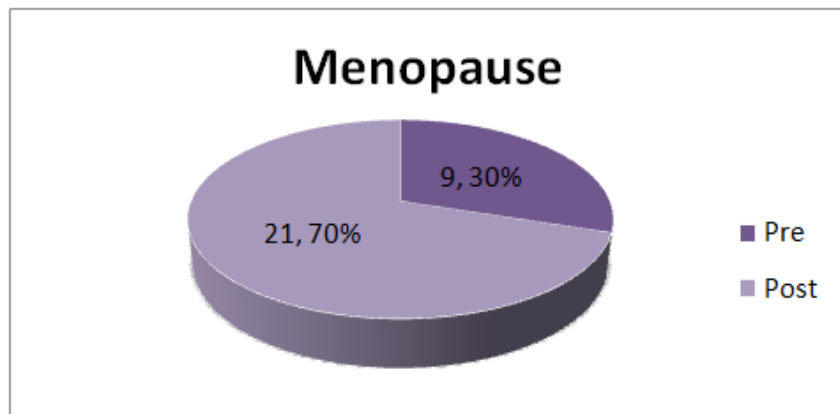


Fig 2: Baseline Characteristics – Menopausal Status

In this study, out of 30 patients, 6.7 % were in T2N1M0, 13.3% were in T2N2M0, 53.3% were in T3N1M0, 20% were in T3N2M0 and 6.7% were in T4N1M0. The proportion of the stage T3N1M0 was the highest in the subjects before NAC and was shown in the figure 3.

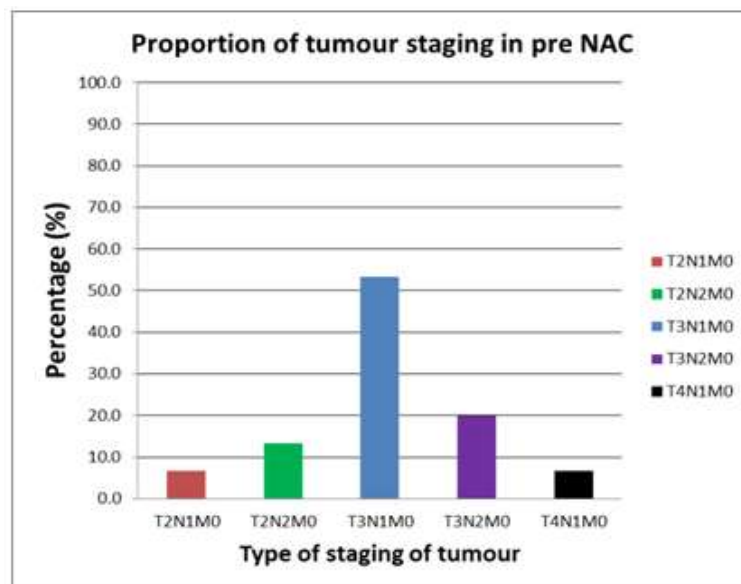


Fig 3: Bar diagram showing the proportion of staging in the patients of the study before neo-adjuvant chemotherapy

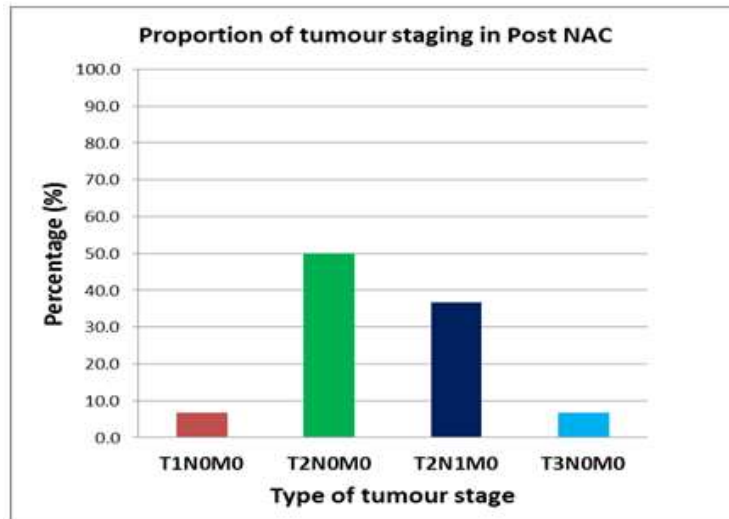


Fig 4: Bar diagram showing the proportion of staging in the patients of the study after neo-adjuvant chemotherapy.

After neo –adjuvant chemotherapy, out of 30 patients, 6.7 % were in T1N0M0, 50% were in T2N0M0, 36.7% were in T2N1M0, and 6.7% were in T3N0M0. The proportion of the stage T2N0M0 was the highest in the subjects after NAC and was shown in the figure. The sentinel lymph node identification was done successfully in 93.3% of the patient (28 out of 30) and in the remaining 6.7 % (2 out of 30) sentinel lymph node identification could not be done. The number of sentinel lymph node removed per patient ranges from minimum 1 node to the maximum of 3 nodes.

The average number of sentinel node harvesting was 1.43 per patient. And the average number of non sentinel node was 7.8 per patients. The number of axillary lymph node removed, ranges from a minimum of 5 nodes to the maximum of 14 nodes. Out of 28 cases in which the sentinel node was identified, malignancy was positive for 12 cases (42.8%) and negative for the 16 cases (57.2%). Similarly in the axillary lymph nodes, out of 30 patients, malignancy was positive for 16 cases (53.3%) and negative for 14 cases (46.7%).

The results were tabulated and analysed with Fisher’s exact test and is shown in the Table 2

Parameters	ALN with metastasis	ALN without metastasis	Total
SLN with metastasis	12 (40%)	0 (0%)	12 (40%)
SLN without metastasis	2 (7%)	16 (53%)	18 (60%)
Total	14 (47%)	16 (53%)	30 (100%)

Foot note: Data are expressed as n (%). SLN = sentinel lymph node; ALN = axillary lymph node. Fisher’s exact test was done to determine the statistical significance and was found to be statistically significant ($p < 0.001$) with confidence interval of 2.43 to 33.25 and ‘f’ value of 0.889

Table 3: Results of SLN & ALN malignancy status.

No. of true-positive findings	12
No. of true-negative findings	16
No. of false-positive findings	0
No. of false-negative findings	2
Sensitivity (%)	85.71
Accuracy (%)	93.33
Negative predictive value (%)	88.89
False negative rate (%)	14.3

Thus in our study, sentinel node dissection was attempted in 30 patients, out of which sentinel nodes were successfully identified in 28 patients, with a sentinel node identification rate of 93%. We achieved a sensitivity of 85.7% (12/14), specificity of > 99.9%, true positive rate of 39.4%, false negative rate of 14.3% (2/18), a negative predictive value of 88.8% (16/18), and an overall accuracy of 40% (12/30). None of the patients in our study developed any complications.

IV. Discussion

IV.1. Methylene blue as a Mapping agent:

Because of its low cost and reduced risks of producing adverse effects, methylene blue has been used widely for lymphatic mapping [4,5]. In a cohort study, Simmons et al [4,5] studied on 100 patients and demonstrated sentinel nodes in 93 subjects using methylene blue; and their results are equally efficacious as radio isotopes. Blessing et al [4,5] (2002) found that both isosulfan and methylene blue had similar identification rates.

Methylene blue when given intradermally produces severe skin reactions like Dermolysis and skin necrosis; hence it is usually given subcutaneously or in the peritumoral tissue (we used peritumoral injection technique). Even after the addition of radio colloid to methylene blue there was no demonstrable increase in identification rate; hence methylene blue has become the single most important dye used for SLNB lymphatic mapping especially in developing countries [4,5].

The main side effect is a bluish discoloration over the site of injection [4,5]. Urine and stools may have a bluish discoloration. It doesn't cause any life threatening complications like acute renal shutdown or change in enteric circulation.

IV.2. Factors associated with Non identification of Sentinel Nodes [3,4,5].

- 1) SLN Identification rate (%)
It is the number of patients showing positive SLN divided by the total number of patients in whom SLN mapping is attempted.
- 2) SLN False Negativity (FNR) rate (%)
It is the number of patients showing false negativity divided by the total number of cases showing true positives and false negatives.
- 3) Short/ Reduced Learning curve of the Surgeons
- 4) Tumor location (Medial location)
- 5) Older age
- 6) Patients with previous excisional or transverse biopsy scars.
- 7) Single Vs. Dual mapping agent



Fig 5: Discoloration of urine

IV.3. Peri-Tumoral Injection [3,4,5]:

During the initial periods investigators tried injecting mapping agents peritumorally for isolation of the lymphatic pathways traversed by the tumoral cells. In case of non palpable malignancies, this method has some difficulty in locating the tumour and requires sophisticated imaging assistance.

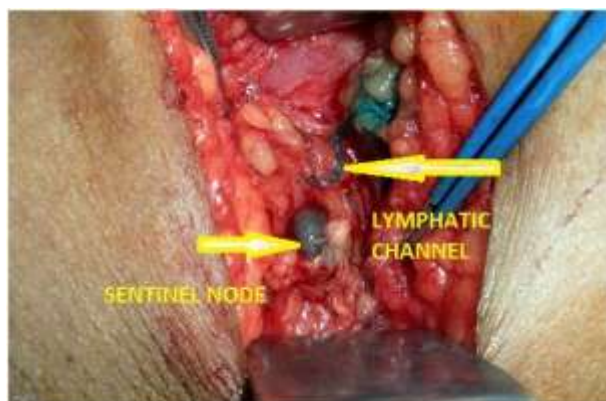


Fig 6: Sentinel Node – Blue Node.

IV.4. Prognostic Significance

The important prognostic factor determining the survival advantage in carcinoma breast is the histopathological status of the axillary node. Following NAC, we got an advantage of assessing the in vivo chemosensitivity. It is an attractive strategy in which the axilla is downstaged to N0. Node downstaging occurs in nearly 47% i.e (malignancy negative for 14 patients out of 30).

Several factors can affect the accuracy of the SLNB [2,5,6,7].

1. Lymphatic pathway may get fibrosed due to the effect of chemotherapy.
2. Cellular debris and tumor emboli may block the channels.
3. Senescence of tumor cells may produce fatty degeneration.
4. Metastatic cells producing disorganized responses to the chemotherapeutic agents.

But the above said possibilities are of theoretical values.

Kuerer et al [1,2,8,9] studied on patients who have NAC, They established a 87% disease free survival period. They also established that NAC cleared the axilla from the malignancy and only 10% of these study population shows occult metastasis. This study creates a new outlook that SLNB can be used as criteria after NAC in prognostic purpose.

Shagi et al [1,2,8,9] LHMC studied small single institutional study over 30 patients of LABC using isosulphan blue as mapping agent after 3 cycles of NAC;SLNB done; SLN identified successfully in 26 of 30 patients; IR – 86.67% Negative predictive value – 72.73%; Accuracy- 88.46% and sensitivity 83.33%; FNR 20%.This study validated that SLNB after NAC is possible. Newman et al [1,2,7,8,9] studied on 54 patients with NAC followed by SLNB; In these patients nodal FNAC were done to confirm the malignancy. They concluded that patient who show complete regression of axillary nodes following NAC can be skipped off from the axillary dissection; IR of this study 98% and FNR 86%. Giuseppe et al [1,2,7,8,9] of Italy studied the accuracy of SLNB in 64 patients after NAC; They identified nodes in 60 patients; (i.e.93.8%).This study showed accuracy of 96.7%;negative predictive value of 91.3% and FNR of 5.1%.This study accurately identified the axillary status.

In our study, the IR of SLNB is 93.33%; sensitivity of 85.7% (12/14), specificity of > 99.9%, true positive rate of 39.4%, false negative rate of 14.3% (2/18), a negative predictive value of 88.8%.The values are comparable to the other studies and found to be significant.

V. Conclusion

Thus Sentinel lymph node biopsy is efficacious and accurate in breast cancer after neo-adjuvant chemotherapy. The Accuracy rate, Identification rate and false negative values of SLNB after NAC are comparable to the node negative breast cancer patients. SLNB may be used as a therapeutic option in patients after NAC in avoiding unnecessary axillary lymph node dissection and its complications.

References

- [1] Evaluation of Sentinel Node Biopsy in Locally Advanced Breast Cancer Patients Who Become Clinically Node-Negative after Neoadjuvant Chemotherapy: A Preliminary Study
- [2] Shaji Thomas, Apurva Prakash, Vinay Goyal, Manju Bala Popli, Shilpi Agarwal, and Monisha Choudhury
- [3] International Journal of Breast Cancer; Volume 2011, Article ID 870263
- [4] Complications of Axillary lymph node dissection for carcinoma of the breast: a report based on a patient survey.
- [5] M. A. Warmuth, G. Bowen, L. R. Prosnitz et al., Cancer, vol. 83, no.7, pp. 1362–1368, 1998
- [6] Sentinel Lymph Node Biopsy for Breast Cancer Using Methylene Blue Dye Manifests a Short Learning Curve among Experienced Surgeons
- [7] Jeffrey M. East; Christopher S.P. Valentine; Emil kanchev; Garfield O. Blake; BMC Surgery 2009;2 doi: 10.1186/1471-2482-9-2

- [8] Lymphatic Mapping Techniques and Sentinel Lymph Node Biopsy in Breast Cancer
- [9] Erika A. Newman, MD, Lisa A. Newman, MD, MPH, FACS, *Surgical Clinics of North America* 87 (2007) 353–364
- [10] Effect of Neoadjuvant chemotherapy on lymphatic pathways leading to sentinel lymph nodes in breast cancer
- [11] Shigeru Tsuyuki, Ayane Yamaguchi, Noriko Senda, Yukiko Kawata, Kosuke Kawaguchi; *Cancer Cell & Microenvironment* 2015; 2: e850. doi: 10.14800/ccm.850; 2015 by Shigeru Tsuyuki, et al
- [12] Sentinel Lymph Node Biopsy Is Accurate After Neoadjuvant Chemotherapy for Breast Cancer
- [13] By Tara M. Breslin, Lisa Cohen, Aysegul Sahin, Jason B. Fleming, Henry M. Kuerer, Lisa A. Newman, Ebrahim S. Delpassand, Rosalyn House, Frederick C. Ames, Barry W. Feig, Merrick I. Ross, S. Eva Singletary, *Journal of Clinical Oncology*, Vol 18, No 20 (October 15), 2000: pp 3480-3486
- [14] Sentinel Lymph Node Biopsy After Neoadjuvant Chemotherapy for Advanced Breast Cancer: Results of Ganglion Sentinelle et Chimiothérapie Neoadjuvante, a French Prospective Multicentric Study
- [15] Jean-Marc Classe, Virginie Bordes, Loic Champion, Herve Mignotte, François Dravet, Jean Leveque, Christine Sagan, Pierre François Dupre, Gilles Body, and Sylvia Giard; *Journal of Clinical Oncology* 2008
- [16] Sentinel lymph node biopsy using dye alone method is reliable and accurate even after neo-adjuvant chemotherapy in locally advanced breast cancer - a prospective study
- [17] Chintamani, Megha Tandon, Ashwani Mishra, Usha Agarwal, Sunita Saxena
- [18] Accuracy of sentinel lymph node biopsy after neo-adjuvant chemotherapy in patients with locally advanced breast cancer and clinically positive axillary nodes.
- [19] *European Journal Of Surgical Oncology: The Journal Of The European Society Of Surgical Oncology And The British Association Of Surgical Oncology* · June 2011 <http://www.researchgate.net/publication/51241935>