

Sodium Valproate-Induced Alopecia in A Patient of Epilepsy

Jasraj B.Panwar¹, Ishwar Chouhan², B.L.Bhardwaj³, Rakesh Tilakraj⁴,

Richa Bansal⁵

Department Of Medicine, Rajindra Hospital, Govt. Medical College, Patiala, Punjab, India

Abstract: Drug-related hair loss is not always easy to diagnose, above all because many different causal factors may be involved and the evaluation of the role played by each of these agents may be difficult. We report here a case of anagen effluvium caused by anti-epileptic and mood-stabilizing drug, sodium valproate. Medication-induced alopecia is an occasional side effect of many drugs. Sodium valproate is a well-established treatment in epilepsy and mood disorders. Its utility is compromised by its adverse effects such as tremor, weight gain, hair loss, and liver dysfunction. Hair loss may occur when drug is used in higher dose. Drug-induced hair loss is diffused and non-scarring, which is reversible upon withdrawal. Valproate induced hair loss is rare ADR of this drug.

I. Introduction

Valproate is a well-established treatment in various types of seizure like absence, generalized tonic clonic (GTC), myoclonic and atonic types, and also in mood disorders^[1]. The clinical utility of this drug may be compromised by its adverse drug reaction (ADR) such as tremor, weight gain, hair loss, and gastrointestinal disturbances, heart burn, liver dysfunction, and thrombocytopenia^[2]. Hair loss, being one of the ADR with valproate having incidence of 3.5%^[3] is diffused and non-scarring. To prevent valproate-induced hair loss, starting therapy with a low dose and progressively increasing the dose should be considered, as this strategy seems to minimize side effects^[4].

II. Case Report

A 13 year old female came to our medicine department with chief complaint of generalized tonic clonic seizure on 11/3/2014. Patient was admitted and investigated for a case of epilepsy. The complete epilepsy screening tests were performed including CBC, Electrolyte, RFT, LFT, Blood sugar, EEG, CT scan of head and MRI brain. Her blood investigations were in normal range. MRI brain report revealed mild asymmetrical volume loss of right hippocampus with increase intensity on T2 signal. Patient was put on sodium valproate 500 mg BD and was discharged in stable condition. Patient started to develop hair loss 20-25 days after starting the valproate which continued to progress over next month and resulted in diffuse non-scarring hair loss. For this reason, she consulted her physician. Diffuse hair thinning was more evident in the frontal and parietal regions. She reported important shedding during hair washing and the presence of many hairs on the pillow in the morning, after sleep. Her hair was thin, but otherwise normal, and a pull test showed a mean of nine hairs. Skin consultation was taken and advised hair trichogram and punch biopsy of scalp area was performed. The result of trichogram revealed an increase in resting hair [telogen] and dystrophic hair at the expense of growing hair [anagen] (anagen effluvium), which is classical of valproate induced hair loss. The signs of common conditions like anemia and hypothyroidism were excluded. Thyroid profile was normal and electrolytes were normal. Hair trichogram and punch biopsy of scalp of the patient revealed diagnosis of the anagen effluvium.

Neuroconsultation regarding change of epileptic medication of the patient was taken. Patient anti-epileptic medicine was modified by Tab. Sodium Valproate 500 mg OD and patient was put on Tab. Phenytoin sodium 300 mg HS. While on these two drugs patient developed maculopapular rashes and patient phenytoin was stopped and Tab. levetiracetam 500 mg was started and valproate continued to taper but patient developed seizure while decreasing these drugs dosage and patient's seizure were controlled with iv Levetiracetam and Tab. Clobazam after getting neuroconsultation. Patient was discharged on levetiracetam and clobazam with stoppage of sodium valproate and was followed up in OPD with seizure free activity and improvement of hair loss.

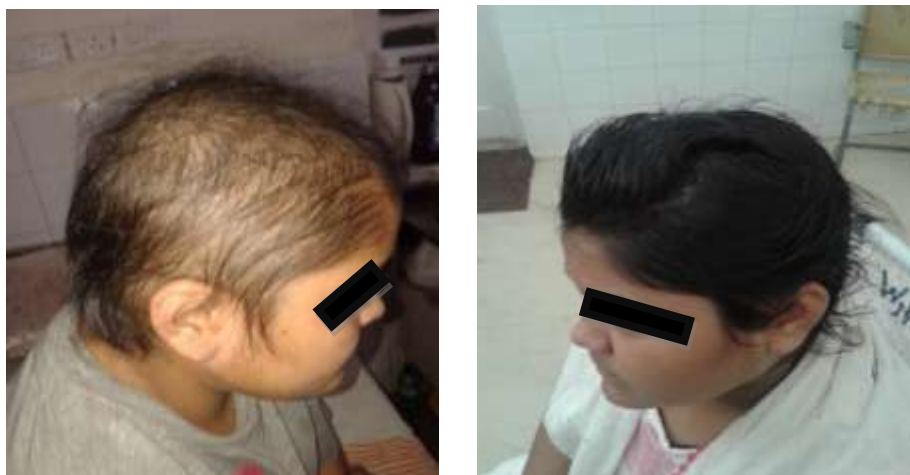

Fig. 1: While on sodium valproate **Fig. 2:** Three month after stopping of Sodium valproate

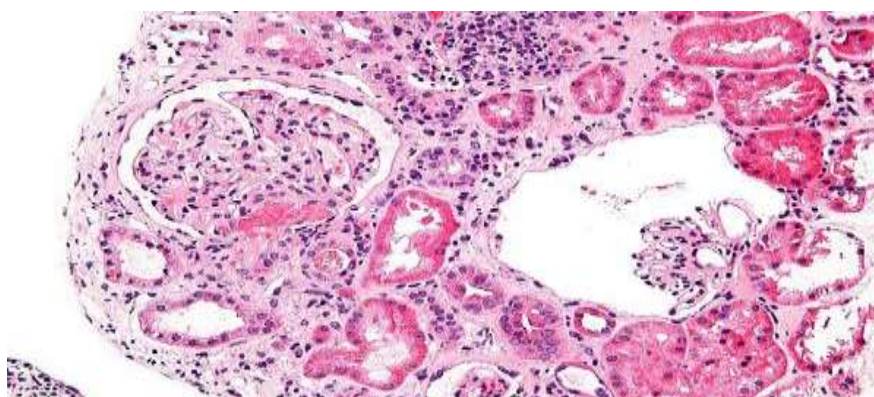


Fig. 3:

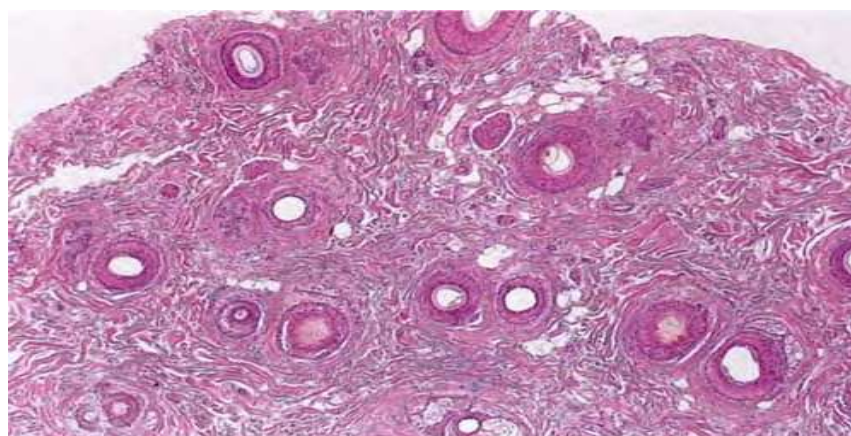


Fig. 4:

III. Discussion

Drug-induced hair loss is usually described as a diffuse non-scarring hair loss, which is reversible upon withdrawal of the drug. There is a long list of drugs that on occasion have been cited as causing hair loss like sodium valproate, lithium, carbamazepine, clomiphene citrate, oral contraceptives, potassium thiocyanate, propranolol, warfarin, olanzapine, risperidone, and many antineoplastic drugs, etc. [5]. Drugs may affect hair follicles through two main mechanisms: (i) Anageneffluvium: It is the pathologic loss of anagen or growth-phase hairs. Classically, it is caused by radiation therapy to the head and systemic chemotherapy, especially with alkylating agents [6]. (ii) Telogen effluvium (precipitating the follicles into premature rest), which may be a consequence of a large number of other drugs like anticoagulants, interferon,

and anti-hyperlipidemic drugs^[7] Telogen effluvium is a scalp disorder characterized by the thinning or shedding of hair resulting from the early entry of hair in the telogen phase (the resting phase of the hair follicle)^[8,9].

Emotional or physiological stress may result in an alteration of the normal hair cycle and cause the disorder, with potential etiologies including eating disorders, fever, childbirth, chronic illness, major surgery, anemia, severe emotional disorders, crash diets, hypothyroidism, and drugs^[6].

Diagnostic tests, which may be performed to verify the diagnosis, include a trichogram, trichoscopy and biopsy^[6]. Withdrawal of the drug almost leads to complete hair re-growth. Drug-related hair loss is not always easy to diagnose, and requires an understanding of normal hair growth and many different causal factors that are involved in it. In this patient, other causes of hair loss were excluded on the basis of the clinical presentation and the trichogram^[10]. We can also suspect that the patients who develop drug-induced hair loss have predisposing factor like hypothyroidism, but her thyroid profile was normal at the time of diagnosis^[11]. Hair loss due to use of oral contraceptives pills is quite common. However, in our case patient was not on any hormonal pills^[12].

Management of hair loss includes reassurance, hair care techniques, and if possible, drug substitution. In clinical practice, sometimes clinicians may be reluctant to discontinue medications in patients suffering from hair loss, if the valproate is otherwise efficacious. If the withdrawal of offending drug is not possible, initiating a low dose and progressively increasing the dose minimizes the side effects. Recognition of cosmetically-related side effect that might result in poor compliance in some patients is necessary^[13].

The mechanism by which valproate induces hair loss is yet to be elucidated. Deficiencies of trace elements like copper, zinc, and magnesium and inhibition of metallic enzymes that are essential for hair growth and keratinization have been suggested^[14]. The therapeutic value of mineral supplements remains unclear not tried in this case. Awareness about this potential problem that may contribute to cosmetic concerns in the patient is a must; in this way, the patient is warranted for better patient compliance.

References

- [1]. Wilting I, van Laarhoven JH, de Koning-Verest IF, Egberts AC. Valproic acid- induced hair-texture changes in a white woman. *Epilepsia*. 2007;48:400–1.
- [2]. Lamer V, Lipozencić J, Turčić P. Adverse cutaneous reactions to psychopharmaceuticals. *Acta Dermatovenerol Croat*. 2010;18:56–67.
- [3]. Oseinali E, Sadollah S, Shahriar SE. Frequency of sodium valproate-induced hair loss and curly hair. *Iran J Pharmacol Ther*. 2005;4:143–5.
- [4]. Despland PA. Tolerance to and unwanted effects of valproate sodium. *Schweiz Rundsch Med Prax* 1994; 83: 1132–1139.
- [5]. Mercke Y, Sheng H, Khan T, Lippmann S. Hair loss in psychopharmacology. *Ann Clin Psychiatry*. 2000;12:35–42.
- [6]. Freedberg, et al. (2003). *Fitzpatrick's Dermatology in General Medicine*. (6th ed.). Page 640. McGraw-Hill. ISBN 0-07-138076-0.
- [7]. Tosi A, Misciali C, Piraccini BM, Peluso AM, Bardazzi F. Drug-induced hair loss and hair growth. Incidence, management and avoidance. *Drug Saf*. 1994;10:310–7.
- [8]. Marks, James G; Miller, Jeffery (2006). *Lookingbill and Marks' Principles of Dermatology* (4th ed.). Elsevier Inc. Page 263. ISBN 1-4160-3185-5.
- [9]. Ames, William; Berger, Timothy; Elston, Dirk (2005). *Andrews' Diseases of the Skin: Clinical Dermatology*. (10th ed.). Saunders. ISBN 0-7216-2921-0.
- [10]. Harrison S, Sinclair R. Telogen effluvium. *Clin Exp Dermatol*. 2002;27:389–5.
- [11]. Shapiro J. Hair loss in women. *N Engl J Med*. 2007;357:1620–30.
- [12]. Polaneczky M, Liblanc M. Long-term depot medroxyprogesterone acetate (Depo- Provera) use in inner-city adolescents. *J Adolesc Health*. 1998;23:81–8.
- [13]. Uehlinger C, Barrelet L, Touabi M, Baumann P. Alopecia and mood stabilizers: Two case reports. *Eur Arch Psychiatry Clin Neurosci*. 1992;242:85–8.
- [14]. Patrizi A, Savoia F, Negosanti F, Posar A, Santucci M, Neri I. Telogen effluvium caused by magnesium valproate and lamotrigine. *Acta Derm Venereol*. 2005;85:77–8.