

## Rhabdoid Meningioma of Brain - Report of A Rare Aggressive Tumor.

Sajeeb Mondal<sup>1</sup>, Rajashree Pradhan<sup>1</sup>, Subrata Pal<sup>1</sup>, Sharmistha Debnath<sup>2</sup>,  
Arindam Banerjee<sup>3</sup> Debosmita Bhattacharyya<sup>4</sup>

<sup>1</sup>(Department Of Pathology, College Of Medicine And Sagore Dutta Hospital, India)

<sup>2</sup>(Department Of Oncopathology, Culcutta Medical College, India)

<sup>3</sup>(Department Of Pediatrics, College Of Medicine And Sagore Dutta Hospital, India)

<sup>4</sup>(Department Of Pathology, RG Kar Medical College & Hospital, India)

---

**Abstract:** Rhabdoid meningioma is a rare aggressive variant of meningioma, regarded as WHO grade III type. Histologically and cytologically, it is distinctive type having abundant eosinophilic cytoplasm, cytoplasmic inclusion with eccentrically placed vesicular nuclei and prominent nucleoli. High recurrence rate and poor outcome are important features. Here we are presenting a rare case of rhabdoid meningioma found in a recurrent meningioma of posterior fossa in a middle aged female. We emphasized the squash cytology and histology finding of the rare neoplasm.

**Keywords:** Rhabdoid meningioma, WHO grade III, squash cytology, aggressive.

---

### I. Introduction

Meningiomas are slow growing central nervous system neoplasm of meningotheial origin. But some of meningiomas have aggressive behaviour (WHO Grade II: atypical, clear cell and choroid and WHO grade III-papillary and anaplastic variant)[1]. Rhabdoid meningiomas are rare aggressive variant, adopted in WHO classification of CNS neoplasm (2000) and belonged to WHO grade III subtype [1,2]. This tumor is associated with rapid growth, high incidence of recurrence and poor survival than others[1,2]. Here we are reporting a rare case of rhabdoid meningioma in a middle aged male patient with an emphasis on squash cytology and histology.

### II. Case Report

A 45 year old lady presented with headache, vertigo and vomiting for last two days and altered sensorium for last one hour. She had past history of posterior fossa tumor and was operated one year back. Histologically it was diagnosed as meningotheial meningioma of posterior fossa (WHO grade I). Her haematological and biochemical tests were within normal limit except mild anemia. Electrolyte assay showed mild hyponatremia (Na-129 mmol/l). CT scan revealed a brightly contrast enhancing dural based mass at previously operated location (figure 1). Clinical and radiological diagnosis was recurrent meningioma. Her visual acuity was normal but both the fundus showed papilledema. She was undergone repeat surgery and intraoperative squash cytology was taken. The squash cytology revealed monotonous meningotheial cells arranged in lobules (figure 2A). There were some meningotheial cells with characteristic abundant cytoplasm and round nuclei pushing to periphery (rhabdoid cells)[figure 2B, 2C]. In gross examination of the resected tumor was greyish mass 5.5x4x3 cm. In histopathology, microscopy revealed a solid mass composed of meningotheial cells in sheets and in whorled pattern (figure 3A). There are areas of monomorphous sheets of cells with abundant eosinophilic cytoplasm with eccentrically placed vesicular nuclei and prominent nucleoli (figure 3B). The cells contained spherical masses of eosinophilic inclusions pushing the nuclei to periphery. Areas of necrosis and psammoma bodies are also found. Mitotic count was 4-8/10high power field. Final histopathological diagnosis was rhabdoid meningioma.

### III. Discussion

Rhabdoid meningioma is a very rare aggressive variant of meningioma [2]. Most of the meningiomas are among grade I (WHO)[2,3]. Only 5-7% meningioma are atypical (grade II) and 3% are anaplastic type (WHO grade III)[2]. Rhabdoid transformation of meningotheial tumor was first described by Perry et al in 1998[3,4]. It was included in WHO classification 2000 as a subtype of meningioma with high risk of recurrence [3]. Though cases have been reported of different age, most of the cases occur in young and middle age with an equal incidence in male and female [1,3,5]. The term rhabdoid refers to resemblance of neoplastic cells to rhabdomyoblast without true skeletal muscle differentiation [1]. Ultrastructurally, it represents whorls of intermediate filaments expressing vimentin and occasionally cytokeratin [6]. Tumor with rhabdoid morphology was initially introduced in renal neoplasm with aggressive behavior [6]. Rhabdoid morphology has been identified in different tumors like carcinomas, sarcomas, gliomas and melanoma [1].

Histologically the rhabdoid morphology cells have large round to oval with abundant eosinophilic cytoplasm, eccentrically placed nuclei with prominent nuclei [3]. Paranuclear cytoplasmic eosinophilic inclusions are frequently found [3]. Most of the cases exhibit rhabdoid morphology with histological evidence of meningotheial differentiation [3]. In our case also, the tumor exhibited typical meningotheial differentiation with areas of rhabdoid morphology. Infiltrating growth and focal necrosis is also associated features and was evident in our case. Differential diagnoses of rhabdoid meningioma include atypical teratoid/rhabdoid tumor, metastatic carcinoma, melanoma, sarcoma and mega cell meduloblastoma [1,3,5]. Histological diagnosis depends on evidence of meningotheial differentiation (whorls, nuclear characters, eosinophilic inclusion bodies), IHC findings (EMA, Vimentin & progesterone receptor positive) [1].

Recurrence rate is very high approaching about 87% [5]. In our case it was a recurrent tumor after 18 month of surgery. Radical surgery and post-operative radiotherapy of 60GY (conventional fractional) is the therapeutic modality of choice [1]. However stereotactic radio surgery, preoperative chemoembolization, combined radio-chemotherapy are the other optional modalities [2]. Median survival is less than three years after surgical resection with adjuvant therapy [2].

### Figures and Tables

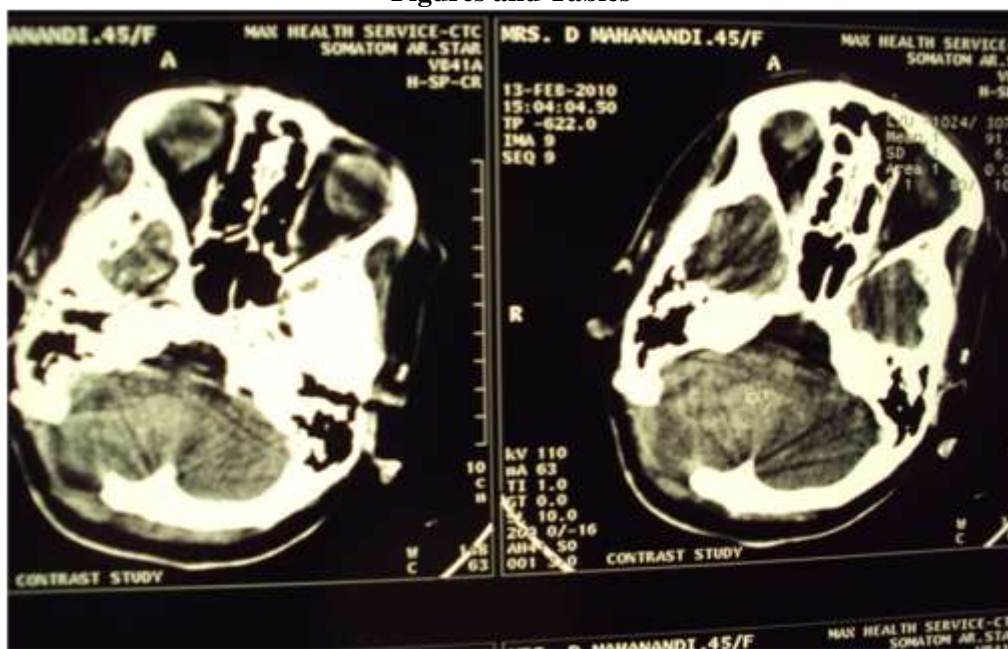


Figure 1: CT scan image of the recurrence of posterior fossa tumor at previously operated site.

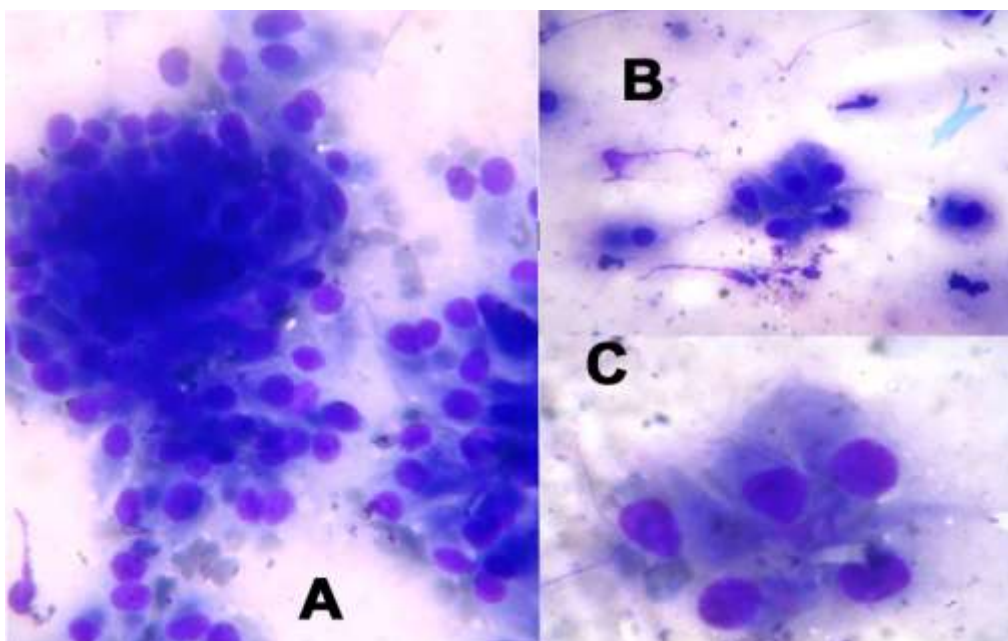
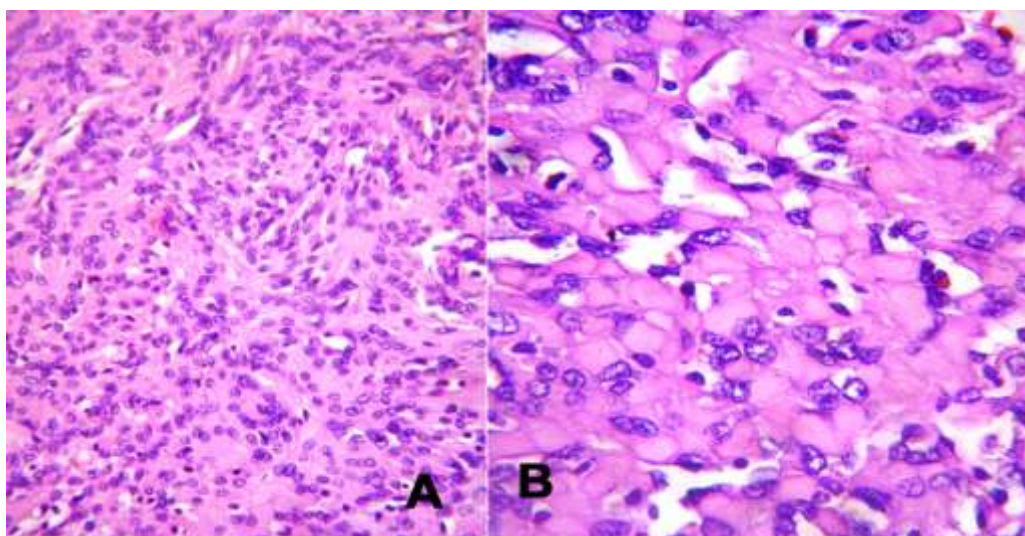


Figure 2: A-Photomicrography of squash cytology of meningioma showing whorl clusters of meningothelial cells [Leishman and Giemsa stain, 40X view]. 2B, 2C: Squash cytology of meningothelial cells with rhabdoid morphology (abundant cytoplasm, large eccentric nuclei) [L & G stain, 40X view].



**Figure 3:** A- Photomicrograph of histology of the area showing whorled pattern of typical meningothelial cells without significant anaplasia [H &E stain, 40X view]. 3B: Photomicrograph of histology of the area of monomorphous sheets of cells with abundant eosinophilic cytoplasm, intra-cytoplasmic inclusions, eccentrically placed vesicular nuclei and prominent nucleoli; typical of rhabdoid meningioma [H & E stain, 40X view].

### References

- [1]. Kar A, Rath G, Mohanty L, Behera P, Mohapatro S, et al. Rhabdoid Meningioma-An Uncommon and Aggressive Variant. *J Cancer Sci Ther* 2013; 5: 343-5.
- [2]. V Kakar, A Elsmore. Rhabdoid Meningioma: Rare And Highly Aggressive. *The Internet Journal of Neurosurgery*. 2005;3(2).
- [3]. Matyja E, Grajkowska W, Nauman P, Bonicki W, Bojarski P, Marchel A. Necrotic rhabdoid meningiomas with aggressive clinical behaviour. *Clin Neuropathol* 2010;29:307-16.
- [4]. Perry A, Scheithauer BW, Stafford SL, Abell-Aleff PC, Meyer FB. Rhabdoid meningioma: an aggressive variant. *Am J Surg Pathol* 1998; 22:1482-90.
- [5]. Han H, Du P, Zhang Y, Deng Y. Diagnosis and Differential Diagnosis of Rhabdoid Meningioma: One Case Report and Literature Review. *Clin Oncol Cancer Res* 2009;6:303-6.
- [6]. Jansen JC, Turner J, Sheehy J, Fagan PA. Recurrent Rhabdoid Meningioma: Case Report. *Skull Base* 2003;13:51-4.