

Palmaris Longus Tendon and Its Association with Incomplete Superficial Palmar Arch

Janani Maheshwari .V. Vyas¹, Showri.R², Senthil Kumar. S³

¹(PhD Scholar, Department Of Anatomy, Sri Ramachandra University, Chennai, India)

²(Department Of Anatomy, Sri Ramachandra University, Chennai, India)

³(Professor, Department Of Anatomy, Sri Ramachandra University, Chennai, India)

Abstract: Palmaris longus muscle, a weak flexor of the hand at the wrist, is well known for its morphological variation and records an agenesis of 10%. Two upper limbs lacking Palmaris Longus Muscle also exhibited incomplete Superficial Palmar Arch [SPA]. Upon reviewing the literature, it was found that only few such cases were reported. Hence, an attempt has been made to study the relationship between the absence of Palmaris longus muscle and occurrence of incomplete SPA. The outcome shall benefit anatomists, hand surgeons, orthopaedicians and cardiologists alike.

Keywords: Palmaris longus absence, Superficial Palmar Arch variation, Ulnar artery.

I. Introduction

Palmaris longus (PL) is one of the most variable muscles in the human body. It is a retrogressive muscle and its tendon is used as a first choice donor tendon [1].

It is continuous with the central part of palmar aponeurosis which protects the chief source of arterial blood to the palm, the superficial palmar arch.

The leading source of arterial supply to the palm is provided by the SPA which is formed by the anastomoses between ulnar artery and the superficial palmar branch of the radial artery (SPRA). This morphology is the classic type. However, the SPA is not always complete. Sometimes, it is incomplete when there is no anastomosis between the arteries forming the SPA.

Sherman.S.Coleman and Barry.J.Anson (1961) divided the incomplete arch type into five subtypes: Type A – Both the superficial palmar branch of the radial artery and the ulnar artery take part in the supply to the palm and fingers but, in doing so fail to anastomose; Type B – The ulnar artery is the SPA. The arch is incomplete in the sense that the ulnar artery does not take in the supply to the thumb and index finger; Type C – The superficial vessels receive contribution from both median and ulnar arteries but without anastomosis; Type D – The radial, median and ulnar arteries- all give origin to the superficial vessels but do not anastomose [2].

The knowledge of the vascular pattern in the palm is important as the radial artery is used for Coronary artery bypass grafting [CABG] procedures [3]. In case of a complete arch, if the radial artery is harvested, ulnar artery compensates for the arterial supply to the remaining fingers via the SPA. If it is an incomplete arch, compensation in the case of CABG and traumatic injuries is not possible and this leads to gangrene of fingers as there is absence of collateral blood flow [4].

Interestingly, Showri.R and SenthilKumar.S (2016) observed 8 ulnar dominant complete SPA where the ulnar artery formed the complete arch without SPRA joining it and terminated by giving a branch to radial side of the index finger and thumb [5].

According to Elizabeth O'Sullivan & Barry S. Mitchell (2002) absence of PL tendon may be a predictor of the pattern of SPA and this may be relevant in identifying suitable patients for surgery involving vascular supply to hand [6].

Loukas et al (2005) stated that the SPA formed by the linkage between SPRA and Ulnar Artery [UA] is not the most commonly observed morphology always [7].

This study is an attempt to report the correlation between absence of palmaris longus tendon and incomplete superficial palmar arch.

II. Materials and method

20 upper limbs were utilized for the present study. The forearm and palm were dissected and the branches of the arteries forming the SPA were traced after removing the palmar aponeurosis. The presence or absence of PL tendon and the pattern of the SPA was noted.

III. Observations And Results

Eighteen hands out of twenty specimens (90%) exhibited complete type of SPA and had presence of PL tendon. Two hands (10%) showed no anastomoses between radial artery and ulnar artery (Incomplete SPA). Both the hands in turn showed absence of PL tendon.

Table 1: Presence and absence of PL tendon in comparison with the type of SPA

Presence/ Absence Of Pl Tendon	Number Of Hands	Type Of Spa	Percentage	Side	Number
Presence	18	Complete	90%	Right	9
				Left	9
Absence	2	Incomplete	10%	Right	1
				Left	1

A rare variation was encountered in the two hands that showed incomplete type of SPA and absence of PL tendon. The SPA was of the incomplete type i.e there was no anastomoses between the ulnar artery and the superficial palmar branch of radial artery. The ulnar artery in both the hands gave rise to three common palmar digital arteries [CPDA] that proceeded distally towards the 2nd, 3rd and 4th inter digital spaces. The radial artery gave rise to two branches. One branch supplied the radial side of the thumb and the other branch joined the deep palmar arch. Both the hands belonged to the same cadaver which was of a female aged about 55 years. Fig.

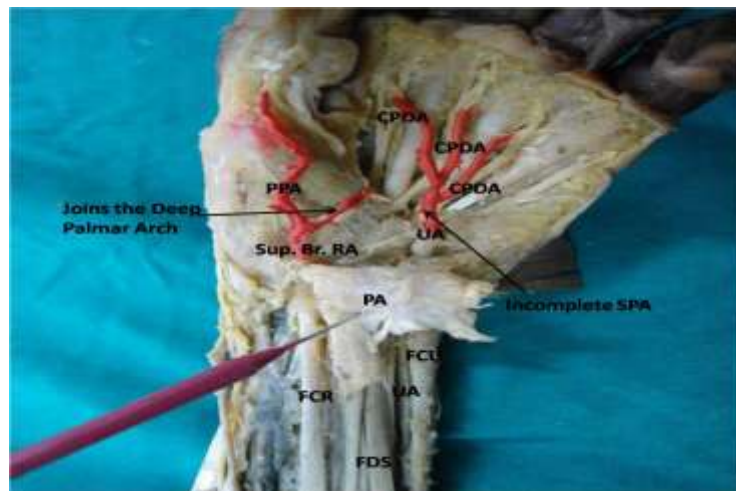


Figure: Absence of PL muscle tendon and Incomplete SPA [Left Upper Limb]–
PPA: Princeps Pollicis Artery; PA- Palmar Aponeurosis; FCR- Flexor Carpi Radialis; FDS- Flexor Digitorum Superficialis; FCU- Flexor Carpi Ulnaris; Sup.Br. RA – Superficial Branch of Radial Artery; CPDA- Common Palmar Digital Artery; UA- Ulnar Artery

IV. Discussion

In the present study, PL tendon was present in 18 hands and absent in 2 hands. The 18 hands in which PL tendon was observed displayed complete type of SPA whereas the 2 hands which showed absence of PL tendon exhibited incomplete type of SPA. This incidence corresponds to the findings of Elizabeth O’ Sullivan & Barry S. Mitchell (2002) in which 47% hands showed abnormal SPA and PL tendon was absent in these hands. The remaining hands in which the PL tendon was present was associated with normal SPA [6]. Although the percentage in this study was lower than that of Sullivan O’ E & Mitchell SB (2002), it was similar to it wherein SPA abnormality was associated with absence of PL tendon.

In the study by Suleyman Murat Tagil et al (2007), absence of PL was found in 4 hands out of which two hands had complete type and 2 hands had incomplete type of SPA. And, eight hands showed presence of PL tendon and these hands had complete SPA [8].

The present study showed only two hands with incomplete SPA. Even though the findings in the present study match with that of Elizabeth O’ Sullivan & Barry S. Mitchell (2002), it is difficult to come to a conclusion that PL tendon will be present only in the hands with complete SPA and absent in hands with incomplete SPA.

Caughell et al (1988) suggests that patients should be evaluated in detail before surgical procedures depending on SPA or its components [9].

Suleyman Murat Tagil et al (2007) suggest that the hand surgeon can have an idea about the existence of an anomalous arch simply by checking the presence of PL tendon [8].

Incomplete SPA was found in 21.5% in Coleman and Anson's (1961) study on arterial patterns in the hand in 650 specimens [2]. Among the incomplete type it was seen that in 3.2% cases, SPRA and UA take part in the arterial supply to the palm, but fail to anastomose (type A), 13.4% where UA forms the SPA entirely but does not supply the thumb and the index finger (type B), 3.8% of mediano – ulnar type with no anastomoses (type C) and 1.1% radio mediano – ulnar type with no anastomoses (type D). The present case showed type A bilaterally.

A slightly lower incidence was observed in the studies by Turk and Metcalf (1984) who observed it in 16% [10] and Marios Loukas et al (2005) and Sujatha Salgado et al (2009) in 10% and 12% respectively [7,11].

In an anatomical study on SPA by Suma M.P et al (2014), complete type of SPA was found in 19 hands out of 20 and 1 hand (5%) showed incomplete type [12] which is similar to our study which reported complete type in 18 hands out of 20 and incomplete type in two hands (10%) TABLE 1. But there was no comparison with presence or absence of PL tendon in that study.

V. Conclusion

This study suggests a relation between absence of PL tendon and incomplete SPA. However, the present study and various other related studies were all done in few specimens. Further studies should be carried out in larger number of specimens and among different races to check if there is a relationship between palmaris longus tendon and superficial palmar arch. The developmental aspect can also be studied.

References

- [1]. Mangala M. Pai, Latha V. Prabhu, S. R. Nayak, S. Madhyastha, Rajanigandhavadgaonkar, A. Krishnamurthy, A. Kumar. The Palmaris Longus Muscle: Its Anatomic Variations And Functional Morphology. Romanian Journal Of Morphology And Embryology 2008, 49(2):215–217
- [2]. Coleman SS, Anson BJ. Arterial patterns in the hand based upon the study of 650 specimens. Surg Gynecol Obstet. 1961; 113: 409–424.
- [3]. Azian A. Latiff ; FaizahOthman ;Fariyah H. Suhaimi ; Srijit Das. Anomalous superficial palmar arch: A cadaveric study with clinical implications. 2008. Archives of Medical Science, 4(2), 197-199.
- [4]. Srinivasa Rao, VenkataRamanaVollala, Narendra Pamidi, SomayajiNagabhooshana, and Bhagath Kumar Potu. Variant formation and distribution of the superficial palmar arch. Indian J Plast Surg. 2010 Jan-Jun; 43(1): 116–117.
- [5]. Showri. R, SenthilKumar. S. A study on ulnar dominant complete superficial palmar arch. Int J Anat Res 2016;4(3):2587-2589.DOI: 10.16965/ijar.2016.281s
- [6]. Elizabeth O'Sullivan and Barry S Mitchell. Association of the absence of palmaris longus tendon with an anomalous superficial palmar arch in the human hand. J Anat. 2002 Nov; 201(5): 405–408.
- [7]. Loukas M, Holdman D, Holdman S. Anatomical variations of the superficial and deep palmar arches. Folia Morphol. 2005 May; 64(2):78-83.
- [8]. Süleyman Murat Tađyl ,AynurEmineÇiçekcibaşý , TunçCevatÖđün, Mustafa Büyükmumcu, Ahmet Salbacak. Variations and Clinical Importance of the Superficial Palmar Arch. S.D.Ü. TýpFak. Derg. 2007;14(2)/ 11-16
- [9]. Caughell KA¹, McFarlane RM, McGrouther DA, Martin AH. Developmental anatomy of the palmar aponeurosis and its relationship to the palmaris longus tendon. J Hand Surg Am. 1988 Jul; 13(4):485-93.
- [10]. Al-Turk M, Metcalf WK. A study of the superficial palmar arteries using the Doppler Ultrasonic Flowmeter. J Anat 1984; 138: 27 – 32.
- [11]. Salgado L S S, Hasan R, Perera A A M M S L, Wijesundara W M R D, Anuradha W K. Variations of the Superficial Palmar Arch in a Sri Lankan Perspective: A Cadaveric Study. GSTF Journal of Advances in Medical Research (JAMR) Vol.1 No.2, October 2014
- [12]. Suma M.P, Vijay Kumar S, PriyaRanganath. An anatomical study of superficial palmar arch. Int J Anat Res 2014, Vol 2(4):735-39. ISSN 2321- 4287