

A Study of Additional Pair of Sacral Foramina in Eastern Indian Dry Sacra

Gyanaranjan Nayak

Department of Anatomy, I M S and SUM Hospital, S O A University, Bhubaneswar, Odisha, India.

Abstract: Occurrence of five pairs of sacral foramina is an anatomical variation which may be due to sacralisation of fifth lumbar vertebra or first coccygeal vertebra. Sacralisation of lumbar vertebra may lead to compression of fifth sacral nerve causing backache and sciatica. It may be associated with prolapse of intervertebral disc above the sacralisation. On the other hand sacralisation of coccygeal vertebra may result in prolongation of second stage of labor and perineal tear.

Aim- To study the incidence of fifth pair of sacral foramina and ascertain their clinical importance.

Methods and material- Eighty human dry sacra were studied macroscopically and they were observed for additional pairs of sacral foramina.

Statistical analysis used- The data was compiled and analysed using Microsoft Excel's software.

Results- Out of 80 sacra, sixteen numbers of sacra (20%) showed a fifth pair of sacral foramina. Twelve sacra (15%) showed sacralisation of lumbar vertebra whereas four cases (5%) presented with sacralisation of coccygeal vertebra.

Conclusion- We found variation in the number of sacral foramina in the studied sacra. This knowledge is relevant to the anaesthesiologists for performing trans-sacral nerve blocks. And radiologists should bear this variation in mind while interpreting radiographs of lumbo-sacral region. The knowledge of such variation is also helpful for neurologists and orthopedicians while evaluating back pain.

Key Words: Sacrum, Caudal Anaesthesia, Sciatica.

I. Introduction

The sacrum is a triangular piece of bone wedged between the two hip bones. It is formed by the fusion of five sacral vertebrae constituting four pairs of sacral foramina. The sacrum has a blunt caudal apex that articulates with the coccyx and its wide base articulates with the fifth lumbar vertebra. The fifth lumbar vertebra may fuse with the sacrum which is called sacralisation of lumbar vertebra. And the sacrum may also fuse with the first coccygeal vertebra which results in sacralisation of coccygeal vertebra. Both the cases described above present with five pairs of sacral foramina¹.

Sacralisation of lumbar vertebra may compress the fifth sacral nerve manifesting as sciatica and back pain. Sacralisation may be kept in mind in case of young individuals presenting with back pain. Lumbar sacralisation may pose difficulty in identifying the lumbar level corresponding to an emerging nerve root at the time of spinal block. This makes radiological examination necessary before lumbar epidural injection or selective nerve root block if lumbar sacralisation is suspected². Lumbar sacralisation may not cause nerve root compression by itself³. However sacralisation of fifth lumbar vertebra causes an increased risk of early degeneration of the upper intervertebral disc. And the disc herniation may result in development of nerve root symptoms^{4,5}. Sacralised fifth lumbar vertebra is associated with poor obstetric outcome. There is delay in engagement of head of the fetus during labor. There are chances of difficult labor as lumbar sacralisation may induce occipitoposterior position. And labor may be prolonged as descent of head takes longer in a longer birth canal⁶.

Coccygeal sacralisation has also got its own clinical significance. Coccygeal sacralisation can be the culprit behind the failure of caudal anaesthesia due to passage of the fifth sacral and first coccygeal nerves in the fifth pair of sacral foramina. Coccygeal sacralisation also leads to fixation of the coccyx, as a result of which the anteroposterior diameter of the pelvic outlet cannot be increased during labor. This results in prolonged labor, perineal tear and creates problems in forceps delivery⁷.

The knowledge of sacralisation of lumbar or coccygeal vertebra leading to variation in the number of sacral foramina is highly significant for physicians, orthopaedic surgeons, anaesthesiologists and obstetricians. So we undertook the present study to find out the variation in the number of sacral foramina and correlate it with sacralisation.

II. Materials And Methods

Our study included 80 dry human sacra available in a Medical College in Bhubaneswar, Odisha. All the sacra were macroscopically examined and the number of the paired sacral foramina in each sacrum was noted. The sacra with additional pair of sacral foramina were photographed. The data was compiled and analysed.

III. Results

Sixty four sacra (80%) were found to be normal and presented with four pairs of sacral foramina. Rest sixteen sacra (20%) showed the presence of five pairs of sacral foramina. Twelve of the abnormal sacra (15%) showed lumbar sacralisation. Only four of the variant sacra (5%) showed coccygeal sacralisation. Table-1 shows the incidence of additional pairs of sacral foramina.

The fusion of the fifth lumbar vertebra to the first sacral vertebra was complete in the twelve sacra showing lumbar sacralisation. However in the sacra presenting with coccygeal sacralisation the fusion was incomplete and hence the fifth pair of sacral foramina found in them were incomplete as well. Figure-1 shows sacrum with five pairs of sacral foramina due to lumbar sacralisation. Figure-2 shows sacrum with five pairs of sacral foramina due to coccygeal sacralisation.

Category	Frequency	Incidence (%)
Lumbar sacralisation	12	15%
Coccygeal sacralisation	4	5%

Table 1 The incidence of lumbar and coccygeal sacralisation in sacra showing a fifth pair of sacral foramina in the present study

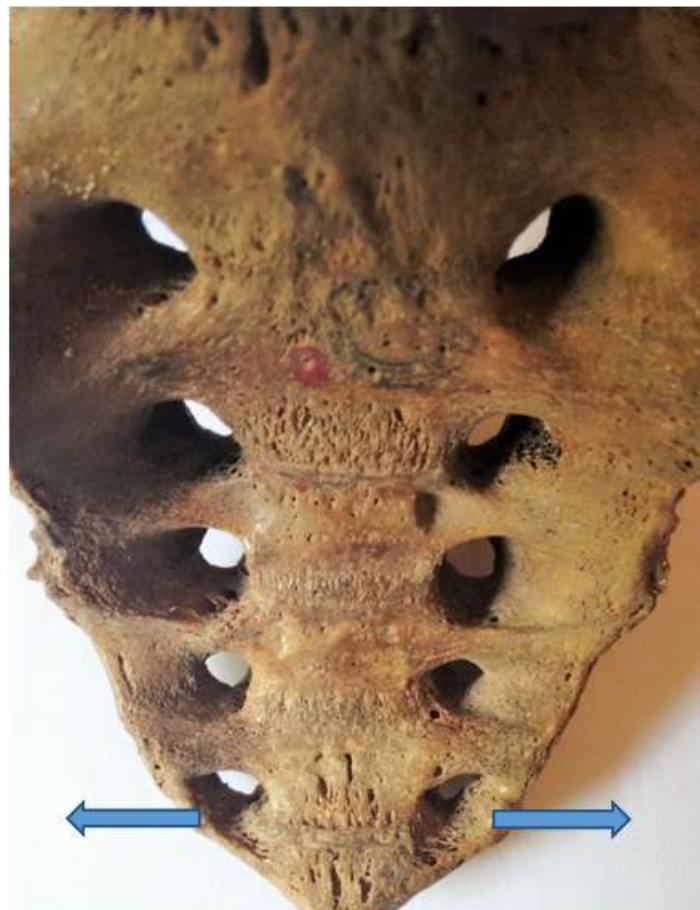


Fig 1(a) Photograph of ventral surface of sacrum showing a fifth pair of sacral foramina due to sacralisation of lumbar vertebra.

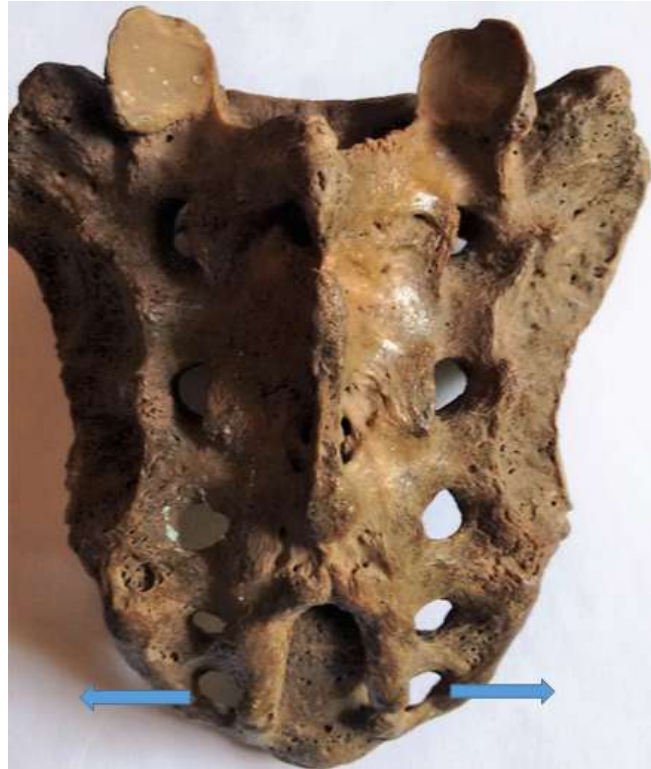

Fig 1(b) Photograph of dorsal surface of sacrum showing a fifth pair of sacral foramina due to sacralisation of lumbar vertebra.

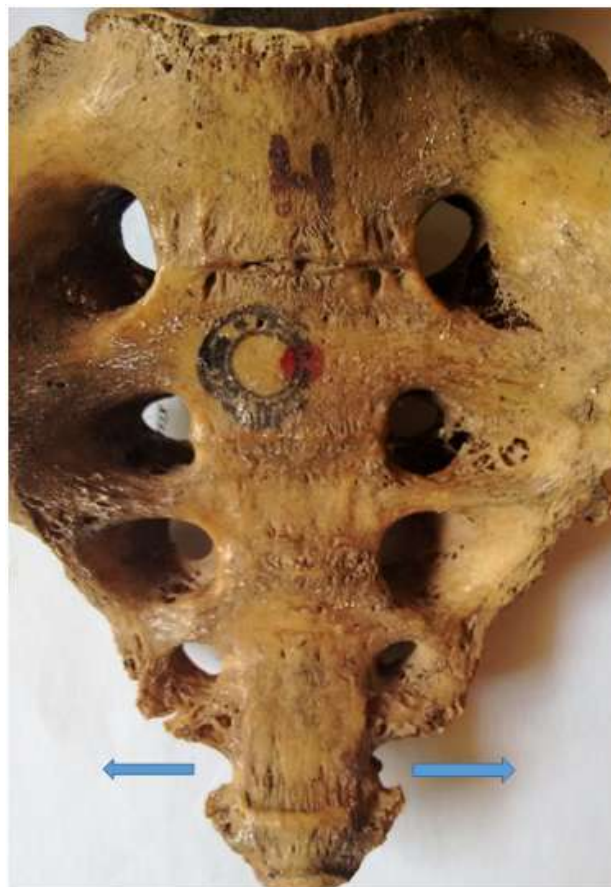

Fig 2(a) Photograph of ventral surface of sacrum showing a fifth pair of sacral foramina due to sacralisation of coccygeal vertebra. The fifth pair of sacral foramina are incomplete.

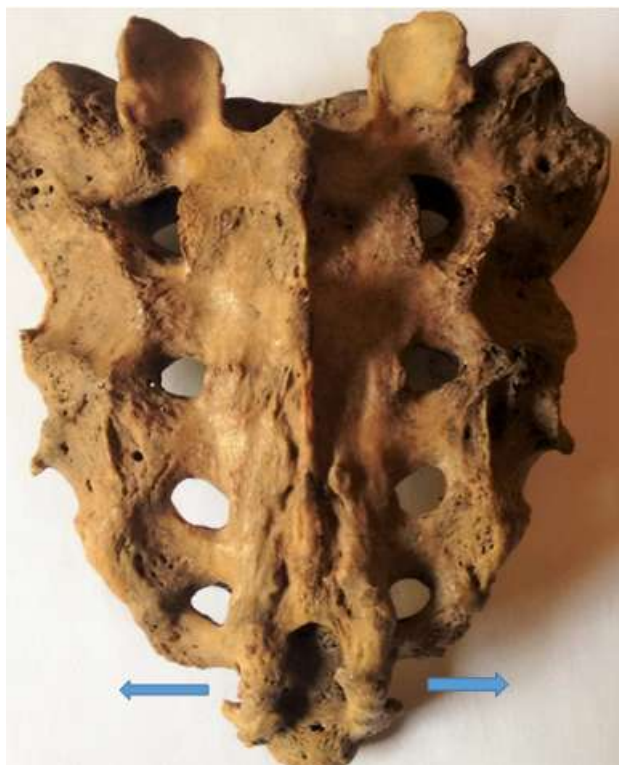

Fig 2(b) Photograph of dorsal surface of sacrum showing a fifth pair of sacral foramina due to sacralisation of coccygeal vertebra. The fifth pair of sacral foramina are incomplete.

IV. Discussion

The incidence of lumbar sacralisation in our study was comparable to the findings of Singh⁶ who has reported an incidence of 16.6%. Swargam et al⁸ have reported the incidence of lumbar sacralisation in their study as 10%. Kamal et al⁹ have reported an incidence of 21.1% of sacralisation in their study. However Goswami et al¹⁰ have reported the incidence of lumbar sacralisation as 2.5% and Chaijaroonkhanarar et al¹¹ have reported an incidence of 4.4%.

There is very little literature about sacralisation of coccygeal vertebra. Singh⁶ has reported an incidence of 13.6%. Sacralisation can be regarded mostly as a congenital anomaly. Other factors responsible for sacralisation are traumatic back injury, extreme arthritic changes in old age and iatrogenic spinal fusion surgery⁷. Sacralisation, as discussed in the following paragraphs may also have a genetic basis. Formation of vertebral bodies and neural arches are regulated by the respective homeobox and paired-box genes Pax 1 and Pax 9^{12,13}.

Peter et al¹³ have reported that, in transgenic mice deficient for one functional copy of Pax 1, mutation in Pax 9 may result in vertebral malformations in lumbar region like fused vertebrae, split vertebrae and ossified fusion between vertebrae and neural arches. So it may lead to fusion between fifth lumbar vertebra and first sacral vertebra and the fifth lumbar vertebra may get sacralised.

Wellik et al¹⁴ have put forward that, Hox genes are indeed involved in global patterning of mammalian axial skeleton. They mention that Hox 10, Hox 11 triple mutants both severely affect sacral formation. These paralogous mutants according to them result in complete loss of lumbar or sacral vertebrae, but the total number of vertebral elements are not altered. Thus Wellik et al predict that shifts in the expression of Hox 11 paralogous genes would result in alteration in position and number of sacral vertebrae. This might provide a basis for sacralisation of coccygeal vertebra.

V. Conclusion

Our study highlights that presence of an additional pair of sacral foramina arises due to sacralisation of lumbar or coccygeal vertebra. And sacralisation not only poses a challenge in anaesthetic and obstetrics practice but also indicates that defective regulation of Homeobox and Paired-box genes may be the basis of the anatomical variation.

References

- [1]. Platzer W. Color Atlas of Human Anatomy, Volume- 1; Locomotor system, 8th Ed, Stuttgart, Thieme.2008: 11.
- [2]. Hughes RJ and Saifuddin A . Numbering of Lumbosacral Transitional Vertebra on M R I ; Role of the iliolumbar ligaments. Am. J. Roentgenol.;2006; 187 (1): W 59-65.
- [3]. Otani K, Konno S, Kikuchi S. Lumbosacral transitional vertebra and nerve-root symptoms; J. Bone Joint Surg Br;2001;83(8): 1137-40.
- [4]. Kong CG, Park JS, Park JB. Sacralisation of L₅ in Radiological Studies of Degenerative spondylolisthesis at L₄-L₅ ; Asian Spine J; Jun 2008; 2(1):34-37.
- [5]. Berlemann U, Jeszenszky DJ, Buhler DW, Harms J. The role of lumbar lordosis, Vertebral end-plate inclination, disc height and facet orientation in degenerative spondylolisthesis. J Spinal Disord; 1999; 12: 68-73.
- [6]. Singh R. Classification and analyses of fifth pair of sacral foramina in Indian dry sacra; Int J Morphol; 2014; 32(1): 125-130.
- [7]. Nagar S K, Khubavat D, Malukar O, Varlekar P, Rathod H, Chauhan P. A Study of Sacralisation of Coccygeal Vertebra in Gujrat. N J I R M, 2012; 3(3);July – August: 39-42
- [8]. Swargam N, Chandruptla M. Sacralisation of fifth lumbar vertebra; International Journal of Recent Scientific Research; June, 2014; Vol. 5; Issue 6; 1159-1160 .
- [9]. Kamal AHM M, Ara S, Begum S, Hoque MM, Khatun K. Bangladesh Journal of Anatomy; 2013; Vol 11; No 2; 54-57 .
- [10]. Goswami P, Yadav Y, Chakradhar V. Sacral Foramina: Anatomical Variations and Clinical Relevance in North Indians; European Journal of Academic Essays; 2014; 1(4); 29-33 .
- [11]. Chaijaroonkhanrar W, Umka J, Buranarugsa M, Namking M. Sacralisation of 5_{th} lumbar vertebra in Thais; Srinagarind Med J; 2006; 21(3): 194-199.
- [12]. Wallin J, Mizutani Y, Imai K, Miyashita N, Moriwaki K, Taniguchi M, Koseki H, Balling R. A new Pax gene, Pax 9, maps to mouse chromosome 12; Mamm. Genome; 1993; 4(7):354-8.
- [13]. Peter H, Wilm B, Sakai N, Imai K, Maas R, Balling R. Pax 1 and Pax 9 synergistically regulate vertebral column development; Development; 1999;126(23): 5399-408.
- [14]. Wellik DM, Capecchi M. Hox 10 and Hox 11 genes are required to globally pattern the mammalian skeleton; Science; 2003; 301(5631):363-7.