

A Study of Incisional Hernia Repair with Octomesh

Dr. ChandraKant Paliwal¹, Dr. Dinesh Kumar Jindel², Dr. KannoMal Garg³

¹Associate Professor, Department Of Surgery, Institute For Medical Sciences And Research Centre, JNU, Jaipur, Rajasthan, India.

²seniorconsultant Surgeon, Apollo Hospital, Jaipur

³Professor & Head, Department Of Surgery, Institute For Medical Sciences And Research Centre, JNU, Jaipur, Rajasthan, India.

Abstract: Incisional Hernia is a common surgical condition. Mesh repair technique showed reduced number of postoperative complications and recurrence compared to other techniques. The aim of the study was to evaluate the technique of mesh repair of incisional hernias with octomesh. This prospective study consisting of 30 cases was done. Octomesh repair was done in all the 30 cases. Follow up of 6 to 12 months was carried in the OPD of Institute for Medical Sciences and Research Centre, JNU, Jaipur, Rajasthan, India with regards to postoperative complications and recurrences if any. Recurrence of only 6 was noticed in the present study. Less number of postoperative complications were noticed in the present study. It was concluded that octomesh repair is one of the effective techniques for incisional hernia repair.

Keywords: Incisional hernia, octomesh, postoperative complication.

I. Introduction

Incisional hernia is defined as a defect occurring through the operative scar. It is one of the most common conditions requiring major surgery despite advances in surgical techniques and suture material. The incidence of incisional hernia in literature is 2- 11% following all laparotomies¹ and it is a source of morbidity and requires high health care costs. . It is seen more in females, obese and older age group. As a result of high recurrence rate in the repair of incisional hernia, various types of repairs have been used both anatomical and prosthetic. But the results have been disappointing with a high incidence of recurrence-about upto 50% after an anatomical repair and upto 10% following prosthetic mesh repairs^{2,3,4}.

One of the newer options for open ventral hernia repair, this procedure consists of the Octomesh synthetic polypropylene implant with eight securement straps and a unique delivery device that enables placement during open ventral hernia surgery. The device is used to perform a "tension-free" repair of certain types of ventral hernia. Octomesh has a flat mesh component that covers the hernia defect plus eight securement straps that hold the mesh in place. The flat mesh serves as a frame into which tissue will grow. Clinical results with Octomesh to date have shown very low levels of pain, immediately after surgery and more than five years after the operation.

The surgeon makes an incision above the hernia to dissect out the hernia sac and removes adhesions. Once free, the hernia sac and its contents are returned to the abdomen. The straps secure the implant using normal tissue friction without the need for fixation by sutures or tacks, which are often thought to be a cause for post-op and chronic pain. After Surgery Complications with the Freedom Octomesh Hernia Repair System have been studied and are shown to be very rare.

The introduction of prosthetics has revolutionized hernia surgery with the concept of tension free repair. The implantation of prosthetic mesh remains the most efficient method of dealing with incisional hernia⁵. The prosthetic mesh can be placed between the subcutaneous tissues of the abdominal wall and the anterior rectus sheath (onlay mesh repair) as well as in the preperitoneal plane.

The key difference is that the Octomesh implant is designed in a way that enables the surgeon to cover the hernia defect broadly but with less tissue dissection while placing the implant behind the muscles. With the Strap Technique, the Octomesh doesn't have to be sutured or tacked in place, therefore reducing the risk of chronic pain associated with these fixation methods. The eight straps are placed in the tissue with the delivery device and held in place through normal tissue friction.

The present study was undertaken to evaluate the technique of preperitoneal octomesh repair of incisional hernias with regards to post operative complications and recurrences.

II. Material And Methods

This prospective clinical study consists of 30 patients with incisional hernia managed by Preperitoneal mesh repair in Institute for Medical Sciences and Research Centre, JNU, Jaipur, Rajasthan, India during the period from April 2016 to November 2016. The patients who were admitted to surgical wards, diagnosed to

have incisional hernia and managed by Preperitoneal mesh repair were included in this study. All patients underwent thorough clinical examination and a detailed history and details of earlier operation were asked for. All patients were evaluated for systemic disease or precipitating cause. Patients who had hypertension, diabetes mellitus or cough were controlled preoperatively. Routine investigations were done for all patients including chest x-ray and ultrasonography of the abdomen. A day prior to surgery, shaving of the abdomen and genitalia was done.

A nasogastric tube and Foley's catheter was passed and broad-spectrum antibiotics was given to all patients before the procedure. Patient was explained about the effects and complications of the procedure. The procedure was done under general anaesthesia, spinal or epidural anaesthesia in supine position.

In all cases, old operative scar was excised, generous skin incision were used to permit adequate exposure of hernial sac and defect. The sac was opened and contents were reduced after lysis of the adhesions. The surgeon then prepares the area to insert the mesh implant. After the area is prepared, the Octomesh implant is inserted. The implant will reinforce the repair and surrounding tissue. The eight straps are tunneled through the lateral part of the tissue with the delivery device.

Sizes of Octamesh Available	Measurement
XS	12cmX15cm
S	15 cm X 25 cm
M	20 cm X 30 cm
L	28 cm X 35 cm
XL	35 cm X 40 cm

Fig.1-Sizes of Octomesh

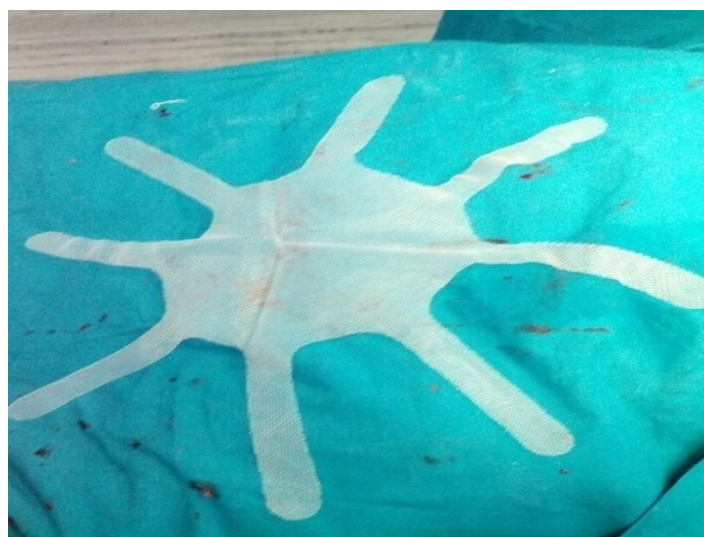

Fig.2-Octomesh

The excess sac was excised, peritoneum was closed with absorbable synthetic suture. Adequate preperitoneal plane was prepared between the posterior rectus sheath and peritoneum, mesh was placed and fixed with prolene no. 2-0 or 3-0 sutures. Suction drains were laid on the mesh and brought out through separate stab wounds.

Muscular aponeurotic structures were repaired with prolene no.1 suture. Skin was closed after insertion of suction drain in subcutaneous plane. In the postoperative period, nasogastric aspiration was done, every two hourly in first 24 hours.

The nasogastric tube was removed once the patient passed flatus. Foley’s catheter was removed on postoperative day one. Suction drain was removed once the drainage falls to 25 to 30 cc. Antibiotics were continued for five days. Postoperatively, deep breathing exercises, movement of limbs in bed was advised as soon as patient recovered from anaesthesia. Early limited ambulation was done once the patient was able to bear the pain. Skin sutures removed on 10th day and in few cases after 10th day. At discharge, patients were advised to avoid carrying heavy weights and advised to wear abdominal belt. Patients were reviewed after one month and three months in all cases. At review, symptoms were asked for and operative site examined for any recurrence. These cases were then analyzed and results were compared with existing literature. An extensive review of literature is carried out.

III. Results

A prospective clinical study consisting of 30 patients with Incisional hernia who were managed by preperitoneal mesh repair is undertaken to investigate the role of preperitoneal mesh repair and its postoperative complications.

Thirty patients underwent preperitoneal mesh repair of incisional hernia during eight month study from April 2016 to November 2016. The youngest patient was 26 years old and the oldest was 70 years old. Twenty four patients were females which outnumbered the six male patients.

The female to male ratio was 4:1 showing that incidence of incisional hernia is higher in females. In all the thirty patients, hernia appeared within two years after surgery, 18 developed incisional hernia in first year while rest had in second year.

Table 1: Mesh size and no. of cases it was used in.

Mesh Size	No. of Cases
XS	4
S	23
M	2
L	1

Table 2: Age wise Distribution of Patients with Incisional Hernia

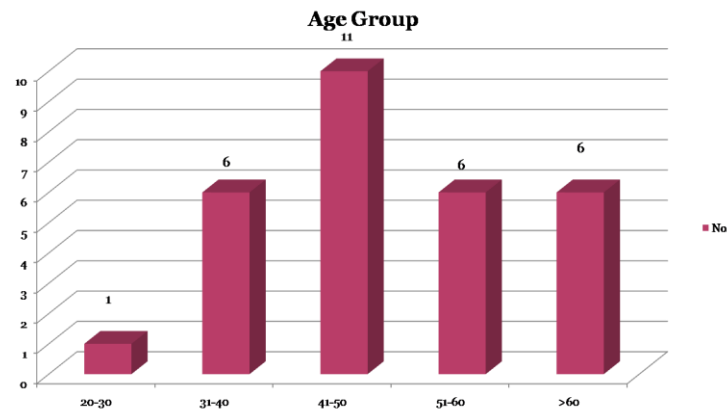


Table 3: Sex wise Distribution of Patients with Incisional Hernia

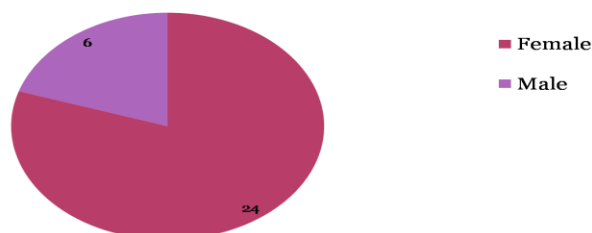


Table 4: Type of Incision causing hernia

Location of Hernia	No. of Cases
Midline lower abdomen	16
Epigastrium	4
Left hypochondrium	7
Right lumber region	2
Umbilical region	1

Post operative Course

- Follow up was short
- But during this period cosmetic results excellent
- Post operative pain nil to minimal
- No seroma formation
- No recurrences

Drains were used in all the patients. The period of drainage ranged in all cases on 3rd to 4th post operative day. Follow up was carried out for minimum 6 months. No recurrence was encountered in the followup group.

IV. Discussion

In present study, age ranged from 26 years to 70 years and with peak incidence in 31 to 50 age group. As per the Maingot’s studies, mean age was around 45 years¹⁰. There is a female preponderance noticed with 81.1%. In Bhutia et al study, the female : male ratio was 3:1.5 with female preponderance 84%¹¹, in this study all patients are presented with history of swelling, associated pain was present in 36 cases. Most of cases in our series, it was reducible hernia (92.5%) and with 7.5% of cases had irreducible hernia. We had approximately 33.9% of cases with early onset of incisional hernia (within one year of previous surgery) whereas 66.1% of cases had onset of incisional hernia in second year. Majority of incisional hernias (80%) developed in the first two years as per international studies¹². In this study, 77.3% of cases developed incisional hernia through lower midline incision, 9.4% through Pfannensteil incision, 7.6% through upper midline incision, 5.7% through paramedian incision.

Seroma formation is comparable with Manohar et al study but significantly more compared to Leber et al study¹⁰. In our study, the most of the hospital stay spent in preoperative workup and in the treatment of associated medical illness, if any, to reach the normal parameters for safe surgery. Total duration of hospital stay is increased when risk factors are present and duration of hospital stay after surgery also increased when the risk factors are present.

In present study, we had followed up all the patients after discharge for 15 days, 1month, 3 months and few cases upto 6months of duration.

There was no recurrence of incisional hernia noticed in the present study. de Vries Relingh TS et al reported a recurrence rate of incisional hernia following different techniques of mesh repair as follows: In onlay technique it was 28.3%, inlay technique 44%, and underlay technique 12%¹⁹. Leber et al reported a recurrence rate of 17%, Antonie Hamy et al 3.1% of cases¹². There was no recurrence in Hameed et al and Manohar et al study.

The main advantage of pre peritoneal mesh repair are - Less chance of mesh infection and erosion through skin because the graft lies in preperitoneal plane between posterior rectus sheath and peritoneum, avoids adhesions, bowel obstruction, enterocutaneous fistula and erosion of mesh, minimal morbidity and duration of hospital stay is less compared to other techniques. The main disadvantage is moretime consuming, extensive preparation of preperitoneal plane and surgical experience. The preperitoneal (sublay) mesh hernia repair was first described by Renestopa, Jean Rives, and George Wantz . This technique is considered by many surgeons to be the gold standard for the open repair of abdominal incisional hernia^{6,7,8,9}.

Major problems that occur during octomesh incisional hernia is

- Recurrence
- Chronic post operative pain
- Seroma formation
- Infection
- Badly scarred abdomen

The main solutions adopted for these complications are –

- Recurrence - Large mesh with large underlay
- Chronic post operative pain – Minimal or no fixation
- Seroma formation – Minimal dissection

- Infection - Minimal dissection
- Badly scarred abdomen – Excision of scar

V. Conclusion

Technical advantages of using octomesh is that it requires

- Minimal sub cutaneous dissection
- Large mesh can be used easily
- Easy to learn
- No fixation sutures
- Can be spread easily and uniformly
- Smaller incision

Therefore, less number of postoperative complications noticed in present study. No recurrence noticed in this study. In the present study, preperitoneal octomesh repair had excellent long-term results with minimal morbidity.

References

- [1]. Da-silva al; Patroiaanu. A. Incisional hernias;factor influencing development. South Med. J. 1991; 84 : 1500-155.
- [2]. Cassar K, Munro A. Surgical treatment of incisional hernia. B J Surg 2002; 89:534-545.
- [3]. George CD, Ellis H. The results of Incisional hernia repair. A twelve year review. Ann R Coll Surg Engl 1986; 68: 185-7.
- [4]. Bauer JJ, Harris MT, Gorfine SR, Kreeel I. Rives stoppa repair of giant incisional hernias. Experience with 57 patients. Hernia 2002; 6: 120-3.
- [5]. Ahmed; D. Mahmood; J.Khan. Use of Mesh in the management of recurrent incisional hernias.Pak. J. Surg. 1995: 11: 101-2.
- [6]. Berry MF, Paisley S, Low DW et al. Repair of large complex recurrent incisional hernias with retromuscular mesh and panniculectomy Am J Ssurg 2007;194: 199-204.
- [7]. Iqbal CW, Pham TH, Joseph A et al. Long term outcome of 254 complex incisional hernia repairs using modified Rives-Stoppa technique World J Surg 2007; 31: 2398-2404.
- [8]. Martin- Duce A, Nogueras F, Villet AR et al.Modifications to Rives technique for midline incisional hernia repair. Hernia 2001; 5: 70-72.
- [9]. Langer C, Schaper A, Liersch T et al. Prognosis factors in incisional hernia surgery:25 years of experience. Hernia 2005; 9: 16-21.
- [10]. Michael Zinner, Seymour I. Schwartz,Harold Ellis. Maingot's: Abdominal operations. 10th ed, Vol. 1, 423-425 and 548-572.
- [11]. Bhatia WT, Chandra SS, Srinivasan K, Ananthakrishna N. Factors predisposing to incisional hernia after laparotomy and influencing recurrences rate after different methods of repair: A prospective study of 220 patients. IJS 1993; 55 (11): 535-543.
- [12]. Richard J, Sanders S, Didementi D. Principles of abdominal wall closure, prevention of wound dehiscence. Arch Surg. 1977; 112: 1188-91.
- [13]. Manohar C S, Ramdev K. Management of Incisional Hernia by Peritoneal Mesh Repair.International Journal Of Basic Medical Sciences;Volume 1 issue 3 June2010
- [14]. Ponka JL. Hernias of the abdominal wall. Philadelphia, W. B. Saunders, 1981
- [15]. Bucknell TE, Cox PJ. Burst abdomen and incisional hernia: A prospective study of 1129 major laparotomy. Br Med J 1982; 284: 931.
- [16]. Antoine Hamy, Patrick Pessaux, Tephania S, Serge Radriamananjo et al. Surgical treatment of large incisional hernia by an intraperitoneal Dacron mesh and an aponeurotic graft. J Am Coll Surg 2003 Apr; 196 (4): 531-534.
- [17]. Fakhar Hameed , Bashir Ahmed, Asrar Ahmed, Riaz Hussain Dab, Dilawaiz. Incisional Hernia Repair by Preperitoneal (Sublay) Mesh Implantation. A.P.M.C Vol: 3 No.1 January-June 2009
- [18]. Leber Geoffrey E, Garb Jane L, Alexander Albert I, Reed WP. Long-term complications associated with prosthetic repair of incisional hernia. Arch Surg 1998 Apr; 133 (4): 378-382.
- [19]. deVries Reilingh TS, Van Geldere D, Langenhurst B, Dejong D, van der wilt GJ, van GH. Repair of large midline incisional hernias with polypropylene mesh: Comparison of three operative techniques. Hernia 2004 Feb; 8 (1): 56- 59.