

## Non-Functioning Pituitary Adenomas

Aem Haddam, Ns Fedala\*, D Belarbi\*, L Ahmed Ali\*

Department Of Endocrinology Bab El Oued Hospital, Algiers, Algeria

\* Department Of Diabetology Bab El Oued Hospital, Algiers, Algeria

---

**Summary:** Non functioning pituitary adenomas (NFPA) are glandular tumors of the pituitary gland that do not manifest in any clinical aspect related to hypersecretion. They represent 28 to 33.2% of pituitary adenomas (PA). They are diagnosed at a later stage than functional adenomas, tumor size in these tumors is often more important which is responsible for visual impairment and anterior pituitary deficiency. We specify in this article the phenotypic and evolutionary characteristics of NFPA in women.

**Keywords:** Non functioning pituitary adenomas, immunohistochemistry, MRI, surgery, radiotherapy

---

### I. Introduction

Non functioning pituitary adenomas (NFPA) are glandular tumors of the pituitary gland that do not manifest in any clinical aspect related to hypersecretion (1). They represent 28 to 33.2% of pituitary adenomas (PA). They are diagnosed at a later stage than functional adenomas, tumor size in these tumors is often more important which is responsible for visual impairment and anterior pituitary deficiency (2).

This is a descriptive retrospective study of the cases of patients with a NFPA hospitalized and followed in the department of endocrinology during the period 2000 to 2015. The aim of this study was to specify the phenotypic and evolutionary characteristics of non-functioning pituitary adenomas in women.

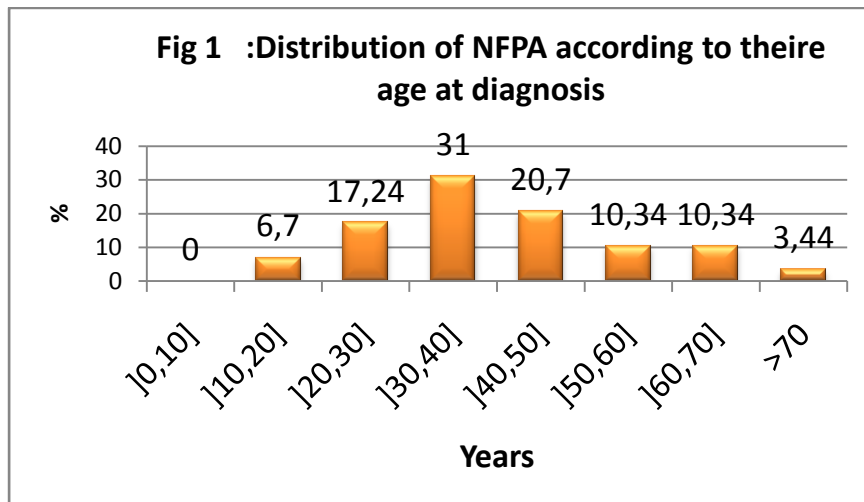
### II. Materials, methodology

This is a descriptive retrospective study of the cases of patients with a NFPA hospitalized and followed in the department of endocrinology during the period 2000 to 2015. For each patient were collected; The clinical and paraclinical parameters established during the initial management and during post-therapeutic re-evaluations. In this study, we precised the existence of a personal and familial history (multiple endocrine neoplasia, pituitary adenoma ...); the reason for consultation, the first symptom appeared in the disease, the age at diagnosis, the period between the first symptomatology ;the Diagnosis and the clinical aspect; (Headache, visual impairment, diplopia); Vomiting, epilepsy, frontal syndrome, Signs of apoplexy (sudden visual impairment, meningeal irritation syndrome), menstrual disorders (spaniomenorrhea, primary or secondary amenorrhea), the presence of spontaneous and/or induced galactorrhea, signs of corticotroph deficiency (asthenia, hypotension, mucocutaneous depigmentation) thyrotropic deficiency (bradycardia, constipation, dryness and intolerance to cold) or posterior pituitary leading to diabetes insipidus. Hormonal assessment (gonadotropic axis: FSH, LH, estradiol), lactotropic axis: prolactin level, Corticotroph axis (ACTH at 8 am, cortisol at 8am, overnight dexamethasone suppression test, insulin-induced hypoglycemia test to estimate corticotropic reserves), Thyrotropic axis (TSH, FT4), somatotropic axis (GH, IGF1, insulin-induced hypoglycemia test to estimate somatotrophic reserves). Neuroradiologic assessment (MRI of the pituitary gland, To assess the characteristics of the adenoma). Ophthalmological assessment (visual acuity, Fundus, visual field) and immunohistochemistry.

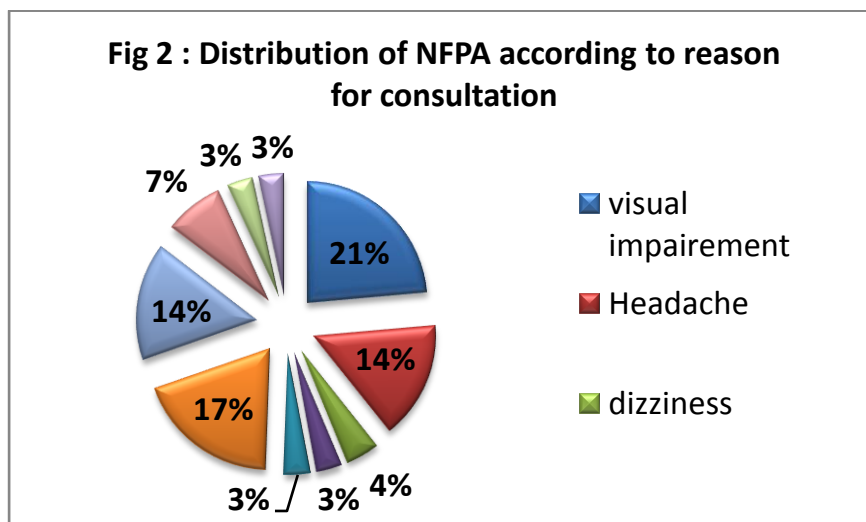
### III. Results

\* 120 NFPA were recorded in 632 pituitary adenomas, representing (19%) of all PA. They represented the fourth cause after prolactinomas (42%), GH secreting adenomas (28%) and gonadotropin secreting adenomas (11%).

We reported that 24.1% (n: 29) of the patients were females with a male to female ratio of 3:1. The most affected age group was between 30-40 years with an average age at diagnosis of 41 years and 7 months (15-76 years) (Fig1)



The most frequent reasons for consultation were visual impairment 21% (decreased visual acuity in all cases) and menstrual cycle disorders (20.6%). Galactorrhea represented the third reason for consultation (Fig. 2) with an average delay at diagnosis of 4 years and 3 months (3 months - 10 years). 7% of the patients had no symptoms, and were incidentally discovered (pituitary incidentalomas).



On the Clinical aspect, nearly 2/3 of patients had signs advocating cranial tumor (vomiting, headache, visual impairment) and endocrine deficiency signs (Table I).

The gonadotroph and somatotroph axis were the most affected. Hyperprolactinemia was observed in 2/3 of the cases. (Table II and III). In all cases, hyperprolactinemia was less than 150 ng/ml.

**Table I : Neuroendocrine aspect**

Symptomatology	Number	%
Headach and neurological signs	20	41,6
Visual impairment	15	31,2
APD*	20	69
PPD**	1	2,08

\*APD : anterior pituitary deficiency

\*\* PPD : posterior pituitary deficiency

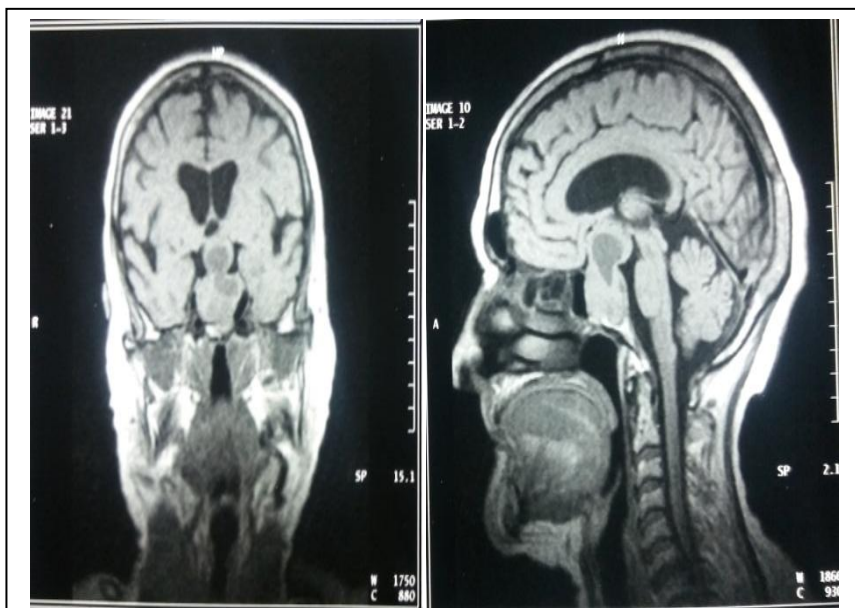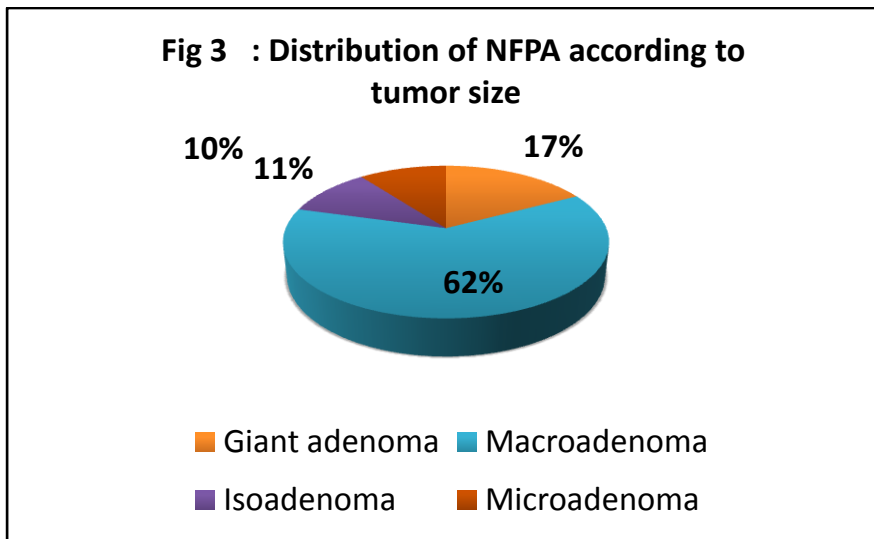
**Table II:** Distribution of patients according to endocrine evaluation

Hormonal axis	Number	%
Gonadotrph	19	65,5
Corticotroph	15	51,7
Thyreotropic	11	37,9
Lactotroph (Hyperprolactinamie)	17	58,6
Somatotroph	20	69

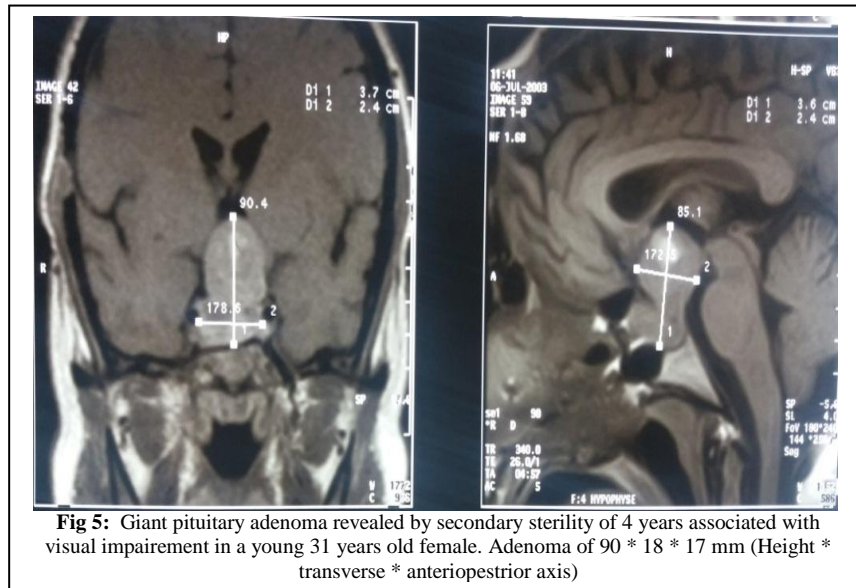
**Tablea III:** Distribution of patients according to the number of affected axis

Hormonal axis	Number	%
One axis affected	10	34,5
Two axis affected	4	13,8
All axis affected	6	20,7

On the radiological aspect, slightly more than 2/3 of the patients had a pituitary macroadenoma (62.06%). It was invasive in 65.5% of cases and giant with multidirectional extension in 17% of cases.



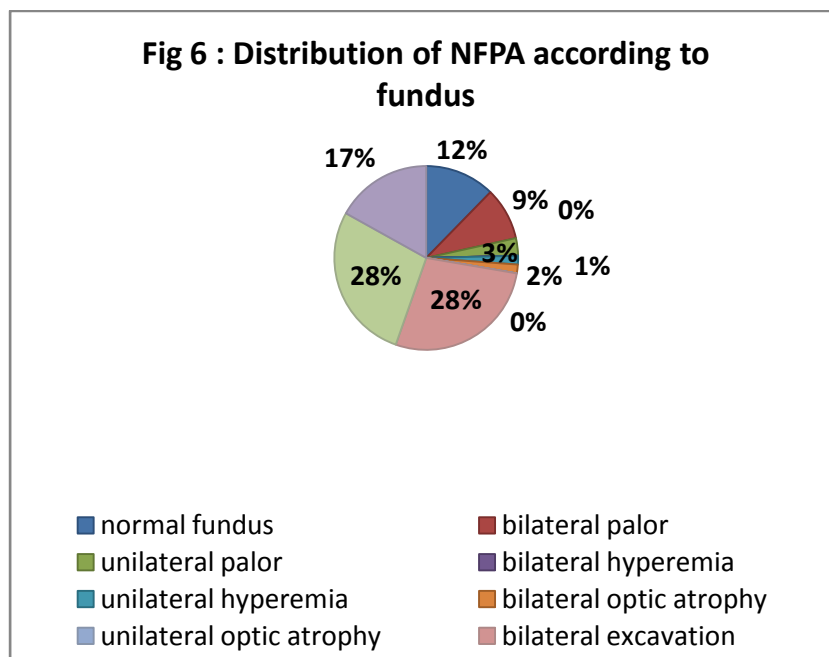
**Fig 4:** Giant PA measuring 45mm height partially necrosed with suprasellar extension compressing optical chiasma; infra-sellar extension filling the sphenoidal sinus, anterior extension to the frontal lobe.



Ophthalmologic exploration found visual impairment in 2/3 of the cases with decrease in visual acuity (60%) unilateral or bilateral blindness (33%), visual field (VF) disorders (34.9%) (Table IV) And fundus abnormalities (52.9%).(Fig 6)

**Table IV:** Distribution of patients according to their visual field affection :

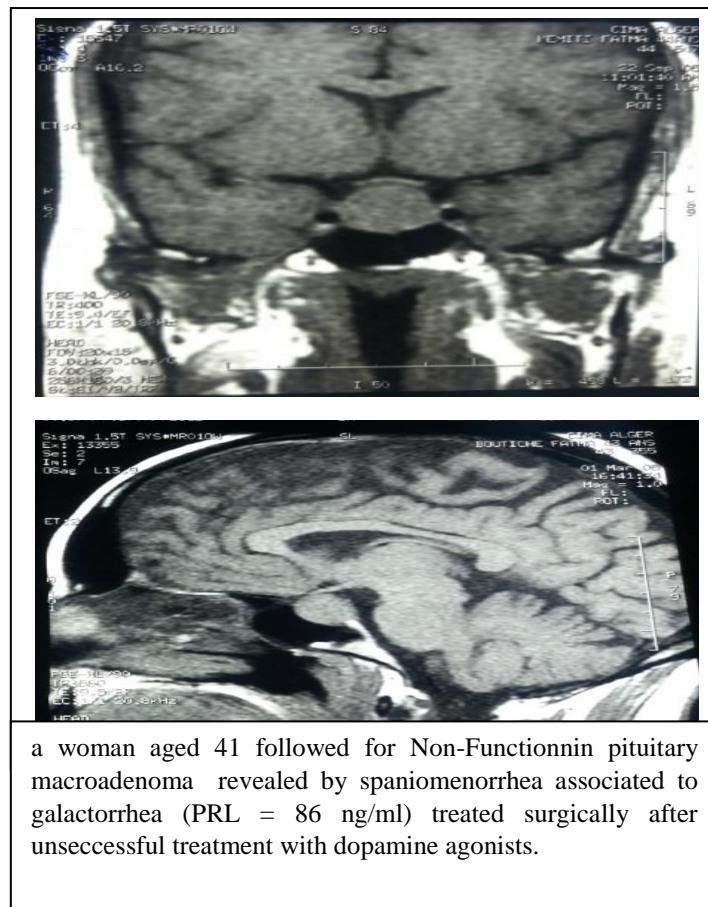
VF	Number	%
<b>Bilaterally normal VF</b>	<b>19</b>	<b>65,5</b>
<b>Bilateral quadranopsia</b>	<b>0</b>	<b>0</b>
<b>Unilateral temporal quadranopsia</b>	<b>1</b>	<b>3,4</b>
<b>Bilateral temporal hemianopsia</b>	<b>6</b>	<b>20,7</b>
<b>Unilateral temporal hemianopsia</b>	<b>2</b>	<b>6,9</b>
<b>Bilateral scotoma</b>	<b>1</b>	<b>3,4</b>
<b>Unilateral scotoma</b>	<b>0</b>	<b>0</b>
<b>Totale</b>	<b>29</b>	<b>100</b>



Therapeutically, all patients were referred for first-line surgery. It was performed trans-sphenoidally and lead to complete excision only in 7 cases of all NFPA (24.1%) (mean adenoma size :  $13 \pm 0.15$  mm). The Mean tumor reduction in other cases is 43% (mean size of adenomas:  $55.5$  mm  $\pm$  0.2). The immunohistochemical study of the tumor pieces concluded that they are non-secreting adenomas in all cases.

During postoperative evolution we noticed the appearance of a new endocrine deficiency in 18.18% of the cases and the recovery of the gonadocorticotroph axis in one patient. An improvement in ophthalmologic disorders was observed in 27.3% of cases.

Surgical treatment was followed by radiotherapy in 18 patients with large pituitary tumor remnant (mean size  $16$  mm  $\pm$  0.5). The evolution was marked nevertheless by a tumoral evolution in 3 cases requiring usage of treatment with TEMOZOLAMIDE. The neuroradiological reevaluation showed a stabilization of the tumoral lesion. The therapeutic association with somatostatin analogs and dopamine prior to the indication of radiotherapy did not have a tumoricidal effect.



\*From 11 patients operated with small postoperative tumor remnants, 09 remained stable after an average follow-up of 4 years. In 04 patients surgery was repeated because of a tumor reascension 3 years after. Partial excision was performed with an average tumor reduction of (26.18)%. A complement of radiotherapy was performed in them to limit tumor evolution.

#### IV. Discussion

NFPA represent clinically 15 to 30% of pituitary adenomas. They are situated after prolactinomas and somatotroph adenomas, at the same level or just after corticotroph adenomas.

They are more frequent in men than in women and are most often diagnosed during the 4th or 5th decade [2]. However, it must be pointed out that in women the peak of incidence occurs earlier between 20 and 45 years because of the greater frequency of disconnection hyperprolactinemia which results in an obvious clinical aspect that are menstrual cycle disorders which motivate Women to consult early conversely to man [3] NFPA might be diagnosed with a slow and progressive cranial tumor syndrome present in 50 to 80% of patients having headache and visual impairment with decrease in uni- or bilateral progressive decrease in

visual acuity which can progress to Blindness. The most classic pathognomonic sign is bitemporal hemianopsia caused by compression of the optical chiasma. Sometimes retro chiasmatic localization may lead to delayed diagnosis. Oculomotricity affection is rare. More rarely, the installation of the tumor syndrome can be acute during a pituitary apoplexy (15 to 25%) with sudden headaches, pseudo-meningeal irritation syndrome, oculomotricity and visual field disorders. NFPA are frequently manifested by an anterior pituitary insufficiency syndrome (4).

In women with genital activity, anterior pituitary insufficiency may manifest by menstrual cycle disorders such as spaniomenorrhea or secondary amenorrhea. In these cases the diagnosis is easy and it is made quickly.

The problem arises in women of pre-menopausal or post-menopausal age: the absence of hot flushes, although not specific, should suggest an eventual gonadotroph deficit; The absence of elevated plasma gonadotropins indicates a gonadotroph deficit advocating for a pituitary disease. More rarely, hypersecretion syndrome can be observed. Almost always it is a disconnection hyperprolactinemia and rarely a gonadotroph hypersecretion (4). Disconnection hyperprolactinemia occurs clinically, especially in women, by galactorrhea. It is sometimes spontaneous but in the majority of cases only induced (in 80% of cases). Hypersecretion of gonadotropins is rarely symptomatic. It causes hot flushes and ovarian hyperstimulation with endometrial hyperplasia, polycystic ovaries and hyperoestradiolemia apart from any hormonal treatment. However, it should be pointed out that NFPA can be fortuitously discovered because of the easy access to modern pituitary imaging (5) (6). Radiological assessment reveals a mass syndrome in the sellar region, sometimes compressive and invasive. It represents a decision-making element for the surgical approach which is rhinoseptale most often (7).

Indeed, the treatment of gonadotroph and non-functional adenomas relies on surgery, radiotherapy and or medical treatment. Surgical excision, usually by the rhinoseptal route, allows pathological diagnosis. According to the neurosurgeon's experience, an improvement (60-85%) or a normalization (30-50%) of the visual field and a recovery of the anterior pituitary functions (in 15 to 60%) of the patients can be both observed. However, excision is rarely complete in patients with a compressive or invasive macroadenoma, and there is a risk of post-surgical recurrence in 10 to 65% of patients within 5 to 10 years. In consequence it is important to emphasise on the need for hormonal and MRI assessment 3 to 6 months after surgery and on long-term follow-up (8).

Radiotherapy is indicated almostalways postoperatively either systematically particularly in front of a significant tumor remnant or during postoperative monitoring when assessing an increase in the volume of the tumor remnant.

Conventional radiotherapy reduces the risk of postoperative recurrence (an average of 32% after surgery and 11% after surgery and radiotherapy) but exposes the patient to immediate complications (nausea, asthenia) or long-term complications (anterior pituitary insufficiency in 50% of cases at 10-year-of disease evolution, neurological complications) with decrease in life expectancy (cerebrovascular risk). Despite adequate hormone replacement conventional or focused radiotherapy requires annual follow-up in particular of anterior pituitary functions and adenomatous volume (9) (10) (11).

The immunohistochemical study of the tumor piece is important to realise because it makes it possible to specify whether it is non-functional adenomas or non-excretory secreting adenomas. In reality, it would be more exact to speak of clinically non-functional adenomas, since immunocytochemistry, in vitro cultures and in situ hybridization of these tumors generally reveal abnormalities of FSH or LH or TSH or units secretion, or without humoral translation (12) (13) (14).

If excision is incomplete, medical treatment with combination of dopamin agonist and somatostatin analog should be discussed priorly to the indication of postoperative radiotherapy. In fact, the presence of dopamin receptors on adenomatous cells has been observed. Bromocriptine decreases in vivo and in vitro subunit concentrations of gonadotropins, while cabergoline (Dostinex®) has a greater anti-tumor effect, would prevent post-surgical tumor recurrences, an effect correlated with the expression of the short isoform of D2 receptor (15).

It was demonstrated that there ewiste subtypes of somatostatin receptors on adenomatous cells. Octreotide (Sandostatine®) decreases gonadotropin and  $\alpha$  subunit secretions and has an antiproliferative effect in vitro on adenomatous cells in cultures. As well as an antitumor effect of somatostatin analogs has been reported in 10-15% of patients, headache and visual field disturbances improvement without significant adenomatous volume variability was also observed during treatment with somatostatin analogs (16).

Finally, simultaneous treatment by somatostatin analogs and dopamin agonists may be considered []: an average 30% decrease in adenomatous volume was observed in 60% of patients when simultaneously prescribing octreotide (200  $\mu\text{g} \times 3$  / Day) and cabergoline (0.5 mg / week) (17) (18). However, GnRH agonists are most often ineffective and sometimes dangerous, whereas GnRH antagonists reduce gonadotropin concentrations without significant anti-tumor effects (19). Among the currently available chemotherapies, temozolomide is an important actor. This alkylating agent, conventionally used for glioblastomas, allows a

response in 40 to 50% of aggressive pituitary tumors. However the maintenance of tumor control over long term is rare. The best therapeutic approach for these pituitary tumors remains to be defined (20).

## V. Conclusion

The clinical aspect of non-secreting pituitary adenomas is exceptional. A finer analysis to look for signs at the beginning is important: headache, decreased visual acuity, unfortunately observed posteriorly. An imaging must be requested quickly. Anterior pituitary insufficiency predominates on the gonadotroph function. Hyperprolactinemia, generally less than 150 ng/mL, should prompt for further investigation and for the search of these adenomas. NFPA are most often diagnosed with a tumor syndrome. Their management, except contraindications or particular situations, is most often surgical, after an endocrine evaluation and after a deep neuroradiological and ophthalmological assessment. The excision, most often by trans-sphenoidal route, should be as much as possible done by an experienced neurosurgeon: the best guarantee of the most complete possible excision with as few complications as possible. A follow up is necessary in order to decide on a complementary treatment (usually a radiotherapy) as soon as a remnant or a recurrence is observed.

## Bibliography

- [1]. G. Raverot and al, adénome hypophysaire gonadotrope, EMC Endocrinologie nutrition 2014 ;vol 11 n3
- [2]. E. Fontana and al, épidémiologie des adénomes hypophysaires, revue médicale suisse ; 2009, vol n223
- [3]. Molitch M.E. Non functioning pituitary tumors and pituitary incidentalomas *Endocrinol Metab Clin N Am* 2008 ; 37 : 151-171
- [4]. G. Raverot and al, adénome hypophysaire gonadotrope, EMC endocrinologie Nutrition, juillet 2014, vol n3 ; 1-8
- [5]. G.Assic and al, exploration et prise en charge des adénomes hypophysaires non fonctionnels : exploration biologique et radiologique, consensus de la société française d'endocrinologie ; juillet 2015 ; vol 77 : 14-20
- [6]. Chanson P., Brochier S. Non-functioning pituitary adenomas *J Endocrinol Invest* 2005 ; 28 (suppl. 11) : 93-99
- [7]. L. Abouaf and al, exploration neuro ophtalmologique des adénomes hypophysaires non fonctionnels, consensus de la société française d'endocrinologie, juillet 2015, vol77 :23-28
- [8]. G.Assic and al, exploration et prise en charge des adénomes hypophysaires non fonctionnels : exploration biologique et radiologique, consensus de la société française d'endocrinologie ; juillet 2015 ; vol 77 : 14-20
- [9]. Molitch M.E. Non functioning pituitary tumors and pituitary incidentalomas *Endocrinol Metab Clin N Am* 2008 ; 37 : 151-171
- [10]. Constine LS, Woolf PD, Cann D, Mick G, McCormick K, Raubertas RF, Rubin P. Hypothalamic-pituitary dysfunction after radiation for brain tumors. *N Engl J Med* 1993 Apr 22;328(16):1208.
- [11]. Wassim Chemaitilly and Charles A Sklar1. Endocrine complications in long-term survivors of childhood cancers. *Endocr Relat Cancer* 2010; 17: R141.
- [12]. Hanson PI, Aylwin SJ, Monson Jp, Burrin Jm. Fsh secretion predominates in vivo and in vitro in patients with non-functioning pituitary adenomas *Eur J Endocrinol.* 2005;152:363-370
- [13]. CHANSON P, BROCHIER S. Non-functioning pituitary adenoma. *J Endocrinol Invest* 2005;28:93-99
- [14]. SNYDER P.J. Gonadotroph adenomas Melmed S., ed. *The pituitary.*1995;vol.1Cambridge Blackwell-Science:559-575
- [15]. Pivonello R., Martone C., Filippella M., Cavallo L.M., Somma C., Cappabianca P., and al. Dopamine receptor expression and function in clinically nonfunctioning pituitary tumors: comparison with the effectiveness of cabergoline treatment *J Clin Endocrinol Metab* 2004 ; 89 : 1674-1683 [cross-ref]
- [16]. Colao A., Filippella M., Di Somma C., Manzi S., Rota F., Pivonello R., and al. Somatostatin analogs in treatment of non-growth hormone-secreting pituitary adenomas *Endocrine* 2003 ; 20 : 279-283 [cross-ref]
- [17]. The French Multicenter Octreotide Study GroupWarnet A., Harris A.G., Renard E., Martin D., James-Deidier A., Chaumet-Riffaud P. A prospective multicenter trial of octreotide in 24 patients with visual defects caused by nonfunctioning and gonadotropin-secreting pituitary adenomas *Neurosurgery* 1997 ; 41 : 786-797 [cross-ref]
- [18]. Colao A., Filippella M., Pivonello R., Di Somma C., Faggiano A., Lombardi G. Combined therapy of somatostatin analogues and dopamine agonists in the treatment of pituitary tumours *Eur J Endocrinol* 2007 ; 156 : S57-S63
- [19]. Andersen M., Bjerre P., Schroder H.D., Edal A., Hoiland-Carlson P.E., Pedersen P.H., and al. *In vivo* secretory potential and the effects of combination therapy with octreotide and cabergoline in patients with clinically non-functioning pituitary adenomas *Clin Endocrinol* 2001 ; 54 : 23-30
- [20]. Lasolle H., Castinetti F., Cortet C., Cloix L., Batisse-Lignier M., Bonnet F., Bourcigaux N., Traitement par témozolomide des tumeurs hypophysaires agressives et carcinomes hypophysaires : résultats à court et long terme à partir d'une cohorte française de 31 patients *Annales d'Endocrinologie* ,October2016) Volume 77, Issue 5, Pages 557-624