

Anatomical Variations of Inferior Phrenic Artery in Indian Population

Dr.J.Karpagajothi¹, Dr.S.Bharathi Rani², Dr.N.S.Sunitha³

(Assistant Professors , Institute Of Anatomy , Madurai Medical College , The Tamilnadu Dr .M.G.R Medical University, Tamilnadu , India).

Abstract:

Background and aim: The inferior phrenic arteries (IPA) are the first branch of abdominal aorta and are the most frequent extrahepatic arterial supply to liver tumours especially hepatocellular carcinoma. As trans arterial chemo embolization (TACE) is one of the treatment options for these tumours , the descriptions about these arteries, their origin and the course will help interventional radiologist in achieving complete embolization of these tumours. The present study was undertaken to analyse the variations of IPA origin and to evaluate their branching pattern

Materials and Methods: This study was done in 34 consecutive human cadaveric specimens, irrespective of age and sex , allotted for dissection in our institute.

Results: Out of the 34 consecutive cadavers, both right inferior phrenic artery (RIPA) and left inferior phrenic artery (LIPA) have predominant separate origin from abdominal aorta RIPA - 23/34 (67.6%), LIPA - 19/34 (55.9%). However, RIPA originated from coeliac trunk in 10/34 (29.4%) and from right renal artery in one of them (2.9%). LIPA originated from coeliac trunk in 15/34 (44.1%). None of the cadavers had a common stump origin for both arteries.

Conclusion: Accurate knowledge about normal and variant origins of inferior phrenic artery is essential for interventional radiologists and surgeons.

Keywords: Inferior phrenic arteries, variant anatomy, hepatocellular carcinoma.

I. Introduction

The inferior phrenic arteries (IPA) constitute a pair of important vessels, supplying multiple organs apart from the diaphragm including the adrenal glands, esophagus, stomach, liver, inferior vena cava, and retroperitoneum. The IPAs commonly arise from the abdominal aorta just above the celiac trunk or from the celiac trunk. They arise either separately or as a common trunk from the same sources. The inferior phrenic artery can also arise from the renal, left gastric, superior mesenteric or rarely from hepatic artery [1] . Hepatocellular carcinoma (HCC)and few other vascular tumours of the liver, especially the large one near the dome of diaphragm (segment VI,VII,VIII, IV and II) can receive additional blood supply from the phrenic arteries apart from the dominant hepatic arteries. Trans arterial chemoembolization (TACE) and radioembolisation have emerged as a standard treatment option for these tumours both for downstaging and as palliation. As Inferior phrenic arterial blood supplies HCC , especially those located near the dome of the diaphragm, [2] complete knowledge of their anatomy is vital in achieving complete response.

II. Materials And Methods

The study was carried out in 34 consecutive human cadaveric specimens allotted for dissection for under graduate medical students in our Institute of Anatomy during the period of 2010-2013. The dissection was performed according to the text book of Cunningham's manual of practical anatomy (16thed,2009) [3]. Abdominal cavity was opened by cutting and reflecting the anterior abdominal wall muscles. Abdominal viscera were mobilized to expose the origin of inferior phrenic artery . After resection of tissues adjacent to the crura of diaphragm, the origin of the RIPA and LIPA, its course and their branches were documented.

III. Results

Out of 34 specimens studied, both right inferior phrenic artery (RIPA) and left inferior phrenic artery (LIPA) have predominant origin from the abdominal aorta(AA). 67.6% of RIPA have their origin from AA, whereas only 55.9% of LIPA have their origin form AA. It is always a separate origin for both arteries rather than from a common trunk. Ten of them have both arteries originating separately from abdominal aorta .Two of them have both arteries originating seperately from coeliac trunk.

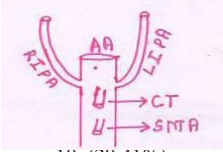
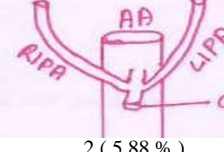
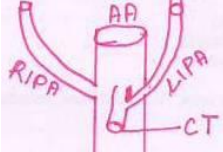

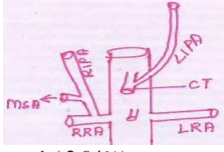

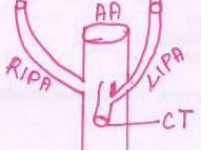
Extra abdominal aorta origin was found in 11 out of 34 RIPA, whereas it was found in 15 out of 34 LIPA . Regarding RIPA, 10 (29.4%) had originated from coeliac trunk and remaining one from right renal

artery (2.94%). Regarding LIPA, all the 15 (44.11%) have their origin from the coeliac trunk. The results have been tabulated below in Table 1 and 2.

Table : 1 Common Source Of Origin

S.No	Source	Ripa	Lipa
1	Abdominal Aorta	67.6%	55.9%
2	Coeliac Trunk	29.4%	44.1%
3	Right Renal Artery	2.9%	-
4	Total	100%	100%

Table : 2 Variant Source Of Origin

SOURCE	Abdominal Aorta	Coeliac Trunk	Right Renal Artery
Both RIPA&LIPA	 10 (29.41%)	 2 (5.88 %)	-
RIPA Alone	 6 (17.64%)	 4 (11.76%)	 1 (2.94%)
LIPA Alone	 4 (11.76%)	 7 (20.58%)	-
TOTAL	20 (58.82%)	13 (38.24%)	1

In 31 out of 34 cadavers the normal branching pattern of inferior phrenic artery was observed. In remaining three cadavers, following variations was noted. In one cadaver both middle supra renal and right inferior phrenic artery arose as a common trunk from right renal artery and the left inferior phrenic artery originated from coeliac trunk (Fig-1).

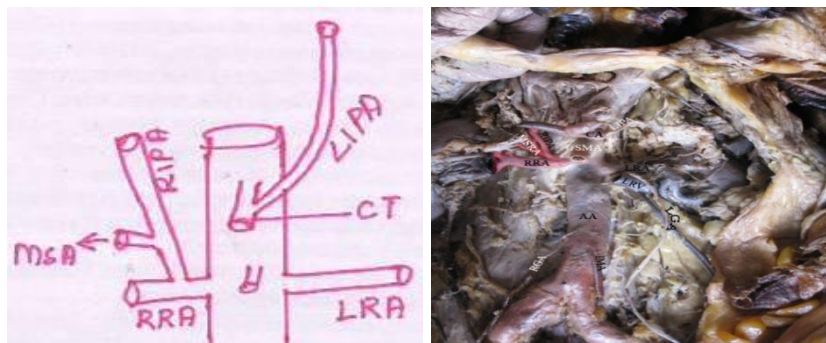


Fig 1

[AA- Abdominal Aorta, CT-Coeliac trunk,RIPA- Right inferior phrenic artery,LIPA- Left inferior phrenic artery,RRA- Right renal artery,LRA-Left renal artery,MSA-Middle suprarenal artery]

In one cadaver both middle supra renal and inferior phrenic arteries arose as a common trunk from aorta just above the renal artery. On the left side Inferior phrenic artery arose from aorta just above the left renal artery and here accessory renal artery was seen (Fig-2).

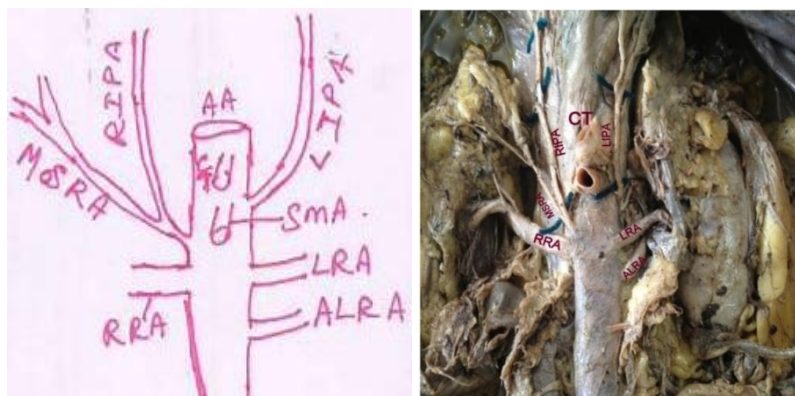

Fig 2

[AA- Abdominal Aorta, CT-Coeliac trunk,RIPA- Right inferior phrenic artery,LIPA- Left inferior phrenic artery,RRA- Right renal artery,LRA-Left renal artery,MSRA-Middle suprarenal artery,ALRA-Accessory renal artery]

In one cadaver on the left side both medial and lateral branches of inferior phrenic artery arose separately – medial branch from coeliac trunk and lateral branch from abdominal aorta but right side showed no such variation (Fig-3).

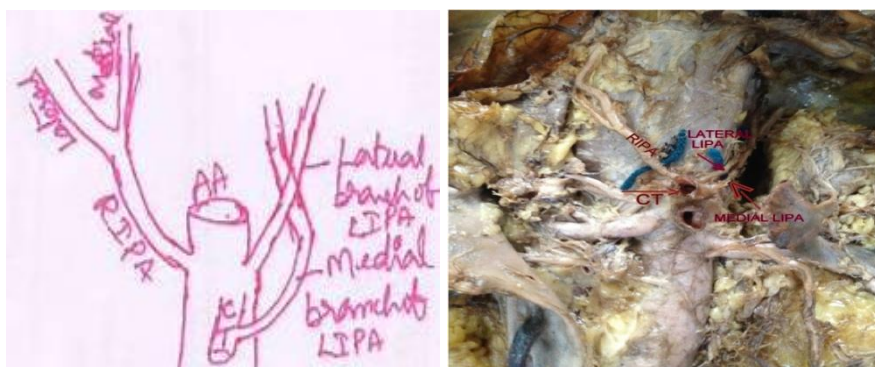

Fig 3

[AA- Abdominal Aorta, CT-Coeliac trunk,RIPA- Right inferior phrenic artery,LIPA- Left inferior phrenic artery]

IV. Discussion

The Inferior phrenic arteries commonly arise from abdominal aorta just above the coeliac trunk or from the coeliac trunk. They arise either separately or as a common trunk from the same sources. The inferior phrenic artery can also arise from the renal artery, left gastric, superior mesenteric artery or rarely from hepatic artery. After their origin both arteries ascend upwards and laterally anterior to crus of diaphragm near the medial border of suprarenal glands, the right passes posterior to IVC and left passes behind esophagus. Near the posterior border of the central tendon of the diaphragm, each divides into medial and lateral branches. These branches supply the wall of Inferior vena cava , serosal surface of abdominal esophagus. Each inferior phrenic artery has two or three small suprarenal branches. The capsule of the liver and spleen may also receive a small supply from the arteries

Various cadaveric studies reported such variations [4-7].In Adachi's study of 74 cadavers, the artery arose from the abdominal aorta and the coeliac trunk in 31 and 34 cadavers respectively [4]. Greig et al reported that out of 425 cadavers the right inferior phrenic artery arose from the aorta in 46.1% and from coeliac trunk in 41.4%.

Variant origins of right inferior phrenic artery were from the right renal artery, or an accessory renal artery, the hepatic artery or an accessory hepatic artery, and internal spermatic artery.

The left inferior phrenic artery arose from the coeliac trunk in 52.2% and from the aorta in 44%. Variant origin of left inferior phrenic artery were from left gastric artery, left renal artery and accessory left hepatic artery [5].

Loukas et al reported out of 300 cadavers, the right inferior phrenic artery arose from right renal in 17%, coeliac trunk in 40%, abdominal aorta in 38%, left gastric artery in 3% and hepatic artery proper in 2% .

The left inferior phrenic artery arose from left renal artery in 5% , the celiac trunk in 47% , aorta in 45% , left gastric artery in 2% and hepatic artery proper in 1% of specimens [6].

According to Pick and Anson , celiac artery and aortic sources were found to be the most common origin of inferior phrenic artery in 47.8% and 45.1% respectively .They reported that in 5.8% inferior phrenic artery arose from renal artery, 2.3% from left gastric artery, 0.3% from hepatic arteries [7].

Suman Tiwari et al reported that out of 50 specimens only in 5 specimens coeliac trunk gave origin to inferior phrenic artery [8].

Patel et al studied that ,out of 39 cadavers the inferior phrenic arteries had their origin from coeliac trunk in 16 (41%) cadavers . Both RIPA and LIPA arising from the coeliac trunk were present in 2 (0.5%) cadavers. In rest of 23 (58.97%) cadavers RIPA and LIPA takes origin from abdominal aorta [9].

In our study out of 34 consecutive cadavers both RIPA and LIPA have predominant separate origin from abdominal aorta RIPA - 23/34 (67.6%) LIPA - 19/34 (55.9). However the RIPA originated from celiac trunk in 10/34 (29.4%) and from right renal artery in one of them (2.94%). The LIPA originated from coeliac trunk in 15/34 (44.1%). Aorta was the source in 58.82% , coeliac trunk in 38.24% and renal artery in 2.94%. The current study showed similar findings except that the frequency of the IPA originating from the coeliac trunk was lesser. The results of our study was reviewed with other studies in Table 3.

Table:3-Comparision Of Various Studies Of Origin Of Inferior Phrenic Arteries

Study	Abdominal Aorta	Coeliac Trunk
Adachi	41.89%	45.94%
Greig	46.1%	41.4%
Loukas M	38%	40%
Pick And Anson	45.1%	47.8%
Patel	58.7%	41%
Present Study	58.82%	38.23%

According to branches of IPA in their study, Miyayama et al. [10] stated that the medial and lateral branches of the LIPA frequently arise from separate origins. Kim et al. [11] reported a case in a series of 23 patients in which the medial branch arose from the left gastric artery and the lateral branch arose from the coeliac trunk. Ilke Ali Gurses et al [12] reported in one case (1/26,3.85%) the medial and lateral branches of LIPA originated from the coeliac trunk and the aorta, respectively. We observed same branching pattern of LIPA in one case (1/34,2.94%) [fig 3] which coincided with Ilke Ali Gurses et al.

Gown et al reported the significant relation of hepatocellular carcinoma and extra hepatic collateral supplies from the inferior phrenic artery in his study. Among 383 interventional procedures, 346 hepatocellular carcinomas were found in the bare area of liver had extra hepatic collateral supplies from the inferior phrenic artery. Among them in 3 cases of hepatocellular carcinoma the right inferior phrenic artery exclusively supplied it [2].

Recent advances in treatment of hepatocellular carcinoma involves transcatheter arterial chemoembolization which requires the detail anatomical knowledge of extra hepatic collateral supply to hepatocellular carcinoma . Complications are to be expected after embolization of the inferiorphrenic arteries, due to the introduction of chemical agents into target and non-target arteries. These include: abdominal or referred shoulderpain , pleural effusion, basal atelectasis, hiccups and diaphragm weakness [13-16]. Furthermore, gastritis, esophagitis and ulceration might develop if the gastric and esophageal branches of the LIPA are affected [17].

According to Felix variations regarding the lateral branches of the abdominal aorta can be explained with the ladder theory [18]. This theory states that the IPAs develop from the cranial group of the lateral mesonephric arteries and variations between other lateral branches such as the middle suprarenal, renal and gonadal arteries are possible.

V. Conclusion

Knowledge of variations of IPA can assist significantly in liver tumor treatment and any upper abdominal radiological interventions.

References

- [1]. Standring,S , Ellis H , Healy JC at el Vascular supply and lymphatic drainage. In Gray's anatomy. 40thedition Edinburg: Churchill livingstone, 2005;p.1072 -1074
- [2]. Gowan D KoGY,YoonHK Sung KB, Lee F RyuS, at el Inferior phrenic Artery Anatomy, Variaons, pathologic conditions and interventional management Radio graphics 2007; 27 (3) 687-705
- [3]. Romanes, G.J. Cunningham text book of Anatomy . (2009)16thedition p 1297-1302.
- [4]. Adachi B. Das arterien system der Japaner, Band 2. Kyoto :Keiserlich - Japanischen Universitat; 1928. pp. 14–16.
- [5]. Greig HW, Anson BJ, Coleman SS. The inferior phrenic artery: types of origin in 850 body-halves and

- [6]. diaphragmatic relationship. Q Bull Northwest Univ Med Sch. 1951;25:345–50. [PMC free article][PubMed]
- [7]. Loukas M, Hullett J, Wagner T. Clinical anatomy of the inferior phrenic artery. Clin Anat. 2005;18:357–65. [PubMed]
- [8]. Pick JW, Anson BJ. The inferior phrenic artery: origin and suprarenal branches. Anat Rec. 1940;78:413–27.
- [9]. Suman Tiwari , K. Jeyanthi Study of Origin of Inferior Phrenic Arteries from the Coeliac TrunkAnatomica Karnataka, Vol-6, (3), Page 38-41 (2012)
- [10]. Bharat G Patel*, Prakash Gosai , Ritesh K Shah , Sanjay D Kanani A cadaveric study of origin of inferior phrenic artery form celiac trunkGCSMC J Med SciVol (II) No (II)July-December 2013
- [11]. Miyayama S, Yamashiro M, Yoshie Y, Okuda M, Nakashima Y,Ikeno H, et al. Inferior phrenic arteries: angiographic anatomy , variations, and catheterization techniques for transcatheter arterial NLMNIH DHHS USA.chemoembolization. Jpn J Radiol. 2010;28:502–11. [PubMed]
- [12]. Kim HC, Chung JW, Kim WH, An S, Seong NJ, Jae HJ, et al. Chemoembolization of the left inferior phrenic artery in patients with hepatocellular carcinoma: 9-year single-center experience. AJR Am JRoentgenol. 2010;194:1124–30. [PubMed]
- [13]. İlke Ali Gürses, ÖzcanGayretli, Aysin Kale, Adnan Öztürk, Ahmet Usta, and Kayihan Şahinoğlu Inferior Phrenic Arteries and Their Branches, Their Anatomy and Possible Clinical Importance: An Experimental cadaver Study Balkan Med J. 2015 Apr; 32(2): 189 – 195. Published online 2015 Apr 1.
- [14]. Duprat G, Charnsangavej C, Wallace S, Carrasco CH. Inferiorphrenic artery embolization in the treatment of hepatic neoplasms.ActaRadiol. 1988;29:427–9.
- [15]. Chung JW, Park JH, Han JK, Choi BI, Kim TK, Han MC. Transcatheter oily chemoembolization of the inferior phrenic artery in hepatocellular carcinoma: the safety and potential therapeutic role. JVascIntervRadiol. 1998;9:495–500. [PubMed]
- [16]. Shin SW, Do YS, Choo SW, Lieu WC, Cho SK, Park KB, et al. Diaphragmatic weakness after Transcatheter arterial chemoembolization of inferior phrenic artery for treatment of hepatocellular carcinoma. Radiology. 2006;241:581–8. [PubMed]
- [17]. Lee DH, Chung JW, Kim HC, Jae HJ, Yoon CJ, Kang SG, et al. Development of diaphragmatic weakness after transcatheter arterial chemoembolization of the right inferior phrenic artery: frequency and determinant factors. J VascIntervRadiol. 2009;20:484–9. [PubMed]
- [18]. Chung JW, Park JH, Han JK, Choi BI, Han MC, Lee HS, et al .Hepatic tumors: predisposing factors for complications of transcatheter oily chemoembolization. Radiology. 1996;198:33–40.
- [19]. 18 In: Felix W, editor; Kiebel F, Mall FP,editors. Manual of human embryology. The mesonephric arteries Vol. 2. Philadelphia: J.B.Lippincott Company; 1912. pp. 820