

Rare Involvement of Extranodal Non-Hodgkin's Lymphomas, With Short Review of Literature

D. D.Kalyani¹, Dr. R. Rajyalakshmi², O. Shravan Kumar³,

¹ Assistant Professor, ² Assistant Professor, ³ Professor
Department Of Pathology, Gandhi Medical College, Secunderabad

Corresponding Author: Dr. D. Kalyani, Assistant Professor, Department Of Pathology, Gandhi Medical College, Secunderabad, India.

Abstract: Primary extranodal lymphomas are rare in sites like ovary, thyroid, nasopharynx and central nervous system (CNS). It is usually a well-known late manifestation of disseminated nodal disease. Five rare cases of extranodal lymphomas were reported at Department of Pathology, Gandhi Medical College and Hospital, Secunderabad. All five cases were diagnosed as Non Hodgkin's lymphoma (NHL) based on histopathological, radiological and immunohistochemistry findings. Primary extranodal lymphomas usually they present with features of carcinomas. But immunohistochemistry plays an important role in diagnosis and classification of extranodal lymphomas in these sites.

Keywords: Extranodal, non-Hodgkin's lymphoma, immunohistochemistry.

I. Introduction

Lymphomas involving extranodal sites most commonly occur simultaneously with nodal involvement. Primary extranodal lymphomas are commonly seen in gastrointestinal tract but they are rare in the sites like ovary, thyroid, nasopharynx, and central nervous system (CNS). Although 25–40% of Non Hodgkin's lymphoma (NHL) patients present with a primary extranodal lymphoma,^[1-3] but they are rarely reported in the literature.

II. Materials And Methods

A total number of eighteen cases of lymphomas were reported from April 2008- May 2009 in the Department of Pathology, Gandhi Medical College and Hospital, Secunderabad. Out of which five cases (27.7%) were extranodal lymphomas. In all these cases, the slides were stained with Hematoxylin and eosin and correlated with immunohistochemistry findings as well as radiological findings and were reviewed.

Five cases of extranodal lymphomas involving rare sites like ovary, thyroid, nasopharynx and CNS were reported as carcinomas in the department of Pathology, Gandhi Medical College, Secunderabad. They were presented clinically.

Case details are as follows. One case presented with left iliac fossa mass, one case with hypertension and paresis, two cases with space occupying lesions in cerebellum and one with right cervical lesion. In all the five cases there was no clinical suspicion of lymphoma [Table-1]. Out of five cases, cytology was done in only 3 cases which showed features of lymphoma. [Figures 1]. Gross features revealed grey white, fish flesh cut surface with diffuse involvement. [Figure 2]. CT findings of sinuses revealed hyper intense soft tissue masses in left maxillary, bilateral ethmoidal sinuses extending into the orbits. [Figure 3]. In all these cases, the slides were stained with Hematoxylin and Eosin and correlated with radiological findings. They were further classified based on immunohistochemistry findings.

III. Results

Out of five cases, cytology was done in 3 cases which showed features of lymphoma. On Histopathology all the five cases showed the features of NHL with diffuse infiltrate of monomorphous population of lymphoid cells with scant rim of cytoplasm and large vesicular nuclei infiltrating into the native tissue. Immunohistochemically in four cases tumor cells were positive for B cell markers and T cell markers in one. [Figures 8,9,10]. However all the cases showed positivity for Leucocyte common antigen (LCA) [Table 2].

On Histopathology [Table 2] all the five cases showed the features of NHL with diffuse infiltrate of monomorphous population of lymphoid cells with scant rim of cytoplasm and large vesicular nuclei infiltrating into the native tissue [Figures 4-7]. Immunohistochemically in four cases tumor cells were positive for B cell markers and T cell markers in one [Figures 8, 9]. However all the cases showed positivity for Leucocyte common antigen (LCA) [Figure10].

Table 1: Clinical summary

SL. No.	Age/sex	Site	Clinical presentation	Radiology findings	Clinical diagnosis
Case 1	66/F	Left ovary	12x10cm left iliac fossa mass, tender, firm	12x10cm, mixed echoic mass s/o ovarian cancer on ultrasound	Carcinoma ovary
Case 2	38/M	Maxillary antrum, Spinal cord	Acute retention of urine, perianal pain, left eye proptosis, infraorbital swelling, wasting of left tibialis, gastrocnemius, absence of left knee and ankle jerks and peripheral sensory loss	hyperintense soft tissue masses in sacral spinal canal in the sagittal plane, presacral space, left maxillary, bilateral ethmoidal sinuses and both orbits on MRI	Secondaries
Case 3	68/F	Thyroid	4x3cm, hard right upper cervical swelling, restricted mobility	Multiple hypoechoic lesions of varying sizes in thyroid on ultrasound	Multinodular goitre
Case 4	45/M	Right cerebellum	Paresis, fever and loss of weight. No history s/o immunosuppression	Space occupying lesion in right cerebellum on CTscan	High grade Glioma
Case 5	35/F	Left cerebellum	Parasthesias, headache. No history s/o immunosuppression	Space occupying lesion in left cerebellum on CTscan	Glioma

Table 2: Cytological, histopathological and immunohistochemical findings

SL. No.	Cytology	Histopathology	Immunohistochemistry	Final Diagnosis
Case1	Not done	Diffuse Large cell lymphoma	CD20 (diffuse cytoplasmic) LCA (diffuse cytoplasmic and membrane)	Diffuse large B cell lymphoma, Left ovary
Case2	Not done	NHL	CD20 (diffuse cytoplasmic) LCA (diffuse cytoplasmic and membrane) CD3 negative	NHL, B cell type, Nasopharynx, with metastases in brain and spinal cord presenting as cauda equine syndrome
Case3	NHL	Diffuse Large cell lymphoma	CD-20(diffuse cytoplasmic) LCA (diffuse cytoplasmic and membrane)	Diffuse large B cell lymphoma, Thyroid
Case4	Round cell tumor	NHL	CD3 (diffuse cytoplasmic) LCA(diffuse cytoplasmic and membrane) CD 20 negative	Diffuse T cell NHL, Right cerebellum
Case5	Round cell tumor	NHL	CD20 (diffuse cytoplasmic) LCA(diffuse cytoplasmic and membrane)	Diffuse large B cell lymphoma, Left cerebellum

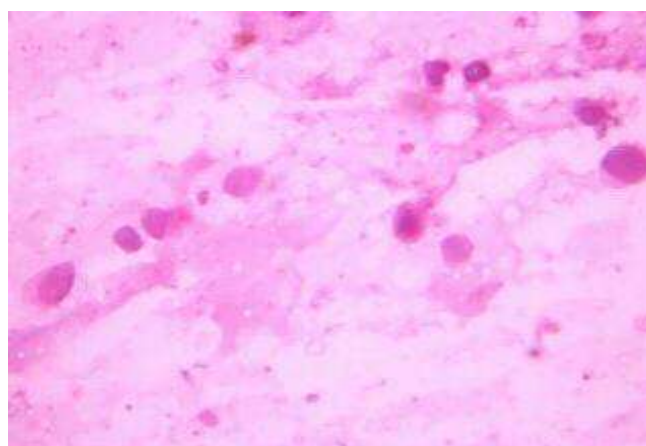


Figure 1: Cytology of thyroid shows lymphoma cells and colloid H&E 40X



Figure 2: Gross photograph of Ovarian lymphoma

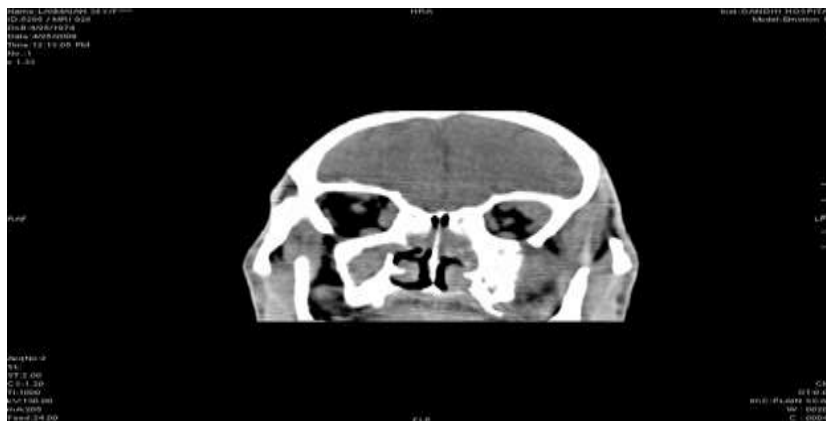


Figure 3: CT shows hyperintense soft tissue masses in left maxillary, bilateral ethmoidal sinuses and both orbits

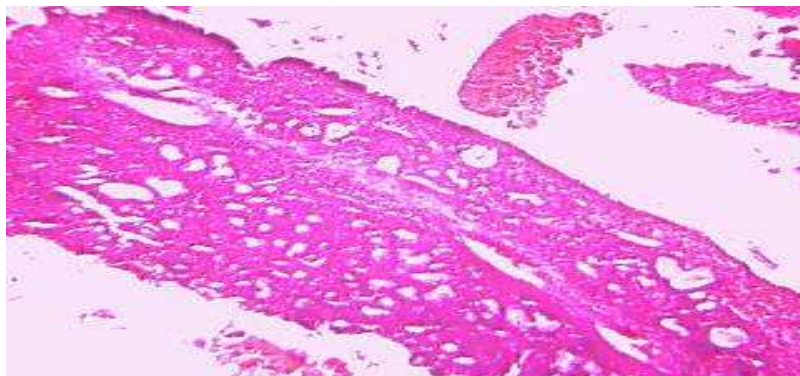


Figure 4: Lymphoma infiltrate in paranasal sinus H&E 10X

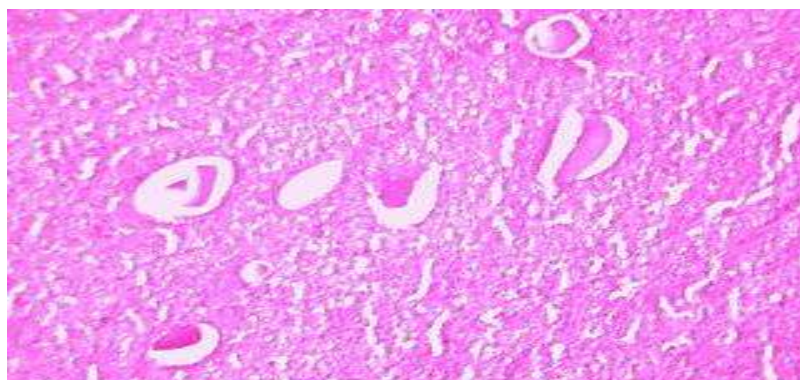


Figure 5: Lymphoma infiltrating into thyroid follicles H&E 40X

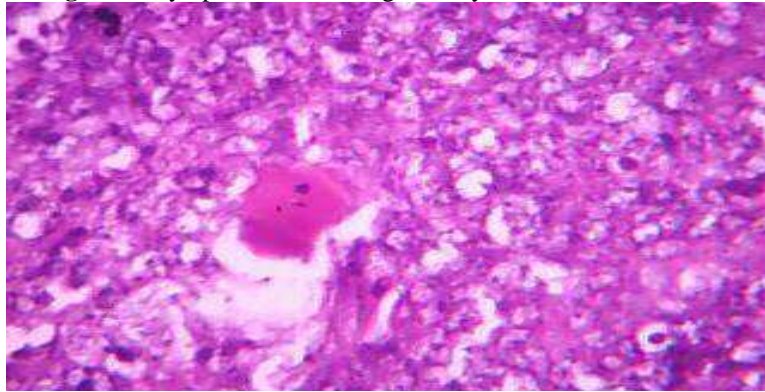


Figure6: Lymphoma infiltrate with thyroid follicle H&E 100X

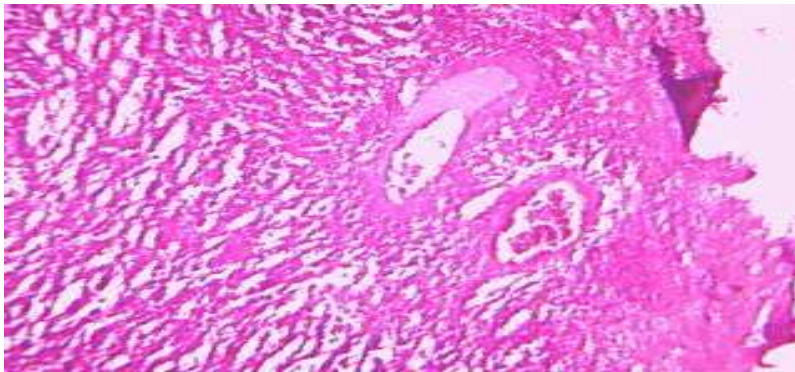


Figure 7: Ovarian stroma infiltrated by lymphoma H&E 40X

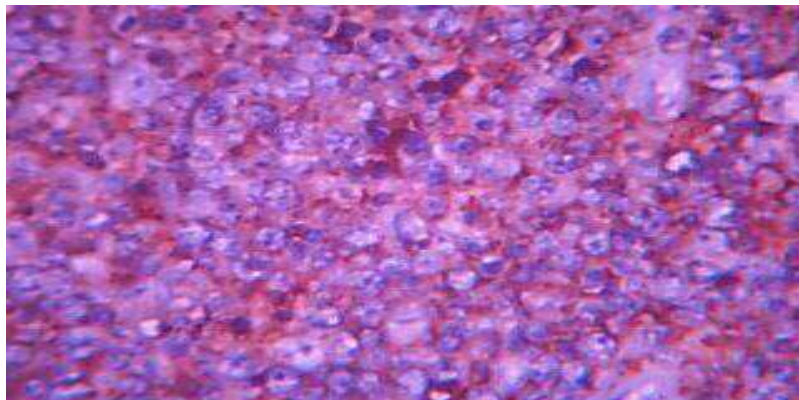


Figure 8 : Lymphoma cells positive for CD 20 on IHC

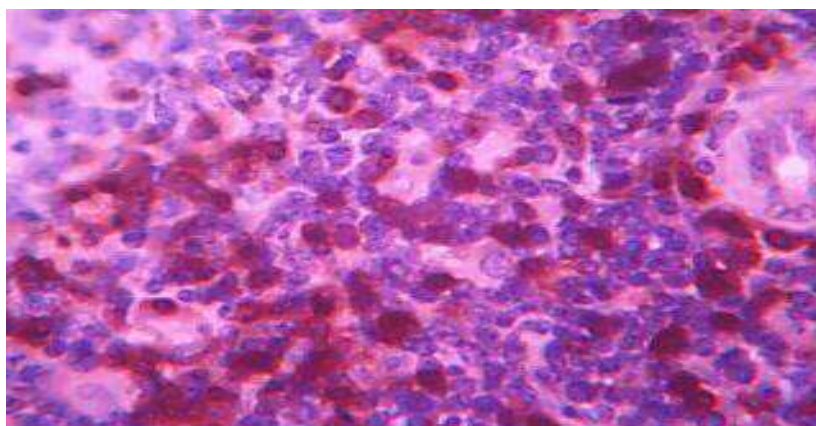


Figure 9: Lymphoma cells positive for CD 3 on IHC

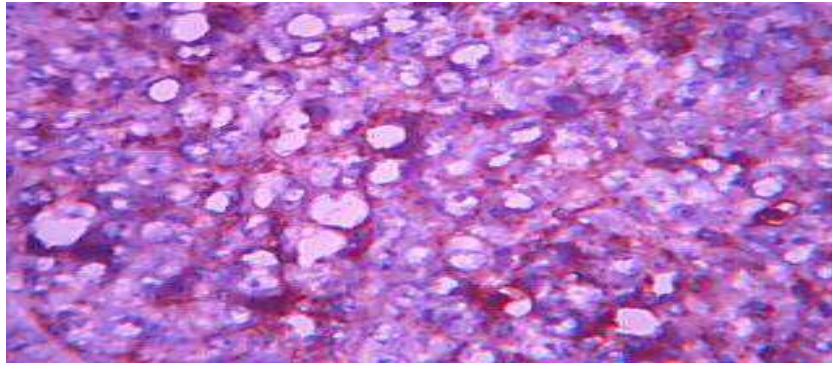


Figure 10: Lymphoma cells positive for CD45 (LCA) on IHC

IV. Discussion

Primary extranodal lymphomas are rare in sites like ovary, thyroid, nasopharynx and CNS.^[4] They usually present with features of carcinoma. Immunohistochemistry plays an important role in diagnosis as well as in subtyping. NHL in gynecologic tract is very rare, usually affects the ovary and most of them are systemic tumors, but only less than 10% have been reported as localized and they manifest like an advanced ovarian cancer with pelvic complaints.^[5-9] The similar clinical presentation was seen in our case.

Primary CNS lymphomas are rare, account for 5-6%.^[10] They are common in immunocompromised patients and almost have an aggressive histology. We reported two cases of CNS lymphomas in immunocompetent patients which is very uncommon. CNS presentation may include spinal cord compression, leptomeningeal spread, intracerebral mass lesions. Epidural and paranasal sinuses involvement is commonly associated with CNS diseases. In our study, one out of two CNS lymphoma cases, NHL in maxillary antrum had involvement of CNS with deposits in spinal cord. Patient presented with signs & symptoms of cauda equina syndrome which is a neurosurgical spinal emergency. These cases were reported very rarely^[11-13]

Nearly all primary NHL of the thyroid develop on a background of Hashimoto's thyroiditis and are Mucosa Associated Lymphoid Tissues (MALT) lymphomas.^[14] In all five cases the presence of positive staining for LCA distinguishes malignant lymphoma from nonlymphoid neoplasm. Four cases were subclassified as B- cell lymphomas (CD10, CD 20 positive & CD3 negative) and one case of CNS lymphoma as T- cell lymphoma (CD 3 positive & CD20 negative)

We report these primary extranodal lymphomas because of its rarity of site of involvement like ovary, thyroid, paranasal sinuses and CNS and also two cases of CNS lymphomas were diagnosed in immunocompetent patients which is very uncommon. As they usually present with features of carcinomas, Immunohistochemistry plays an important role to differentiate from nonlymphoid neoplasm.

References

- [1]. D'Amore F, Christensen BE, Brincker H et al. Clinicopathological features and prognostic factors in extranodal non-Hodgkin lymphomas. *Eur J Cancer* 1991; 27: 1201–8.
- [2]. Newton R, Ferlay J, Beral V et al. The epidemiology of non-Hodgkin's lymphoma: comparison of nodal and extra-nodal sites. *Int J Cancer* 1997; 72: 923–30.
- [3]. Otter R, Gerrits WB, Sandt MM et al. Primary extranodal and nodal non-Hodgkin's lymphoma. A survey of a population-based registry. *Eur J Cancer Clin Oncol* 1989; 25: 1203–10.
- [4]. Marshalla, Ernest beutler, Thomas J. Kipps, Williams Hematology, 7th edition, 2006; 1410- 12.
- [5]. Monterosso V, Jaffe ES, Merino MJ, Medeiros LJ. Malignant lymphomas involving the ovary: A clinicopathologic analysis of 39 cases. *Am J Surg Pathol* 1993; 17: 154- 70.
- [6]. Osborne BM, Robboy SJ. Lymphomas or leukemia presenting as ovarian tumors. An analysis of 42 cases. *Cancer* 1983; 52: 1933–43.
- [7]. Iyengar Pratibha ; Ismill Nadia ; Deodhare Sanjeev; Precursor B-cell lymphoblastic lymphoma of the ovaries: An immunohistochemical study and review of the literature; *International journal of gynecological pathology* ; 2004, 23 (2), 193-7.
- [8]. Yamada T, Iwaoe N, Kasamatsu H, Mori H: A case of malignant lymphoma of the ovary manifesting like an advanced ovarian cancer. *Gynecol Oncol*. 2003 Jul; 90 (1): 215-9.
- [9]. Tijani Elharroudi, Nabil Ismaili, Hassan Errihani, Abdelouahed Jalil: Primary lymphoma of the ovary; *Journal of cancer research and therapeutics*; Year : 2008, 4, (4), 195-6.
- [10]. G. Spectre, A. Gural, G. Amir, A. Lossos, T. Siegal and O. Paltiel; Central nervous system involvement in indolent lymphomas ; *Annals of Oncology* 2005 16(3):450-4.
- [11]. Riffaud et al, Acute Cauda Equina Compression revealing Hodgkin's Disease: Case Report ; *Chang Gung Med J* September–October 2007 ; Vol. 30 No. 5.
- [12]. Hollender A, Kvaloy S, Nome O et al. Central nervous system involvement following diagnosis of non-Hodgkin's lymphoma: a risk model. *Ann Oncol* 2002; 13: 1099–107.
- [13]. Primary central nervous system T-cell lymphoma Gijtenbeek et al. *Neurology*. 2001; 57: 716-718
- [14]. Dilip K. Das, Subhash K. Gupta, Issam M. Francis, Mahmoud Sayed Ahmed; Fine-needle aspiration cytology diagnosis of non-hodgkin lymphoma of thyroid: A report of four cases; *Diagnostic Cytopathology*; 1993; 9 (6), 639 – 45.