

## Case Report: A Case of Wegener's Granulomatosis in A Young Adult Patient- Clinical, Imaging, Pathological And Microbiological Correlation.

Dr. Sameer R. Verma<sup>1</sup>, Dr. Vandana Sardana<sup>2</sup>

<sup>1</sup>Professor Department Of Radiodiagnosis CSS Hospital, Subharti Medical College, Subhartipuram, Meerut

<sup>2</sup>Assistant Professor Department Of Microbiology CSS Hospital, Subharti Medical College, Subhartipuram, Meerut

---

**Abstract:** Wegener's granulomatosis is an uncommon autoimmune disease with multi-system involvement that manifests as vasculitis, granulomatosis and necrosis. We present a case in a young male adult patient presenting with symptoms of chronic sinusitis having extensive sinus and nasal disease on initial CT, with detection of lung lesions and renal involvement and histo-pathological confirmation by antineutrophil cytoplasmic antibody positivity and nasal biopsy along with detection of infection of the nasal and paranasal tissue by *Staphylococcus aureus*. This case highlights the importance of imaging and laboratory investigations, in diagnosis of an uncommon but potentially lethal condition. Further detection of nasal carriage of *Staphylococcus aureus* may be helpful in disease confirmation and prognostication.

**Keywords:** granulomatosis, vasculitis, CT, c-ANCA, *Staph. aureus*

---

### I. Introduction

Wegener's Granulomatosis (WG) was described in detail by Friedrich Wegener in 1936. The incidence is estimated to be 5-12 new cases/million per annum in the United States.<sup>1</sup> WG is characterized by triad of granulomatous lesions of the upper and lower respiratory tract, focal segmental glomerulonephritis and disseminated necrotizing vasculitis. Patient with Wegener's granulomatosis frequently have a clinical symptoms of respiratory tract infection and the ANCA titer elevation. Furthermore, patients with Wegener's granulomatosis have secondary infection of the nasal and paranasal tissue caused by *Staphylococcus aureus*.<sup>2</sup> This case highlights the importance of imaging and laboratory investigations, in diagnosis of an uncommon but potentially lethal condition and detection of nasal carriage of *Staphylococcus aureus* may be helpful in disease confirmation and prognostication.

### II. Case History

A 32 years old male patient presented to our department with symptoms of nasal blockage, blood mixed nasal discharge with redness of eyes for routine CT study of paranasal sinuses. On clinical examination patient had bilateral conjunctival hyperemia, nasal mucosal hypertrophy with polypoidal projections with provisional clinical diagnosis of allergic rhino-sinusitis with polyposis. His blood examination revealed mild anemia (hemoglobin 10.2 gm/dl), leucocytosis with neutrophilia (TLC- 13,600/ mm<sup>3</sup> with neutrophilia) and markedly elevated ESR (120mm in first hour by Westergren method).

CT PNS examination revealed bilateral paranasal sinus soft tissue opacification (most marked in ethmoidal sinuses) with extension of pathology in nasal cavity with thinning of nasal turbinates and bony nasal septal perforation. No intracranial or intraorbital extension of pathology was noted [Figure 1].

On further elucidation of history patient revealed complaints of cough, occasional dyspnoea and chest discomfort. His chest X-ray revealed nodular shadow in left apical region, with subsequent CT chest revealing nodular pulmonary lesions in apical segments of both upper lobes abutting pleura [ Figures 2 ] with mild right pleural effusion [Figures 3].

Ultrasound of the abdomen of the patient revealed bilateral raised renal parenchymal echogenicity with normal renal size [Figure 4]. Subsequent urine microscopy revealed microscopic hematuria and proteinuria. His serum creatinine was marginally raised (1.4 mg/dl).

Based on the complete radiological findings with relevant clinical and laboratory investigations possibility of Wegener's Granulomatosis was suggested. The diagnosis was confirmed by histopathological examination of nasal tissue excised on surgery which revealed granulomatous inflammation [Figure 5] and presence of Antineutrophil cytoplasmic antibody (C-ANCA) in serum. Culture of nasal tissue material revealed growth of *Staphylococcus aureus* which was also isolated in swab culture from the anterior nares of the patient subsequently.

### **III. Discussion**

Limited form of WG with involvement of the upper respiratory tract and the lungs with renal sparing is frequently seen in women, while the kidneys are involved in the common form frequently seen in men.<sup>3</sup> Sinus and nasal involvement is seen in 70-90% of patients, lung lesions are noted in 80-90% of patients with pleural involvement seen in 25-30% of patients and renal involvement is seen in 70-80% of patients throughout the course of disease.<sup>4</sup> Although WG may occur at any age, the mean age of occurrence is 40 to 55 years old. The M/F ratio is equal.

The four criteria of diagnosis defined by the American College of Rheumatology (ACR) for WG are as follows: 1) Oral or nasal ulcers, or purulent bloody flux 2) An abnormal lung X-ray revealing nodules and cavities 3) An abnormal urinary sediment 4) Granulomatous inflammation in the extra vascular region at biopsy.<sup>5</sup> The presence of two or more of these criteria has a sensitivity of 88% and a specificity of 99%.<sup>5,6</sup>

Pathologically, WG is characterized by necrotizing granulomatous inflammation of small vessel walls, resulting in areas of necrosis surrounded by hemorrhage, small micro abscesses and granulomata within the lungs. A normocytic anaemia, leucocytosis, elevated erythrocyte sedimentation rate (ESR), positive rheumatoid factor and antineutrophil cytoplasmic antibody (specifically PR3-ANCA) are often shown on serology. PR3-ANCA is positive in 85% of patients with active multiorgan WG, but this reduces to 30-40% in remission.<sup>6,7</sup>

Wegener's granulomatosis is associated with bacterial infection, in particular nasal carriage of *Staphylococcus aureus*. Infection may play a role in the induction of autoimmunity as well as in the effector phase of the disease through several mechanisms including molecular mimicry and TLR signaling.<sup>8</sup>

Furthermore chronic nasal carriage of *Staphylococcus aureus* may contribute to increased relapse rate of the disease.<sup>2</sup>

#### **Imaging findings**

##### **Chest**

The most common imaging findings are discrete focal opacities that vary in size and appearance from diffuse consolidation to nodular masses, with no zonal predilection, are usually multiple, round or oval in shape, and cavitate in at least 25% with possibility of secondary infection.<sup>9,10</sup> On high resolution CT, ground glass shadowing may surround the nodules, which may be due to hemorrhage. Subglottic tracheal and bronchial wall thickening and narrowing may cause secondary lobar collapse.<sup>11</sup> Pleural thickening and small effusions may occur variably depending on the series quoted.<sup>9,11</sup>

##### **Nasal cavity and paranasal sinuses**

Non-specific mucosal thickening or antral opacification are typical early features, followed by nasal septal thinning and granulomatous ulcerated change. Bony destruction is also frequently demonstrated on CT including a necrosed nasal septum (saddle nose deformity). There may be sinus atrophy and the maxillary bone may progressively ossify.<sup>12</sup> On MRI, granulomatous tissue varies in signal with the stage of inflammation. In the early phase of inflammation nonspecific T2 weighted signal hyperintensity is present, but as granulomatous transformation progresses, granulomata appear hypointense.<sup>13</sup>

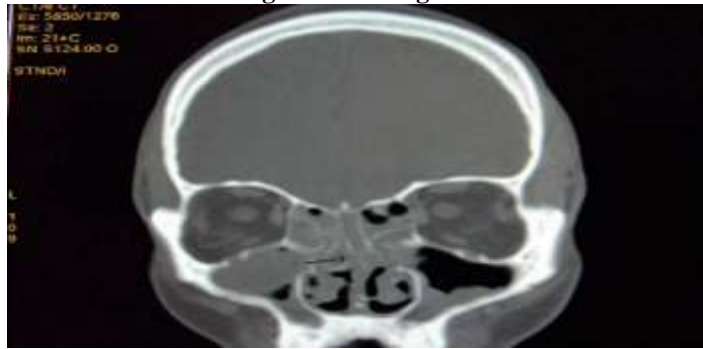##### **Kidneys**

Limited forms of WG sparing the kidney are rare. Usually severe progressive necrotizing glomerulonephritis occurs resulting in rapid deterioration of renal function. Large echogenic kidneys on ultrasound without specific Doppler abnormalities are typical early findings which may rapidly progress to scarred shrunken kidneys with chronic renal failure.<sup>14</sup> More rarely, a pseudotumour may also be present as a non-specific infiltrative lesion indistinguishable from many other renal masses, isointense on T1 weighted and mixed signal on T2 weighted MRI.<sup>15</sup>

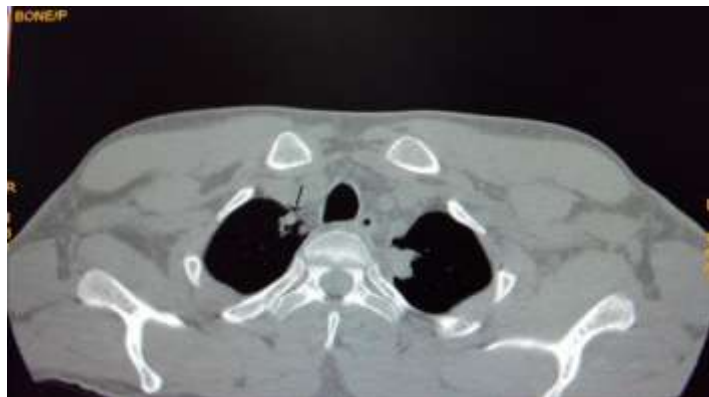Our patient clinically meets the ACR diagnostic criteria and had positive microbiological and pathological findings. Glucocorticoids and cyclophosphamide are recommended for treatment with serial ESR monitoring. While formerly WG was universally fatal within a few months of onset of clinically apparent renal disease, using the above therapy, the prognosis of disease is excellent with marked improvement seen in > 90% of patients and complete remissions achieved in 75% of the patients.<sup>16</sup> Our patient was also put on prednisone and cyclophosphamide therapy with significant remission of symptoms on subsequent follow up. Antiseptic washes and topical antibiotics were prescribed for eradication of nasal carriage of *Staphylococcus aureus* based on culture sensitivity reports.

As a conclusion, WG should be considered in cases presenting with extensive sino-nasal disease and associated chest signs and symptoms and early diagnosis and prompt treatment should be performed. Detection of nasal carriage of *Staphylococcus aureus* may be helpful in disease confirmation and prognostication.

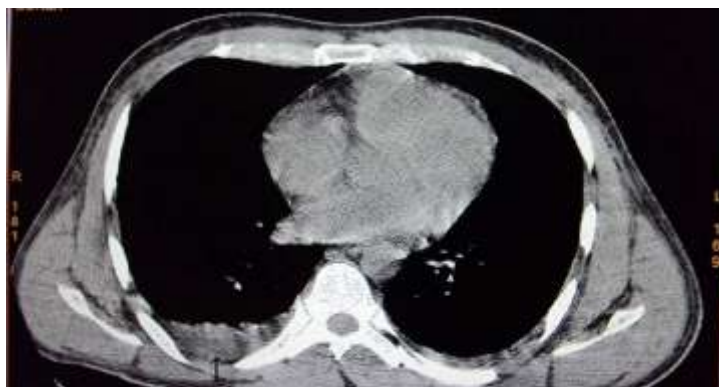Figures And Legends



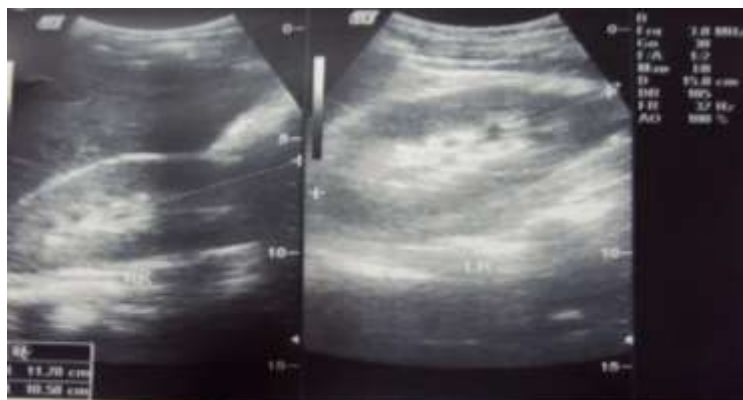**Figure 1 :** CT PNS shows bilateral nasal cavity and paranasal sinus opacification with nasal septal perforation (arrow).



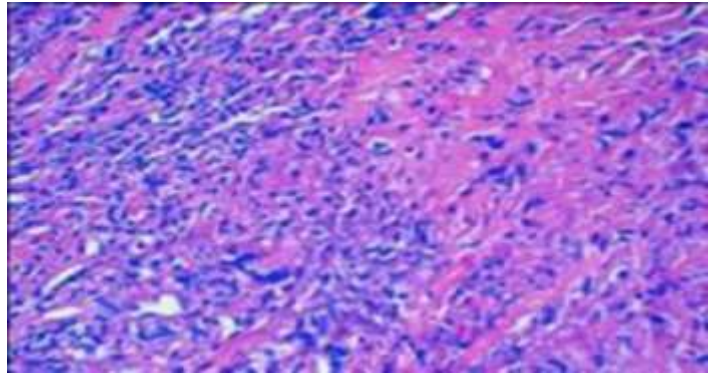
**Figure 2 :** CT chest shows two nodular parenchymal opacities abutting pleura in right lung apical region (arrow).



**Figure 3 :** CT chest shows mild pleural effusion in right lower chest posteriorly (arrow).



**Figure 4 :** USG image shows bilateral raised renal parenchymal echogenicity with normal renal size.



**Figure 5 :** Excised nasal tissue slide photomicrograph shows granulomatous inflammation (Hematoxylin and Eosin, Magnification 100X )

### References

- [1]. Seaton A. Pulmonary lymphocytic angitis and granulomatosis. In, Seaton A (ed). Crofton and Douglas's Respiratory Diseases. 5<sup>th</sup> edition, London, Blackwell Science Inc, 2000;1063
- [2]. Zycinska K, Wardyn KA, Zielonka TM, Demkow U, Traburzynski MS. Chronic crusting, nasal carriage of *Staphylococcus aureus* and relapse rate in pulmonary Wegener's granulomatosis. *J Physiol Pharmacol.* **2008**;59 Suppl 6:825-31.
- [3]. Cotch MF, Hoffman GS, Yerg DE, Kaufman GI, Targonski P, Kaslow RA. The epidemiology of Wegener's granulomatosis. Estimates of the five-year period prevalence, annual mortality, and geographic disease distribution from population-based data sources. *Arthritis Rheum* 1996;39:87-92.
- [4]. Sneller MC, Langford CA, Fauci AS. The vasculitis syndromes. In, Kasper DL (ed). Harrison's principles of internal medicine, 16<sup>th</sup> edition. New York, McGraw-Hill Companies, 2005; 2005
- [5]. Leavitt RY, Fauci AS, Bloch DA, Michel BA, Hunder GG, Arend WP et al. The American College of Rheumatology 1990 criteria for the classification of Wegener's granulomatosis. *Arthritis Rheum* 1990;33:1101-7.
- [6]. Hoffman GS, Kerr GS, Leavitt RY, Hallahan CW, Lebovics RS, Travis WD et al. Wegener's Granulomatosis: An Analysis of 158 Patients. *Ann Intern Med* 1992;116:488-98.
- [7]. Rao JK, Weinberger M, Oddone EZ, Allen NB, Landsman P, Feussner JR. The role of antineutrophil cytoplasmic antibody (c-ANCA) testing in the diagnosis of Wegener
- [8]. Granulomatosis : A literature review and meta-analysis. *Ann Intern Med* 1995;123:925-32.
- [9]. Tadema H, Heeringa P, Kallenberg CG. Bacterial infections in Wegener's granulomatosis: mechanisms potentially involved in autoimmune pathogenesis. *Curr Opin Rheumatol.* 2011;23(4):366-71.
- [10]. Maskell GF, Lockwood CM, Flower CD. Computed tomography of the lung in Wegener's granulomatosis. *Clin Radiol* 1993;48:377-80.
- [11]. Lohrmann C, Uhl M, Kotter E, Burger D, Ghanem N, Langer M. Pulmonary manifestations of Wegener granulomatosis: CT findings in 57 patients and a review of the literature. *Eur J Radiol* 2005;53:471-7.
- [12]. Kuhlman JE, Hruban RH, Fishman EK. Wegener's Granulomatosis: CT Features of Parenchymal Lung Disease. *J Comput Assist Tomogr* 1991;15:948-52.
- [13]. Rasmussen N. Management of ear, nose and throat manifestations of Wegener's granulomatosis: an otorhinolaryngologist's perspective. *Curr Opin Rheumatol* 2001;13:3-11.
- [14]. Muhle C, Reinhold-Keller E, Richter C, Duncker G, Beigel A, Brinkmann G et al. MRI of the nasal cavity, the paranasal sinuses and orbits in Wegener's granulomatosis. *Eur Radiol* 1997;7:566-70.
- [15]. Allen SD, Harvey CJ. Imaging of Wegener's granulomatosis. *Br J Radiol* 2007; 80: 757-65.
- [16]. Verswijvel G, Eerens I, Messiaen T, Oyen R. Granulomatous renal pseudotumor in Wegener's granulomatosis: imaging findings in one case. *Eur Radiol* 2000;10:1265-7.
- [17]. Sneller MC, Langford CA, Fauci AS. The vasculitis syndromes. In: Kasper DL (ed). Harrison's principles of internal medicine, 16<sup>th</sup> edition. New York, McGraw-Hill Companies, 2005;2006.