

Efficacy of Tacrolimus 0.03% Eye ointment in treatment of chronic ocular surface inflammation in severe dry eye

Dr.Monika Kharbanda, Dr.Sachin Walia, Dr.Harsimran Singh, Dr.Ishwar Singh
Ophthalmology Department Govt. Medical College Patiala 147001 Punjab, India

Abstract

Aim: To evaluate the efficacy of tacrolimus 0.03% eye ointment in treatment of chronic ocular surface inflammation in severe dry eye.

Material and Methods: We evaluated the effectiveness of tacrolimus 0.03% eye ointment in treatment of chronic ocular surface inflammation in severe dry eye. A total of 30 eyes of 15 patients were included in this study, who used tacrolimus 0.03% eye ointment BD (twice a day) for three months. Evaluation of patient was done by subjective and objective scores, before the study, at follow up visit and end of the study.

Results: Clinically and statistically significant improvement was seen both objectively and subjectively in patients of severe dry eye treated with topical Tacrolimus.

Conclusion: Tacrolimus eye ointment was found effective in treatment of chronic ocular surface inflammation in severe dry eye as evidenced by improvement in subjective assessment of symptoms, staining, schirmer's score and tear film break up time.

Keywords: Chronic ocular surface inflammation, tacrolimus, dry eye.

I. Introduction

Dysfunctional and unstable tear film in dry eye leads to production of inflammatory mediators in the tear fluid. The increased activity of inflammatory mediators is responsible for pathological alteration to the ocular surface and cellular damage. The relentless cycle of ocular surface inflammation and immune activation leads to decreased tear production through a negative feedback mechanism in dry eye. This concept has led to the development of novel therapies in treatment of disease as the focus shifts from symptomatic relief to address the underlying pathology. The topical antiinflammatory and immunomodulator may favourably alter the long term prognosis of patients with inflammation in dry eye and help in ocular surface healing disrupting the vicious cascade of events. That is why, tacrolimus an immunosuppressant drug comes into use which has antiinflammatory and immunosuppressive action. It is 10 to 100 times more potent than topical cyclosporine[1]. Its use in clinical treatment of dry eye was first described by Moscovici et al in 2012 in humans[2]. Therefore, the present study was designed to evaluate the efficacy of Tacrolimus 0.03% eye ointment in relieving the symptoms and objective improvement in patients of chronic ocular surface inflammation due to dry eye.

II. Material and methods

This present prospective study was conducted in department of Ophthalmology, Rajindra Hospital Patiala from 16.07.2015 to 16.03.2016 (Eight months).The study included 30 eyes of 15 patients with ocular surface inflammation due to severe dry eye.

Criteria for patient selection:

The study included the patient who satisfied the following criteria

- Symptoms as discomfort and fatigue
- Flourescein staining of cornea.
- Schimer Test < 5 mm at 5 min.
- BUT < 5 seconds

Criteria for patient exclusion

- Pregnant/lactating women
- Glaucoma Patients
- Contact lens wearer
- Previous eye surgery
- Use of any other ocular medication (other than artificial tears)
- Presence of any microbial infection

Evaluation of patient was done before as well as after initiation of treatment in follow up, by determining the subjective and objective score.

- Subjective evaluation was done by the following grading method.

- Grade 0 - No symptom
- Grade 1 - Mild symptom with no discomfort
- Grade 2 - Moderate symptom with mild discomfort
- Grade 3 - Severe symptoms with discomfort but no interference with daily activities.
- Grade 4 - Very severe symptoms with discomfort and interference with daily activities.

Objective evaluation :

- Ocular surface evaluation was done by Fluorescein staining for corneal damage. Fluorescein staining was rated 0 to 9 and score of 3 or more was value for diagnosis of dry eye.
- Tear evaluation was done by Schirmer's Test after the instillation of topical proparacaine using standard tear strips kept in the conjunctival sac for 5 minutes.
- Tear evaluation was done by TBUT. It was determined by application of moist fluorescein strip into the conjunctival sac within 30 seconds with slit lamp using diffuse cobalt blue light as was measured upto only 10 seconds.

III. Observations

Table-1 : Fluorescein Score

Sr. No.	Time Interval	Fluorescein Score				
		Mean	SD	SE Difference	t-test	P value
1	Baseline	3.93	0.79	--	--	--
2	After 1 st Month	2.73	0.46	0.262	4.583	0.01
3	After 3 rd Months	1.67	0.52	0.274	9.012	0.001

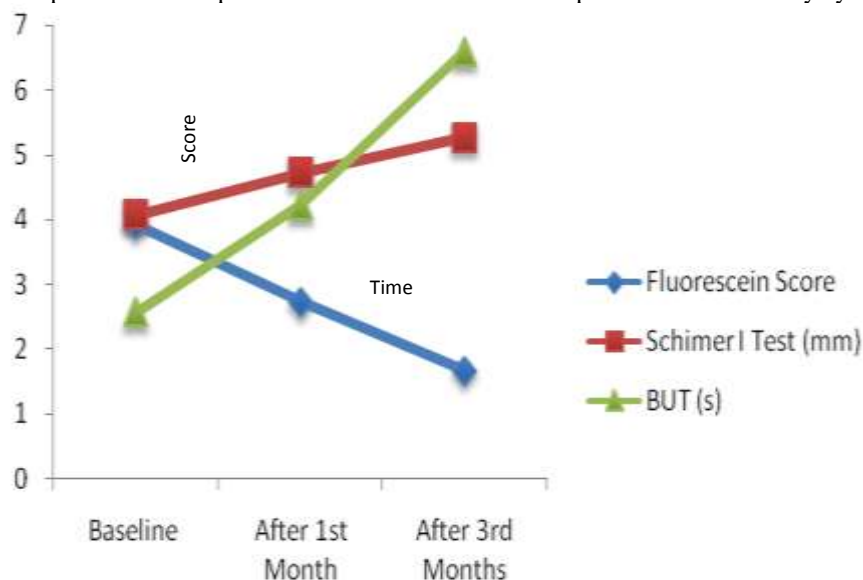
Table-2 : Schimer I Test Score

Sr. No.	Time Interval	Schimer I Test (mm)				
		Mean	SD	SE	t-test	P value
1	Baseline	4.07	1.03	--	--	--
2	After 1 st Month	4.73	1.04	0.270	2.467	0.027
3	After 3 rd Months	5.27	0.88	0.312	3.850	0.002

Table-3 : Tear film breakup time score

Sr. No.	Time Interval	BUT (s)				
		Mean	SD	SE	t-test	P value
1	Baseline	2.57	0.49	--	--	--
2	After 1 st Month	4.23	1.11	0.357	1.953	0.07
3	After 3 rd Months	6.60	1.61	0.222	2.414	0.05

Graph 1 Overall improvement after treatment with topical tacrolimus in dry eye



IV. Results

Out of 15 patients in the present study 9 were males and 6 were females. Distribution of patients according to age showed maximum number of patients belonged to age group more than 50 years and the mean age of patient was 51.9 years. At base line, all patients had discomfort and fatigue as presenting complaints, positive staining, Schirmer was sub-normal and BUT was <5 seconds. On the first follow up at 4 weeks of treatment, subjective scores improved markedly in all patients. Flourescein staining decreased to $2.73 \pm .46$, Schirmer was 4.73 ± 1.04 value of BUT was 4.23 ± 1.11 seconds. There was little improvement in ocular surface inflammation as evidence at the end of 1 month. On last follow up at 3 months, 30 eyes were mostly symptom free, Flourescein score was $1.67 \pm .52$, Schirmer score recorded was 5.27 ± 0.88 , BUT was 6.60 ± 1.61 seconds. So at the end of the study there was shift noted in 30 eyes from severe to either mild or moderate degree. Only three patients complained of mild burning sensation on instillation of the eye ointment but continued the drug and completed the study. No complications were reported in this study as redness or epithelial keratitis.

V. Discussion

Dry eye is the most common ocular disease encountered in practice. It causes discomfort to many people. In dry eye there is tear hyperosmolarity acting as central mechanism for pathogenesis of ocular surface damage and inflammation. It destroys the surface epithelium, triggers production of interlukins, matrix metalloproteinases and hyperactivity of T lymphocytes. Thus, a vicious cycle of inflammation develops on the ocular surface in dry eye leading to chronic inflammation. Tacrolimus is a 23 membered macrolide lactone agent and immunosuppressant isolated from bacterium *streptomyces tsukubaensis* in 1984, used mainly after allogenic organ transplant to lower the risk of organ rejection[3]. Tacrolimus binds to FK506-binding proteins within T lymphocytes and inhibits calcineurin activity. Calcineurin inhibition results in decreased formation of T helper and Th2 cytokines. It blocks the early phase of T cell activation and IL-2 transcription[4]. Topical Tacrolimus eye ointment inhibits the loss of conjunctival epithelium and helps in the proliferation of goblet cells[5]. It has shown to decrease molecular markers of apoptosis (CD40, CD40 ligand) in the inflamed conjunctival epithelium.

Several clinical trials have shown the beneficial effect of systemic and topical tacrolimus in the treatment of refractory ocular surface inflammation due to vernal keratoconjunctivitis[6], atopic keratoconjunctivitis[7], mooren ulcer[8], uveitis[9], ocular pemphigoid and corneal graft rejection[10,11].

These have laid the groundwork for studies using topical tacrolimus eye ointment for the treatment of ocular inflammation in severe dry eye. First of all Berdoulay et al in 2005 studied the effect of topical tacrolimus 0.02% on tear production in dogs with keratoconjunctivitis sicca[12]. In three months trial of 8 dry eye patients, Moscovici et al reported improvement in all patients at the end of treatment in subjective symptoms, ocular surface staining and tear film stability in 2012. Topical 0.03% tacrolimus eye drop improved tear stability and ocular surface status in 24 cases of inflammatory SS-related dry eye as reported by Moscovici et al in prospective double blind randomized study in 2015[13]. This is consistent with our findings, during the first month of treatment corneal staining score, Schirmer test and TBUT score were lower. At the end of three months trial, we found significant improvement in all the subjective and objective score in patients treated with tacrolimus eye ointment.

VI. Conclusion

Tacrolimus 0.03% eye ointment is safe and effective as treatment of chronic inflammation in severe dry eye. It provided symptomatic relief as well as improvement in objective score. But the number of patients enrolled in our study group were very small and no control group was included in the study. Further studies are needed to evaluate the long terms safety results of medication in larger group of patients. However, it is likely be a viable option for ocular surface inflammation associated with dryness.

References

- [1]. Pleyer U, Lutz S, Juske WJ, et al. Ocular absorption of topically applied FK506 from liposomal and oil formulations in the rabbit eye. Invest Ophthalmol Vis Sci 1993; 34:2737-42.
- [2]. Moscovici BK, Holzchuh R, Chiacchio BB, Santo RM, Shimazaki J, Hida Ry. Clinical treatment of dry eye using 0.03% tacrolimus eye drops, Cornea 2012;31:945-9
- [3]. Busuttill RW, Holt CD. Tacrolimus is superior to cyclosporine in liver transplantation. Transplant Proc 1998; 30(5):2174-8.
- [4]. Liu J, Farmer J, Lane W, et al. Calcineurin is a common target of cyclophilin cyclosporin A and FKBP-FK506 complexes. Cell 1991; 66(4):807-15.
- [5]. Kino T, Hatanaka H, Hashimoto M, et al. FK-506, a novel immunosuppressant isolated from a Streptomyces: I. Fermentation, isolation, and physico-chemical and biological characteristics. J Antibiot 1987; 40:1249-55.
- [6]. Kumar S. Vernal keratoconjunctivitis: a major review. Acta Ophthalmol 2009; 87(2):133-47.
- [7]. Nivenius E, van der Ploeg I, Jung K, et al. Tacrolimus ointment vs steroid ointment for eyelid dermatitis in patients with atopic keratoconjunctivitis. Eye (Lond), 2007; 21:968-975.
- [8]. Xie H, Chen J, Lin Y, et al. Effect of topical FK506 used alone or combined with keratoplasty on patients with recurrent Mooren's corneal ulcer. Yan Ke Xue Bao 2006; 22:207-13.

- [9]. Oh-i K, Keino H, Goto H, et al. Intravitreal injection of tacrolimus (FK506) suppresses ongoing experimental autoimmune uveoretinitis in rats. *Br J Ophthalmol* 2007; 91:237-42.
- [10]. Sloper CM, Powell RJ, Dua HS. Tacrolimus (FK506) in the management of high-risk corneal and limbal grafts. *Ophthalmology* 2001; 108(10):1838-44.
- [11]. Aoki S, Mizote H, Minamoto A, Suzuki M, Mishima HK, Tanaka H, Systemic FK506 improved tear secretion in dry eye associated with chronic graft versus host disease. *Br J Ophthalmol* 2005;89:243-4.
- [12]. Berdoulay A, English RV, Nadelstein B. Effect of topical 0.0% tacrolimus aqueous suspension on tear production in dogs with keratoconjunctivitis sicca. *Vet Ophthalmol* 2005;8:225-32.
- [13]. Bernardo Kaplan Moscovici, Ricardo Holzchuh Fernando Eiji Sakassegawa-Naves, Diego Ricardo Hoshino-Ruiz et al. Treatment of Sjogren's syndrome dry eye using 0.03% tacrolimus eye drop: Prospective double-blind randomized study. *Contact lens & Anterior Eye* 2015; <http://dx.doi.org/10.1016/j.clae.2015.04.004>.