

Parameters for Paget's Disease of Bone Diagnosis: Clinicoradiographic Features, Biochemical, Cytogenetic, and Histopathology

Dr. Omar.A. Rageh, B.D.S .

Department of Oral and Maxillofacial Pathology, Faculty of Oral & Dental Medicine - Cairo University

Abstract:

Objective: To conduct a literature review on the diagnosis and management of Paget's disease of bone.

Materials and methods: The Literature was collected and reviewed about Paget's disease of bone, sure the relevant clinicoradiographic criteria and diagnosis. Literature was selected through the search of PubMed, Cochrane Library, and scholar Google databases. The keywords used for the search were Paget's disease of bone, diagnosis ,physiopathology, radiography. A manual search of the reference lists of the identified articles and the authors' article files and recent reviews was conducted to identify additional publications. Those studies that showed new features about Paget's disease of bone were included in this review.

Results: In total 10 literature sources were searched and reviewed. Studies that described new features about Paget's disease of bone physiopathology, diagnostics parameter were reviewed.

Conclusion: We present a scientific statement on Paget's disease of bone providing the level of evidence and the degree of recommendation regarding causes, clinical presentation as well as surgical and medical treatment.

Keywords: Paget's disease of bone; diagnosis; physiopathology.

I. Introduction

Paget,s Disease of the bone, has another medical term as OsteitisDeformans, is a disorder caused by osteoclast overactivation, leading focal areas of excessive bone remodeling that over time heal in a haphazard, structurally weak arrangement leads to deformation and fracture. Onset is almost always in the elderly with a slight predilection for men.¹

Paget's disease of bone (PD) is a polyostotic or monostotic non-hormonal osteometabolic disorder. Over a century after the original disease was described by Sir John Paget¹ in 1877, despite recent intensive studies and widespread interest, its etiology remains unclear. This article review describes the pathomechanism of the structural changes which occur in bone affected with PD, induced by the different dynamic patterns of activity of the disease, and outlines the current and more advanced methods and parameters of diagnosis of disease.²

PDB is a disorder of bone resorption, with increased numbers of stimulated multinucleated osteoclasts found in affected bones .In response to such increased bone resorption, there is a compensatory increment in bone formation. Due to the accelerated turnover rate, newly formed bone is large, disorganized (woven bone) and over vascularization , which clears the clinical findings of expansions, painful, and warm bone lesions³.

The goals of the present paper were to review the literature and to report the most important aspects of PDB in order to facilitate the study of this disease.

Clinical characteristics and symptoms

Clinical features: The disease principally affects older adults. Men are affected more often than women, and whites are affected more frequently than blacks. The asymptomatic disease often is discovered in radiographs taken for unrelated reasons or from an unexpected elevation in serum alkaline phosphatase. Although the disease may be monostotic (i.e.,limited to one bone), most cases of Paget's disease are polyostotic (i.e., more than one bone is affected)⁴.

The patients with PDB may already have complications at time of diagnosis, such as bone fractures or neurological disorders related to the site of the pagetic lesion including deafness, spinal cord or

cranial nerve compression, or hydrocephalus³. The High-output congestive heart failure and transformation of the pagetic lesion to sarcomatous are very rare complications was reported. In addition, osteosarcomas occur in less than 0.5% of PDB patients but should be suspected if sudden passing transforms to manifestations (pain, deformity) are documented³. In other hands, the rare complication of PDB is hypercalcemia in patients immobilized for a long period (healing of the fracture, for example), explained to be due to unbalanced bone resorption in the absence of mechanical stimuli to bone formation. Nevertheless, up to 95% of people with PDB may be totally asymptomatic. It is important to keep in mind, though, that even in such individuals, the disease is gradually progressive and may lead to symptoms and deformities in the future, as documented by Siris and Feldman on the 25-year follow-up of an asymptomatic patient.

Morphological phase:

Osteolytic Phase

The initial osteolytic phase of Paget Disease is described by the prominent vascularization as well as the presence of prominent multinucleated osteoclasts surrounding affected bone with accompanying evidence of bone resorption.(i.e.osteoclast activity predominates)⁵

Mixed Phase

During the mixed phase, osteoclast-play a role in bone resorption continues but is now associated with evidence of new bone formation. Vascularization of affected bone begins to decrease as the lesion evolves into its sclerotic phase.(osteolytic-osteoblastic)⁵

Sclerotic Phase

The last phase of PDB sees a gradual inclined in osteoclast activity but is described by progressive formation of haphazardly arranged bone in a characteristic "woven" architecture. The mosaic pattern of the newly formed bone deposition stands in contrast to the normal lamellar architecture and is structurally weaker, leading a propensity for fracture or deformation.(osteoblastic activity predominates (burnout stage)⁵.

Etiopathogenesis **Viral theory** :as yet unidentified paramyxovirus similar to measles virus (which cause Canine distemper)may be the initial trigger for the disease,To help determine the mechanism responsible for the increased OCL formation by measles virus nucleotide protein (MVNP-transduced cells), we examined the expression of RANK and IL-6 by MVNP-transduced cells. RANK is expressed on committed OCL precursors and is critical for OCL formation Furthermore, IL-6 is expressed at high levels by pagetic OCLs, but not by normal OCLs, and may act as an autocrine factor to increase OCL formation in patients with Paget's disease .IL-6 also increases proliferation of early OCL precursors⁶.

Environmental theory:An environmental trigger for Paget disease has long been considered but never proven. Genetic theory PDB is considered to be a disease of the osteoclasts. Bone marrow and circulating osteoclast precursors documented increased sensitivity to factors lead to stimulating bone resorption such as 1,25dihydroxy vitamin D and receptor activator of NF-kB ligand (RANKL) . as well asIncreased interleukin-6 (IL-6), expression and signaling may paly a role to progressive osteoclastic activity. RANKL (which stimulates osteoclastic differentiation) expression is increased in pagetic marrow cells and increase levels of circulating RANKL were documented recently in PDB patients.Osteoblasts are increased in numbers at pagetic lesions, however, they are normal morphologically and are not classified to be a primary pathophysiologic factor in PDB by most authorities⁷.

The first-degree relatives Individual often reported a history of PDB. Before discussing the genetics of PDB and its disorders related is appropriate to discuss the RANK ligand/RANK/OPG system ,This system plays a role in osteoclast function RANK (receptor activator of NF-kB) is expressed on osteoclast precursors. Rank ligand (RANKL), which is expressed in the marrow stroma and on osteoblasts, binds RANK expressed on osteoclast precursors stimuli osteoclast proliferation and differentiation Rank ligand (RANKL), which is expressed in the marrow stroma and on osteoblasts, binds RANK expressed on osteoclast precursors stimuli osteoclast proliferation and differentiation. Osteoprotegerin(OPG) is a decoy receptor which binds RANKL, thus preventing RANKL from binding RANK. OPG, therefore, inhibits osteoclast differentiation. Juvenile PDB (also known as hereditary hyperphosphatasia) is associated with

inactivating mutations in OPG (TNFRSF11B) ,Loss of this decoy receptor for RANK results in increased binding of RANK to RANKL and therefore increased osteoclastic differentiation/ activity. Regardless of OPG mutations not the most common cause of classical Paget's disease, however, the polymorphisms of this gene may be contribute with PDB in women . a stimulate mutations of RANK (TNFRSF11A) leads to familial expansion osteolysis expansile skeletal hyperphosphatasia, and early-onset Paget's disease, as well as RANK Mutations of, do not appear to be a common cause of classicalPDB(figure 1).⁸

The recent research detected , recurrent mutations in the sequestosome 1 gene (SQSTM1) (also known as p62), which contribute to the regulation of osteoclastic activity by the nuclear factor- (NF- κ B) transcription activation pathway, have been documented in both familial and sporadic cases of the disease. Mutations in another gene involved in the (NF- κ B) signaling pathway, the valosin-containing protein (VCP) gene, have been detected in patients with a rare hereditary syndrome that includes Paget's disease of bone, inclusion body myopathy, and frontotemporal dementia (figure 1).⁸

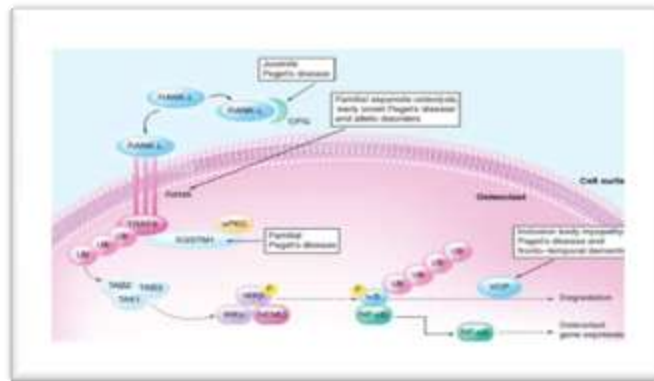


Figure- 1 The Rank–NF- κ B signaling pathway. (Expert Rev. Mol. Med. 9,1–13, (2007).

Diagnostics

Radiographic

Plain radiographies of defected bones and bone scintigraphy are most useful in diagnosing PDB. On radiography, the pagetic lesion may appear to be lytic, sclerotic or, commonly, both . Cortices of long bones are thickened, and when the pelvis is affected, cortical thickening of the superior pubic ramus may often be seen. Typically, radiography of long standing PDB of the skull display as “cotton wool spots” corresponding to sites of bone sclerosis (figure 2&3). Bone scintigraphy with Tc-99m-MDP display an area of excessive radionuclide uptake coinciding with the radiographic bone lesion, show increased bone turnover and vascularity and is specifically useful to identify additional sites in polyostotic PDB, and to act as a basal record for after-treatment comparison. Computerized tomography and magnetic resonance imaging are not specific parameters for the diagnosis of PDB, but it is useful when neurological symptoms of compression are present, or when there is clinical or radiographic suspicion of osteosarcoma³



Figure 2 Paget's disease. Lateral skull film shows marked enlargement of the cranium with new bone formation above the outer table of the skull and a patchy, dense, “cotton wool” appearance. (Courtesy of Dr. Reg Munden).

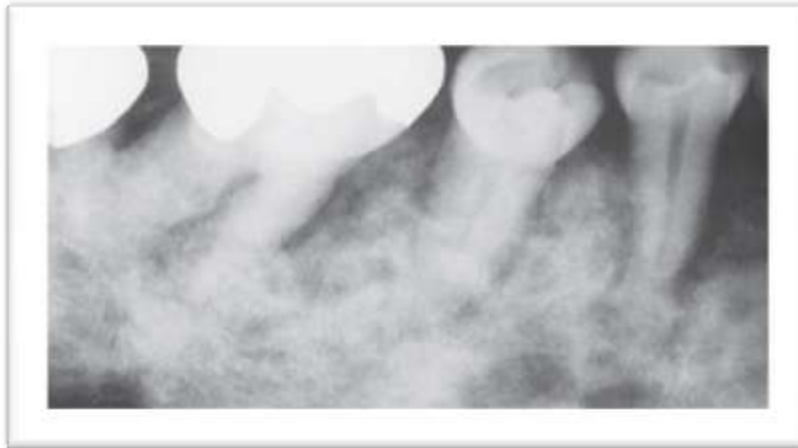

Figure -3 Paget's disease. Periapical film showing the "cotton wool" appearance of the bone.

Biochemical parameters

The laboratory parameters of PDB has increased serum ALP levels, principally because to the extensive experience with the use of this easily obtainable bone formation marker. However, roughly half for serum ALP high levels are attributable to a liver-specific isoform and, therefore, it is wise to analyze serum levels of transaminases and gamma- γ -glutamyl transpeptidase concomitantly, in order to eliminate liver abnormalities. Furthermore, up to 10% of patients with PDB can present normal ALP levels, and such finding should not excluding the diagnosis. Additional particular bone turnover markers, for example, those ordinarily accessible serum C-terminal telopeptide (CTX) Also urinary N-terminal telopeptide (NTX), show bone resorption, Furthermore aminoterminal propeptide for kind 1 collagen (P1NP), show to bone formation, could make advantageous in this setting. Determination of the nonisomerized portion for CTX (alpha- alternately α -CTX), which additional faultlessly reflects the secondary turnover from claiming pagetic woven bone is sadly not generally accessible.

Cytogenetic And Molecular Genetic Findings/Chromosome Analysis

RANK Mutation by E.M& PCR: OPG Mutation caused by homozygous losing of TNFRSF11B. Detection of Canine Distemper Virus in 100% of Paget's Disease Samples via In Situ-Reverse Transcriptase-Polymerase Chain Reaction.

Histopathology: The hallmark of PDB under microscopic are excessive and abnormal remodeling of bone, with both active and quiescent phases (figure-4). Three phases have classically been described as discrete and distinctive, Despite , in reality, they represent a continuum the first one, the lytic phase (incipient-active), in which osteoclasts numerous. second one the mixed phase (active), in which osteoblasts detected more prominent and over active than the osteoclast so it reflecting the amount of bone formation in this stage(figure -6); Also third, that blastic stage, the blastic phase (late-inactive), in which osteoblastic activity gradually declined. Due to there is often extensive osseous damage and due individual areas progress at variable rates, Paget disease of differing phases may be displayed in the same patient. The outcomes is a thickened, disorganized trabecular pattern of bone, referred to as a "mosaic" or "jigsaw" pattern (figure-5) .Cement lines along the coarsened and enlarged trabeculae are characteristically seen; these lines reflected osseous resorption and bone formation . The trabecular areas of thickening usually lost the interconnection display in normal bone and thus are weakened and often known to as "pumice" bone .The cortex is also thickened and is the area of most active bone turnover and repair. These areas of progressive bone resorption and formation also show over vascularization with small caliber vessels. Bone marrow changes are seen throughout the disease process. Fibrovascular tissue changes the normal yellow marrow in more active disease, especially in the lytic phase and less extensively in the early mixed phase . A return to diffuse yellow marrow gradually shows in the late mixed phase . This process often ultimately results in an actual progressive in marrow fat deposition (compared with normal yellow mar- row component), which we refer to as atrophic marrow. during the final inactive stage.

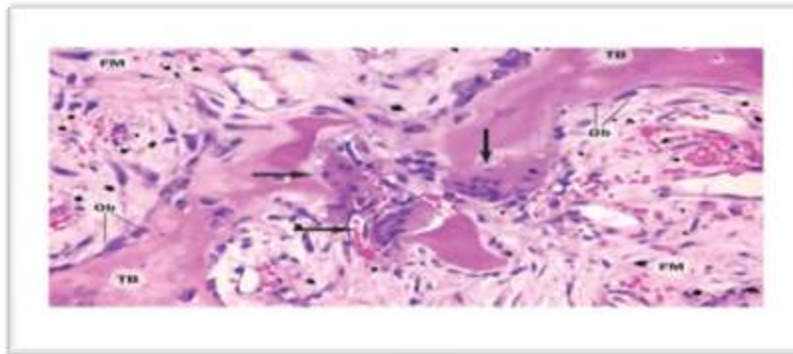


Figure-4 Haematoxylin and eosin stained section (magnification $\times 20$) demonstrating multiple large osteoclasts (arrows). Other features (Obs lining TB and an FM) are also visible. Abbreviations: FM, fibrovascular marrow; Ob, osteoblast; TB, trabecule

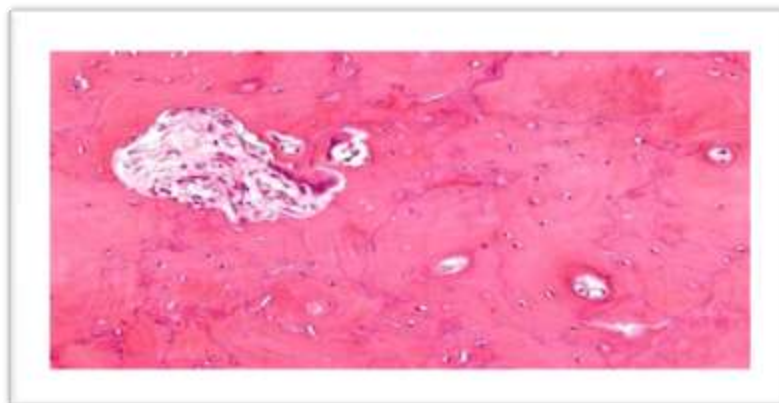


Figure 5 Micrograph showing Paget's disease of the bone with the characteristic jigsaw puzzle-like/mosaic pattern, H&E stain

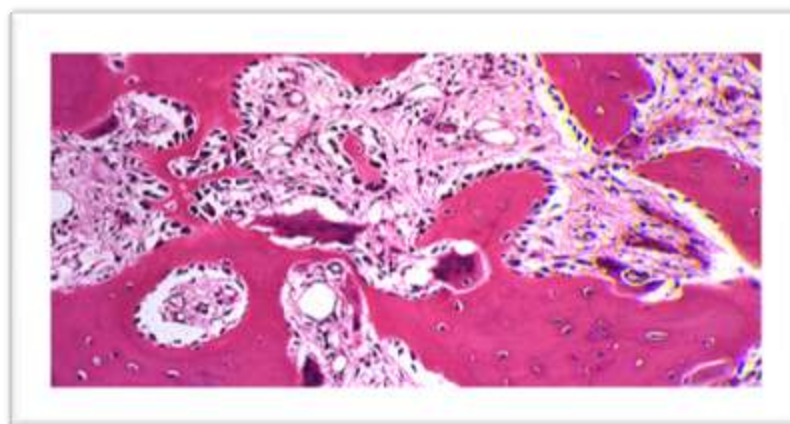


Figure 6- Mixed" phase of Paget's disease of bone.

II . Conclusion

Paget disease of bone represents a most common disorder involvement 3%–4% of the population over the age of 40 years. Paget disease reported a wide spectrum of radiologic patterns and appearances related to the phase of disease seen pathologically. Radiography is sufficient for diagnosis in the most of the cases and typically display pathognomonic changes in the lytic phase of Paget disease, with sharply defined areas of osteolysis in the skull or beginning in subchondral bone of the appendicular skeleton; in the mixed phase, with signs trabecular and cortical thickening and bone enlargement; and in the blastic

phase, with areas of sclerosis. These manifestations related to the overall degree of remodeling of bone, which indicates to the underlying extent of osteoclastic against osteoblastic activity seen histologically. In this article, report summarize and confirm the diagnosis as collecting parameters of clinical radiographic biochemicals marker ,cytogenetic and histopathology. As parameters and keys helpful to confirm and detected the disease in additional to the classical way, clinical & radiographic) the advanced techniques such as cytogenetic using to detect the molecular damages contributing and essential cause of diseases this knowledge act as the best way to use the therapy against the defect.

Reference

- [1]. Sabharwal R, Gupta S, Sepolia S, et al. An Insight in to Paget's Disease of Bone. *Niger J Surg Off Publ Niger Surg Res Soc.* 2014;20(1):9-15. doi:10.4103/1117-6806.127098.
- [2]. Hadjipavlou AG, Gaitanis IN, Kontakis GM. Paget's Disease of the Bone and its Management. *J Bone Jt Surg - Br Vol.* 2002;84-B:160-169.
- [3]. Ferraz-de-Souza B, Correa PHS. Diagnosis and treatment of Paget's disease of bone: a mini-review. *Arq Bras Endocrinol Metabol.* 2013;57(8):577-582. doi:10.1590/S0004-27302013000800001.
- [4]. Griz L, Fontan D, Mesquita P, et al. Diagnosis and management of Paget's disease of bone. *Arq Bras Endocrinol Metabol.* 2014;58(6):587-599. doi:10.1590/0004-2730000002941.
- [5]. Kumar V, Abbas AK, Aster JC. Bones, Joints, and Soft Tissue Tumors. *Robbins Basic Pathol.* 2012;10:765-795. [https://webfiles.uci.edu/redwards/public/RBP9 Chapter 20.pdf](https://webfiles.uci.edu/redwards/public/RBP9%20Chapter%20.pdf).
- [6]. Kurihara N, Hiruma Y, Yamana K, et al. Contributions of the measles virus nucleocapsid gene and the SQSTM1/p62P392L mutation to paget's disease. *Cell Metab.* 2011;13(1):23-34. doi:10.1016/j.cmet.2010.12.002.
- [7]. Roodman G, Windle J. Science in medicine-Paget disease of bone. *J Clin Invest.* 2005;115(2):200-207. doi:10.1172/JCI200524281.200.
- [8]. Chung PYJ, Van Hul W. The role of genes in the pathogenesis of Paget's disease of bone. *IBMS Bonekey.* 2010;7(3):124-129. doi:10.1138/20100436.
- [9]. Kuorilehto T, Nissinen M, Koivunen J, Benson MD, Peltonen J. NF1 tumor suppressor protein and mRNA in skeletal tissues of developing and adult normal mouse and NF1-deficient embryos. *J Bone Miner Res.* 2004;19(6):983-989. doi:10.1359/jbmr.040130.
- [10]. Szulc P, Delmas PD. Biochemical markers of bone turnover in men. *Calcif Tissue Int.* 2001;69(4):229-234.