

## Symptomatic Recurrence of a Residual Rathke's Cleft Cyst Presenting As CSF Rhinorrhoea-A Rare Case Report

<sup>1</sup>Sudhir Suggala, <sup>2</sup>K.V.V.S.N Murthy

<sup>1</sup>Consultant Neurosurgeon, Nagarjuna Hospital, Vijayawada, Andhra Pradesh, India

<sup>2</sup>In charge Professor, Department of Neurosurgery, Government General Hospital, Vijayawada, Andhra Pradesh, India

**Abstract:** We present the first report of Rathke's cleft cyst presenting as CSF rhinorrhea following an asymptomatic period of fourteen years after the first surgery. Our patient, a fifty five year female presented to us with CSF rhinorrhea and two episodes of generalized tonic clonic seizures. She had been operated earlier in 1997 through right pterional craniotomy for decompression of cystic sellar suprasellar mass and was histopathologically confirmed as Rathke's cleft cyst. Recurrence of symptomatic Rathke cleft cyst is considered rare [5%-18%]<sup>1</sup> in various series. Our case is unique in the sense that the patient had been asymptomatic for fourteen years following which she developed symptoms.

### I. Introduction

Rathke's cleft cysts are classically described as benign epithelium-lined intrasellar cysts containing mucoid material. They are thought to originate from remnants of Rathke's pouch<sup>2</sup>. These cysts are frequently small and asymptomatic, and are found in the pars distalis or pars intermedia in 2% to 26% of routine autopsy series<sup>3,4</sup>. Occasionally, they may become large enough to cause symptoms by compression of the visual apparatus, pituitary gland, or hypothalamus by the cyst. Symptomatic Rathke cleft cyst typically present during the 4<sup>th</sup> or 5<sup>th</sup> decade of life with a slightly higher female preponderance<sup>1,6</sup>. Visual loss has been reported to develop in 35%–50% of patients undergoing surgical intervention and may include deficits in visual fields as well as in visual acuity.<sup>1,7</sup> Hyperprolactinemia and growth hormone deficiency are relatively common endocrinological findings associated with RCCs, followed by hypocortisolemia and hypogonadism<sup>1,7</sup>. Diabetes insipidus has been reported as a presenting feature in approximately 7%–20% of patients with RCCs<sup>7,8</sup>. In rare cases, Rathke cleft cyst may present with chemical meningitis, sellar abscess, lymphocytic hypophysitis, or intracystic hemorrhage<sup>8,9</sup>. Histologically, Rathke cleft cysts consist of a single or pseudostratified epithelium with an underlying layer of connective tissue. The epithelium may contain ciliated, goblet, squamous, and/or basal cells<sup>5</sup>. These cysts are classified as a distinct category among other cystic epithelial lesions including dermoid cysts, epidermoid cysts, and craniopharyngiomas. Although small asymptomatic Rathke's cleft cysts have been recorded at autopsy in 13–22% of normal pituitary glands, symptomatic cysts are rare, and only approximately 150 cases have been reported in the literature. The usual management of symptomatic Rathke's cleft cysts has been simple surgical drainage with partial excision of the cyst wall<sup>1,3,8</sup>. Because recurrence of these cysts is reputedly rare, with only a few isolated case reports in the literature, postsurgical radiotherapy usually has not been recommended. We report a case of residual Rathke cleft cyst presenting as CSF rhinorrhea after remaining clinically silent for 14 years after surgery

### II. Case Report

This fifty five year old woman presented in November 2011 with history of two episodes of generalized tonic clonic seizures and intermittent episodes of clear watery discharge from right nostril in the past six months. In February 1997 she had undergone evaluation for progressive visual deterioration and headache. Evaluation revealed a sellar suprasellar lesion for which a right pterional craniotomy and decompression of cystic sellar suprasellar mass was performed. Biopsy report was consistent with Rathke cleft cyst.

On admission her physical and neurological examination was essentially normal. EEG study was not contributory. Hormone evaluation revealed subclinical hypothyroidism [TSH 19.31 µIU/ml (0.35-5.50)] for which she was started on Tab Eltroxin 50ug daily. Rest of the hormone evaluation [GH < 0.05 ng/ml; cortisol, serum evening sample: 3.75 ug/dl; cortisol serum morning sample: 6.66 ug/dl; T3: 0.83 ng/ml, T4: 7.80 ug/dl, FSH: 9.99 mIU/ml, LH: 6.11 mIU/ml, prolactin: 5.83 ng/ml] was normal according to her post menopausal status. A beta-2-transferrin test of the clear nasal watery fluid was performed and proved confirmatory. Visual acuity in the right eye was 6/24 and left eye was 6/12. Fundus exam was normal. Visual field examination [Fig 1] revealed a small defect in right superior temporal region which was probably due to chiasmal compression.

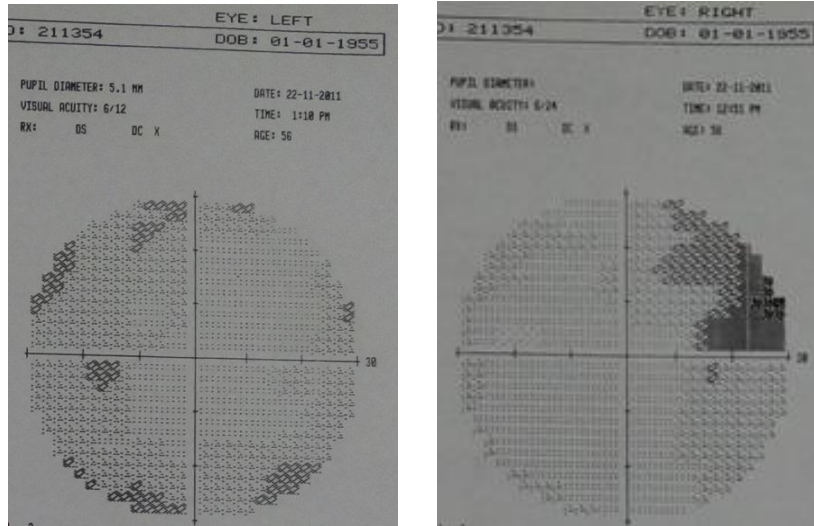


Fig 1: Perimetry of visual fields.

Radiology of the skull revealed a defect in the cribriformplate on the right side. MRI findings were suggestive of a cystic sellar suprasellar lesion with compression of optic chiasma. The lesion was hypointense on T1W image and hyperintense on T2W image with peripheral enhancing wall and internal septa on contrast studies[Fig 3]. CT and MR cisternogram revealed evidence of focal breach in cribriform plate of ethmoid with active leak of CSF into the ethmoid sinus on the right side[Fig1]. Comparison with previous radiology was suggestive of recurrent/residual Rathke cleft cyst[Fig3].

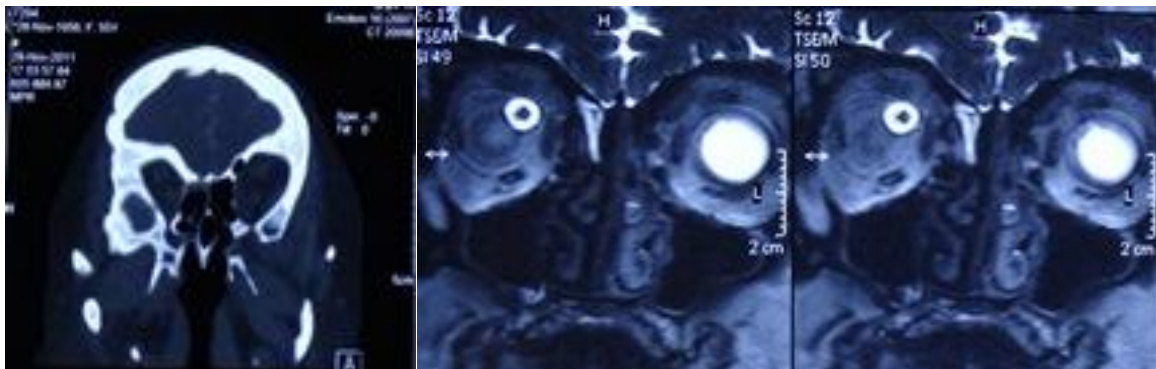


Fig 2: CT and MR cisternography

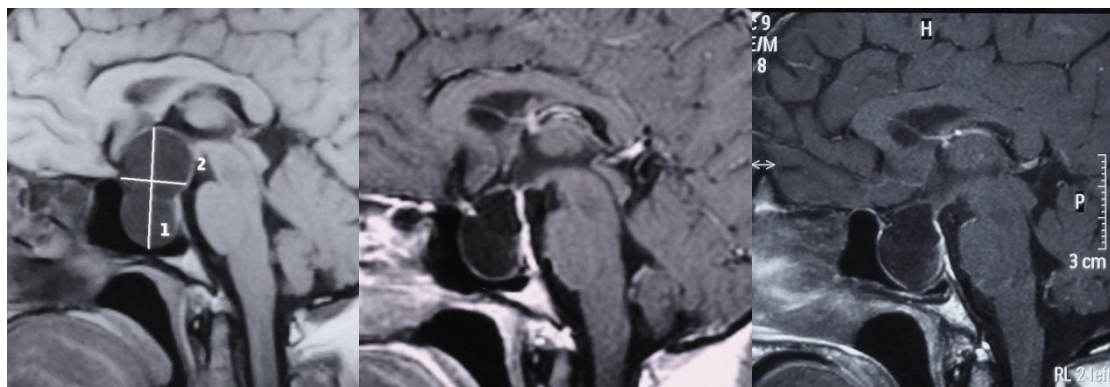


Fig 3: Follow up MRI 1997 [pre op], 1998 [follow up], present [2011] respectively

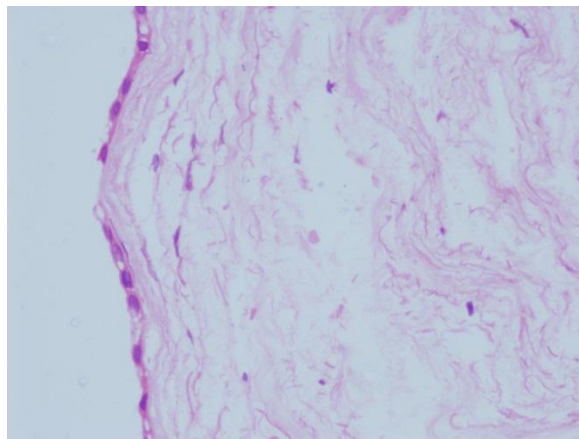


Fig 4: Photomicrograph showing the cyst wall lined by flattened to cuboidal cells .

We performed transnasal endoscope assisted microscopic repair of cribriform plate and decompression of Rathke cleft cyst. There was a defect in the cribriform plate which was repaired with biological glue and paraumbilical fat. The cyst contained pale yellow fluid [protein 100mg/dl, glucose 65mg/dl, chloride 128mmol/l, no cells seen] and there was no defect in the diaphragm sella.

Histopathological examination showed fragmented collagenised cyst wall partly lined by flattened to cuboidal epithelium which was strongly positive for EMA [epithelial membrane antigen] and negative for GFAP [glial fibrillary acidic protein]. Findings were suggestive of benign epithelial cyst consistent with Rathke's cleft cyst [Fig 4]. There was no CSF leak detected in the postoperative period.

### III. Discussion

Rathke's cleft cysts are believed to be derived from the remnants of Rathke's pouch. Some authors believe that these cysts are derived directly from the neurothelium. Some consider them to arise as a result of metaplasia of anterior pituitary cells, whereas still others propose an endodermal origin<sup>2,10,11,12,13</sup>. Symptomatic Rathke cleft cysts are rare, usually presenting as intrasellar lesions with approximately one third having a significant suprasellar extension<sup>14,15</sup>. The common presentations include headache, pituitary dysfunction, and in the event of suprasellar extension, visual loss caused by compression of the optic chiasm<sup>1,7,8</sup>. Various atypical clinical appearances of Rathke's cleft cysts also have been described in the literature: an entirely suprasellar location<sup>16</sup>, hemorrhage into a Rathke's cleft cyst<sup>17</sup>; abscess within the Rathke's cleft cyst<sup>19,20</sup>; cysts associated with pituitary adenomas<sup>21</sup> and Rathke's cleft cyst associated with a pineal cyst<sup>22</sup>. There have been numerous attempts to define the features of a Rathke's cleft cyst on pituitary imaging. The cyst density on CT scanning and cyst intensity on MRI imaging have been variably reported to range from hypo to iso to mixed intensity<sup>23,24</sup>. Calcification, said to be characteristically absent from Rathke's cleft cysts [as evidenced in this case], but has been reported in few case reports<sup>25</sup>. Lack of postcontrast enhancement on MRI has been suggested by some to be the hallmark of these cysts, but patchy or ring enhancement post-gadolinium injection [as seen in this case] also has been reported<sup>23</sup>. At surgery, these lesions have been variably noted to have a cystic to semisolid consistency, and the cyst contents have been described from clear CSF-like to milky-white, brown, machine oil-like, and engine oil-like<sup>23</sup>. Cholesterol crystals within the cyst fluid have been documented, as are cysts with solid components.

Recurrence of Rathke's cleft cysts is said to be very rare<sup>1,26</sup>. It has been suggested that the presence of a solid lesion within the cyst, consisting of stratified squamous epithelium, increases the risk of a recurrence<sup>30</sup>. However, recurrence of cysts lined by a single layer of cuboidal or columnar epithelium also has been reported. In our case the biopsy report did not reveal any foci of stratified squamous epithelium. We could not identify any definite cyst fluid or histopathological characteristic that might predict an increased risk of recurrence.

Aggressive resection of Rathke cleft cysts can result in postoperative endocrine dysfunction. Diabetes insipidus has been reported to be the most common postoperative complication in surgically treated patients<sup>7,8</sup>. In a recent study, 53 patients who underwent surgery for Rathke cleft cysts at three different institutions where various surgical techniques were used reported an 11% recurrence rate during a mean follow-up period of 31 months (2 months minimum)<sup>8</sup>. Voelker<sup>27</sup> and colleagues surgically treated eight patients and reviewed 147 case reports with varying surgical techniques in the literature to arrive at a 5% recurrence rate following transsphenoidal surgery and a 10% rate following craniotomy. Some studies have focused on symptom improvement without indicating the duration of the follow-up period. C. Aho<sup>1</sup> et al series revealed an 18% recurrence rate in patients in whom the duration of follow up was at least 5 years. The question that arises from these observations is whether aggressive surgical intervention, including resection of the symptomatic cyst

contents and wall, is necessary. Full evacuation of the contents and liberal opening of the cyst wall was recommended by Fager and Carter<sup>28</sup> in 1966. Ross<sup>29</sup> et al. advocated the use of cauterization of the cyst wall and application of absolute alcohol if no violation of the subarachnoid space was seen, in an attempt to kill the cellular wall of the cyst and thus potentially decrease recurrence. This was done in their series of 40 patients undergoing transsphenoidal surgery for Rathke cleft cyst without any complication. In C Aho et al<sup>1</sup> series of 118 patients treated surgically, 75 patients received absolute alcohol when the arachnoid membrane was intact. complication such as blindness, anosmia, and partial third cranial nerve damage have been reported following this technique because the subarachnoid membrane may be violated and the alcohol mixed with the patient's CSF, causing the complications. They did not find that radical resection was associated with a decreased recurrence rate. Combined with improved endocrinological complication rates for less radical resection, it appears that attempting total resection of the wall may not be the optimal treatment for a symptomatic Rathke cleft cyst. Instead, squamous metaplasia and the use of a fat and/or fascial graft during surgery were more highly associated with recurrences in patients.

However, because complete surgical removal was not attempted in our case during the first surgery it may be more appropriate to consider the recurrence due to cyst fluid reaccumulation. The CT and MR Cisternography in our case preoperatively revealed a breach in the cribriform plate of ethmoid bone. Comparison of the interval MRI done in 1998 with the preoperative MRI in 2011 revealed the cyst size to be increasing. It might be possible that there would have been an intermittent increase in the intracranial pressure due to the expanding Rathke's cleft cyst and the patient developed CSF rhinorrhea. The defect in the cribriform plate would have been latent after the first surgery via the transcranial route performed in 1997.

#### IV. Conclusion

In summary, we present the clinical, radiological, surgical, and histopathological features of symptomatic recurrence of Rathke's cleft cyst presenting as CSF Rhinorrhoea 14 years after the first surgery. This is the longest period of symptomatic recurrence so far described in the literature. We believe that long-term follow-up with periodic MRI and neuroophthalmological assessment is hence necessary in all such cases. The optimal therapy for a recurrent symptomatic cyst is unclear, but transsphenoidal aspiration and, where possible, extensive removal of the cyst wall are most appropriate; although the role of radiotherapy in preventing further recurrence at present is unclear. This case also raises the question as to whether complete radical resection is necessary to remove a Rathke cleft cyst to reduce symptomatic recurrence.

#### References

- [1]. Aho CJ, Liu C, Zelman V, Couldwell WT, Weiss MH: Surgical outcomes in 118 patients with Rathke cleft cysts. *J Neurosurg* 2005;102:189–193
- [2]. Russel DS, Rubinstein LJ. Pathology of tumors of the nervous system. 5th ed. Baltimore: Williams & Wilkins; 1989:30–32, 690–710
- [3]. El-Mahdy W, Powall M. Transsphenoidal management of 28 symptomatic Rathke's cleft cysts, with special references to visual and hormonal recovery. *Neurosurgery* 1998;42:7–6
- [4]. Burger PC, Scheithauer BW, Vogel FS: Surgical Pathology of the Nervous System and Its Coverings, ed 4. Baltimore: Churchill Livingstone, 2002
- [5]. Matsushima T, Fukui M, Ohta M, Yamakawa Y, Takaki T, Okano H: Ciliated and goblet cells in craniopharyngioma. Light and electron microscopic studies at surgery and autopsy. *Acta Neuro-pathol* 50:199–205, 1980
- [6]. Benveniste RJ, King WA, Walsh J, Lee JS, Naidich TP, Post KD: Surgery for Rathke cleft cysts: technical considerations and outcomes. *J Neurosurg* 101:577–584, 2004
- [7]. Eguchi K, Uozumi T, Arita K, Kurisu K, Yano T, Sumida M, et al: Pituitary function in patients with Rathke's cleft cyst: significance of surgical management. *Endocr J* 41:535–540, 1994
- [8]. Kim JE, Kim JH, Kim OL, Paek SH, Kim DG, Chi JG, et al: Surgical treatment of symptomatic Rathke cleft cysts: clinical features and results with special attention to recurrence. *J Neurosurg* 100:33–40, 2004
- [9]. Shimoji T, Shinohara A, Shimizu A, Sato K, Ishii S: Rathke cleft cysts. *Surg Neurol* 21:295–310, 1984
- [10]. Shanklin WM. 1949 On the presence of cysts in the human pituitary. *Anat Rec*. 104:379 – 407.
- [11]. Shanklin WM. 1951 Incidence and distribution of cilia in the human pituitary with a description of micro-follicular cysts derived from Rathke's cleft. *Acta Anat (Basel)*. 11:361–382
- [12]. Berry RG, Schlezinger NS. 1959 Rathke's cleft cysts. *Arch Neurol*. 1:48 –58.
- [13]. Shuangshoti S, Netsky MG, Nashold Jr BS. 1970 Epithelial cysts related to the sellar turcica: proposed origin from neuroepithelium. *Arch Pathol Lab Med*. 90:444 – 450
- [14]. Byrd SE, Winter J, Takahasi M, Joyce P. 1980 Symptomatic Rathke's cleft cyst demonstrated on computed tomography. *J Comput Assist Tomogr*. 4:411– 414.
- [15]. Rout D, Das L, Rao VRK, Radhakrishnan VV. 1983 Symptomatic Rathke's cleft cysts. *Surg Neurol*. 19:42– 45
- [16]. Itoh J, Usui K. 1992 An entirely suprasellar symptomatic Rathke's cleft cyst: case report. *Neurosurgery*. 30:581–585.
- [17]. Onesti ST, Wisniewski T, Post KD. 1990 Pituitary hemorrhage into a Rathke's cleft cyst. *Neurosurgery*. 27:644 – 646.
- [18]. Fairburn B, Larkin IM. 1964 A cyst of Rathke's cleft. *J Neurosurg*. 21:223–225.
- [19]. Obenchain TG, Becker DP. 1972 Abscess formation in Rathke's cleft cyst – case report. *J Neurosurg*. 36:359 –362.
- [20]. Bogner L, Sziefert GT, Fedocsak I, Pasztor E. 1992 Abscess formation in Rathke's cleft cyst. *Acta Neurochir (Wien)*. 117:70 –72.
- [21]. Nishio S, Mizuno J, Barrow DL, Takei Y, Tindall GT. 1987 Pituitary tumors composed of adenohypophysial adenoma and Rathke's cleft cyst elements: a clinicopathological study. *Neurosurgery*. 21:371–377.
- [22]. Solarski A, Panke ES, Panke TW. 1978 Craniopharyngioma in the pineal gland. *Arch Pathol Lab Med*. 102:490 – 491

- [23]. Sumida M, Uozumi T, Mukada K, Arita K, Kurisu K, Eguchi K. 1994 Rathke's cleft cysts: correlation of enhanced MR and surgical findings. *AJNR Am J Neuroradiol.* 15:525–532
- [24]. Kucharczyk W, Peck WW, Kelly WM, Norman D, Newton TH. 1987 Rathke's cleft cysts: CT, MR imaging, and pathologic features. *Radiology.* 165:491–495
- [25]. Adelman L, Post K. 1977 Calcification in Rathke's cleft cyst. *J Neurosurg.* 47:641.
- [26]. Mukherjee JJ, Islam N, Kaltsas G, Lowe DG, Charlesworth M, Afshar F, et al: Clinical, radiological and pathological features of patients with Rathke's cleft cyst: tumors that may recur. *J Clin Endocrinol Metab* 82:2357–2362, 1997
- [27]. Voelker JL, Campbell RL, Muller J: Clinical, radiographic, and pathological features of symptomatic Rathke's cleft cysts. *J Neurosurg* 74:535–544, 1991
- [28]. Fager CA, Carter H: Intrasellar epithelial cysts. *J Neurosurg* 24:77–81, 1966
- [29]. Ross DA, Norman D, Wilson CB: Radiologic characteristics and results of surgical management of Rathke's cleft cysts in 43 patients. *Neurosurgery* 30:173–179, 1992
- [30]. Yoshida J, Kobayashi T, Kageyama N, Kanzaki M. 1977 Symptomatic Rathke's cleft cyst: morphological study with light and electron microscopy and tissue culture. *J Neurosurg.* 47:451–458.