

Mandelic acid chemical peel in Acne vulgaris: A boon or a bane?

Dr. Shishira.R.Jartarkar, Dr. Mallikarjun.M, Dr. Bugude.Gangadhar, Dr. Manjunatha.P

Abstract

Background: Acne vulgaris is one of the most prevalent skin disease affecting face and the single most common reason for visits to dermatologists.¹ Various modalities of treatment like topical, systemic anti-bacterials, retinoids, sebostatics, have been used in the treatment of acne and nowadays, clinicians seek to employ new technologies in acne care like chemical peeling. Many clinicians have used various chemical peels for treatment of post acne scarring and hyperpigmentation mainly in lighter skin types. Mandelic acid peel is a newer modality for acne vulgaris and hence, it is worthwhile to study the efficacy of mandelic acid peels.

Aims: To study the therapeutic efficacy of 30% Mandelic acid peel in acne vulgaris.

Methods: Fifteen patients with acne vulgaris between the age group of 15 and 30 years with only facial lesions not responding to three months of conventional treatment were included in the study. A test peel was done in the retroauricular area. The peel was applied for two minutes on first session and progressively increased by one minute every fortnightly upto a maximum of five minutes. Total number of sessions was six. The side effects were also noted.

Results: In our study, improvement was noted in all the patients in the study with mean improvement of 53.33%. Erythema and burning were the most common side effects noted

Conclusion: In our study, lower concentration mandelic acid proved to be safe and effective in Indian population with darker skin types, with fewer side effects which were short lived and preventable.

Keywords: mandelic acid, acne, darker skin

Face is a map of our personality as well as our whole life. Study of personality interferences from facial appearance has long history in psychology. Studies have found that facial structure, hair colour and weight all can affect our paychecks.

I. Introduction

Mandelic acid, an alpha hydroxyl acid (AHA) named after German "mandel" meaning almond and derived from hydrolysis of an extract of bitter almonds, has been studied for its possible use in common skin conditions like photoaging, irregular pigmentation and acne. Mandelic acid (alpha-hydroxybenzeneacetic acid) is an 8-carbon alpha-hydroxy acid with the chemical formula $\text{HOCH}(\text{C}_6\text{H}_5)\text{COOH}$. The mandelic acid molecule is larger than the glycolic acid molecule, a widely used AHA. In addition, mandelic acid, which has a pK of 3.41, is stronger than glycolic acid, which has a pK of 3.83 at 25°C. The acidity of AHAs may vary considerably with changes in temperature. Mandelic acid has a high melting point, is partially soluble in water, and is freely soluble in isopropyl and ethyl alcohol.¹ Acne vulgaris is one of the most prevalent skin disease affecting face and the single most common reason for visits to dermatologists.² Acne vulgaris is an inflammatory disease of pilosebaceous unit, characterised by seborrhoea, comedones, papules, pustules, nodules and cysts, with occasional scarring. The disease burden of acne ranges from facial scarring and hyperpigmentation to social, psychological and emotional distress³ as well as self-perception of poor health.^{3,4}

Various modalities of treatment like topical, systemic anti-bacterials, retinoids, sebostatics, have been used in the treatment of acne and nowadays, clinicians seek to employ new technologies in acne care like chemical peeling.^{5,6}

Chemical peeling is the application of chemical agent to skin that causes controlled destruction of part/whole epidermis with/without dermis leading to exfoliation and removal of superficial lesions followed by rejuvenation of new epidermal and dermal tissues.⁷

Chemical peeling is a popular, relatively inexpensive and greatly safe method for treatment of skin disorders like acne.

Chemical peels are classified by the depth of action into superficial, medium and deep peels

Chemical peels are used as an adjunct to medical therapy in acne because they produce complementary rapid therapeutic effects and improvements in skin appearance and textures.

Various chemical peels are used in acne like glycolic acid, salicylic acid, trichloroacetic acid, mandelic acid, etc. Of these mandelic acid is a newer peel for acne, so it is worthwhile to study efficacy of mandelic acid.

Aim: To study the therapeutic efficacy of 30% Mandelic acid peel in acne vulgaris.

II. Materials and method

Fifteen patients with acne vulgaris between the age group of 15 and 30 years with only facial lesions not responding to three months of conventional treatment were included in the study. The patients with a history of hypertrophic scarring, keloids, active or recurrent herpes simplex, oral isotretinoin therapy within previous six months, patients on acne inducing drugs, patients with systemic illness. (e.g.) hypertension, diabetes, thyroid disorder were excluded from the study. Our institution's ethical committee approved the study protocol. The procedure was explained to the patient in detail, and written informed consent was obtained from all patients included in the study. Consent was taken from the parent or guardian if the patient was younger than 18. All oral and topical medications being taken for acne were discontinued 2 weeks before peeling. At the first visit, a test peel with 30% Mandelic acid was performed on a 1×1 cm area in the right retro-auricular area. The patients were reviewed after 1 week, and if they tolerated the peel well, they were taken up for full face peels. Patients were asked to first wash their face thoroughly with water. The patients wore a surgical cap to pull back their hair and cover the ears. Degreasing was done by scrubbing with cotton gauze soaked with acetone. Sensitive areas of the face were protected by a layer of petrolatum. The peel was applied over the entire face using about 1 ml of the peel. The peeled areas were observed for development of erythema, which was regarded as end point. The patients were also asked to report stinging and burning sensation, which was considered alternative end point, when erythema was not visible because of dark skin color. After the end point, patients were asked to wash their face with ice water and apply sunscreen before leaving the hospital. The peel was applied for two minutes on first session and the contact time was progressively increased by one minute every fortnightly upto a maximum of five minutes. Total number of sessions were six. The side effects were also noted. Acne was classified based on Global Acne Grading System into mild, moderate, severe and very severe acne vulgaris.⁸ The degree of improvement was assessed.

0-25% - mild improvement
26-50% - moderate improvement
51-75% - good improvement
>75% - significant improvement

Statistical analysis: The data was analysed using Wilcoxon signed rank test and $p < 0.05$ was considered as significant and $p < 0.01$ was considered highly significant.

Observations: In our study, 9 (60%) were males and 6 (40%) were females. Of these, majority (66.7%) were students. In most of the patients (53.33%), the duration of acne was between 1-4 years, less than 1 year duration was noted in 26.7% and duration more than 4 years was noted in 20% of the individuals. The most common skin type noted was Fitzpatrick's skin type IV (46.7%), followed by skin type III (33.3%) and V (20%)

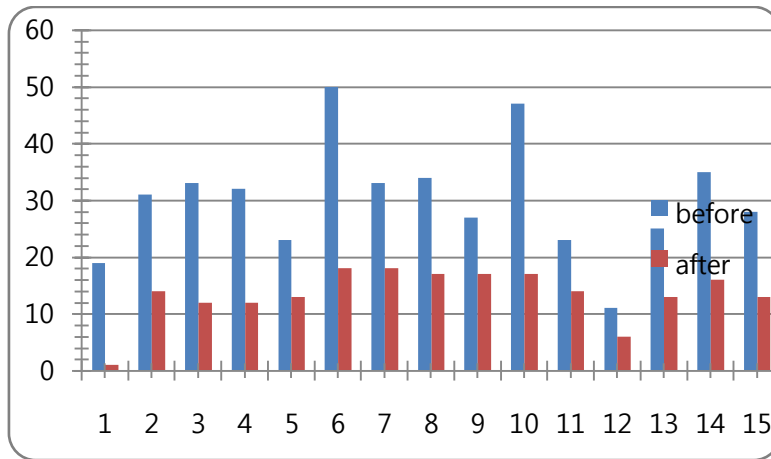
III. Results

In our study, mean age was 21.13 yrs +/- 2.9 (SD) with minimum age of 15 years and maximum age of 25 years.

Total improvement in each patient was calculated and maximum improvement noted was 94.7% and minimum improvement was 37% and mean improvement of all the patients was 54.7%. Improvement based on grade was noted and moderate improvement was noted in 46.7%, good improvement was noted in 46.7% and significant improvement was noted in 6.7%.

Improvement in comedones in each individual was noted. Mild improvement noted in 46.7%, moderate improvement in 40% and significant improvement in 13.3%.

Using WILCOXON Test, improvement of comedones and total score before and after the treatment, was highly significant ($p < 0.01$). Using chi square test, there was a correlation between skin type and comedone score .i.e. there was more significant improvement in comedones in type III skin type than compared to skin type IV and Type V. No statistical significant correlation was noted between total improvement and age/gender/occupation/duration of acne. Most common side effect was burning & erythema noted in 60% (9) of which 55.6% was in skin type IV and remaining in skin type III, which subsided completely over few hours without any sequel. The second most common side effect noted was dryness of the skin in 40% (6) patients.



Improvement in severity of acne , before and after 6 sittings of mandelic acid peel

IV. Discussion

To the best of our knowledge, there has been paucity of data regarding use of mandelic acid peel alone in acne vulgaris. This might be because of the large structure of mandelic acid, which causes slow penetration, thus making it difficult to evaluate it as a peeling agent. According to Taylor¹, chemical peeling with mandelic acid, when compared with glycolic acid peel, produced less erythema and was less likely to result in crusting and blistering side effects. Acne improved remarkably in many patients treated with inflammatory pustular, papular and comedonal acne. Many acne patients who were resistant to antibiotics given both systemically and topically have responded very well to mandelic acid.

In our study, good to significant clearing of acne was seen in 53.4% of patients. Non-inflammatory and inflammatory lesions were seen to clear faster than would ordinarily have occurred with traditional therapy, suggesting anti-inflammatory and anti-bacterial property of mandelic acid. All patients with oily skin and enlarged pores had significant improvement. In our study, the mean total score reduced from 30 to 13 over 12 weeks ($p < 0.01$). Non-inflammatory lesions (comedones) and inflammatory lesions like papules, pustules and nodules had decreased significantly at the end of treatment. Mandelic acid peels were well tolerated, and no patient developed postinflammatory hyperpigmentation/flare up of acne/photosensitivity/scarring or allergic sensitization. Chemical peeling with low concentration mandelic acid, when compared with other peels, produced less erythema, and was less likely to result in crusting or blistering or other adverse effects on the epidermis. The onset of erythema is more predictable and gradual, and there is less likelihood that “hot spots” will develop in dry areas of the face.

V. Conclusion

Mandelic acid is one of the largest alpha hydroxyl acid and penetrated the epidermis slowly and uniformly, making it an ideal peeling agent for the sensitive skins of patients with severe acne and hyperpigmentation. Mandelic acid peel is a promising, safe, simple, cost effective therapy in treatment of active acne resistant to routine modalities of treatment.

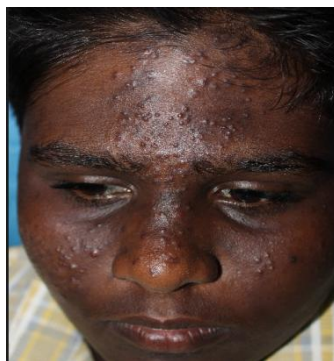

fig.1

Figure 1: A 16yr old with severe acne before treatment



fig.2

Figure 2: After 6 sittings, showing good improvement

References

- [1]. Taylor MB. Summary of Mandelic Acid for the Improvement of Skin Conditions. *Cosmetic Dermatol.* June1999:26-28.
- [2]. Garg VK, Sinha S, Sarkar R. Glycolic acid peels versus Salicylic-Mandelic acid peels in active acne vulgaris and post-acne scarring and hyperpigmentation. *Dermatol Surg.* 2009; 35:59-65.
- [3]. Thomas DR. Psychosocial effects of acne. *J Cutan Med Surg.* 2004; 8suppl4:3-5.
- [4]. Al Robaee AA. Assessment of general health and quality of life in patients with acne using a validated generic questionnaire. *ActaDermatovenerol Alp PanonicaAdrait.* 2009; 18(4):157-64.
- [5]. Kim RH, Armstrong AW. Current state of acne treatment: Highlighting lasers, photodynamic therapy, and chemical peels. *Dermatol Online J.* 2011; 17(3):2
- [6]. Ross EV. Optical treatments for acne. *DermatolTher.* 2005; 18(3):253-66.
- [7]. Khunger N. Standard guidelines of care for chemical peels. *Indian J DermatolVenerolLeprol.* 2008; 74:S5-S12.
- [8]. Adityan B, Kumari R, Thappa DM. Scoring systems in acne vulgaris. 2009; 75(3):323-326.